

The polarity and shape of the T wave in lead V-10 in Chihuahuas

Polaridade e formato da onda T na derivação V-10 em Chihuahuas

La polaridad y forma de la onda T en la derivación V-10 en Chihuahuas

Received: 09/18/2023 | Revised: 09/27/2023 | Accepted: 09/28/2023 | Published: 10/02/2023

Gustavo Luiz Gouvêa de Almeida

ORCID: <https://orcid.org/0000-0001-7612-7655>
Centro Veterinário Colina, Brazil
E-mail: vetcolina@pig.com.br

Marcelo Barbosa de Almeida

ORCID: <https://orcid.org/0000-0001-8219-8484>
Centro Veterinário Colina, Brazil
E-mail: vetcolina@hotmail.com

Ana Carolina Mendes dos Santos

ORCID: <https://orcid.org/0000-0002-7760-713X>
Centro Veterinário Colina, Brazil
E-mail: acmvetcolina@gmail.com

Ângela Vargas

ORCID: <https://orcid.org/0000-0003-3354-9094>
Centro Veterinário Colina, Brazil
E-mail: angela.vgm@hotmail.com

Sophie Ballot

ORCID: <https://orcid.org/0000-0001-5692-9140>
Centro Veterinário Colina, Brazil
E-mail: sb_sophieballot@hotmail.com

Abstract

The T-wave in the canine electrocardiogram can be positive, negative, or biphasic in most leads, while its amplitude should not be greater than 25% of the R wave. However, since the 1960's persists controversy regarding the polarity of the T wave in Chihuahuas when compared to other canine breeds. This study aimed to clarify the polarity and shape of the T-wave in the lead V-10 in a group of healthy Chihuahuas. Retrospective electrocardiographic study with a sample of 20 private client-owned Chihuahuas. The conclusion was that the polarity of the T-wave is usually negative and the shape is asymmetric, type "slow-fast/down-up", in all dogs studied.

Keywords: Electrocardiogram; T-wave; Ventricular repolarization; Chihuahua; Dog.

Resumo

A onda T no eletrocardiograma canino pode ser positiva, negativa ou bifásica na maioria das derivações, enquanto sua amplitude não deve ser superior a 25% da onda R. Porém, desde a década de 1960 persiste a controvérsia à respeito da polaridade da onda T nos Chihuahuas quando comparada com as outras raças caninas. Nosso estudo objetivou esclarecer a polaridade e o formato da onda T na derivação V-10 em um grupo de Chihuahuas saudáveis. Estudo eletrocardiográfico retrospectivo de uma amostra de 20 Chihuahuas de clientela particular. A conclusão foi que a polaridade da onda T costuma ser negativa e o formato é assimétrico, tipo "lento-rápido/descendente-para cima", em todos os cães estudados.

Palavras-chave: Eletrocardiograma; Onda T; Repolarização ventricular; Chihuahua; Cão.

Resumen

La onda T en el electrocardiograma canino puede ser positiva, negativa o bifásica en la mayoría de las derivaciones, mientras que su amplitud no debe ser superior al 25% de la onda R. Sin embargo, desde la década de 1960 persiste la controversia respecto a la polaridad de la onda T en los Chihuahuas en comparación con otras razas caninas. Nuestro estudio tuvo como objetivo aclarar la polaridad y la forma de la onda T en la derivación V-10 en un grupo de chihuahuas sanos. Estudio electrocardiográfico retrospectivo con una muestra de 20 chihuahuas propiedad de clientes privados. La conclusión fue que la polaridad de la onda T suele ser negativa y la forma es asimétrica, tipo "lento-rápido/abajo-arriba", en todos los perros estudiados.

Palabras clave: Electrocardiograma; Onda T; Repolarización ventricular; Chihuahua; Perro.

1. Introduction

The electrocardiogram (ECG) is a graphical recording of the cardiac electrical activity. Historically, Augustus Desiré Waller in 1888 recorded the first canine, feline and human electrocardiograms with the Lipmann's capillary electrometer (Waller, 1888; Besterman & Creese., 1979; Tilley 1985). Few years later, Willem Einthoven announced the development of a string galvanometer electrocardiograph, a tremendous achievement in the field of Medicine (Einthoven, 1902). Nils Lannek (1949) created the thoracic exploring leads system CV5RL (RV2), CV6LU (V2) and CV6 LL (V4) for dogs (Tilley, 1985), later complemented by Hellerstein, and Hamlin (1960) who introduced the new thoracic lead CV10 (V10). Only in the 70's was edited the first textbook dedicated to canine electrocardiography (Bolton, 1975).

On the last 30 years veterinary electrocardiography gained continuous progress becoming an attractive, relatively inexpensive and useful technique to get information in cases of suspicion heart disease, electrolyte disturbances, drug toxicity, pre-surgical evaluation, diagnostic of cardiac arrhythmias, and in experimental research.

Although the history of canine electrocardiography dates back to the 19th century, only recently that the T-wave in the dog has become better characterized (Romito et al, 2022). In healthy dogs and cats, the T-wave shows variable shape and polarity in most leads, and may be positive, negative, biphasic or flat, and his two parts are asymmetric (Oliveira, 2018).

In the thoracic lead RV2 the T-wave usually is positive while in V10 is negative in normal dogs (Hill, 1968; Santilli et al., 2018). However, specifically in relation to Chihuahua's breed, persists controversy about the polarity of the T-wave in this lead, when compared to all other canine breeds. According the classical report of Detweiller and Patterson (1965), the canine T-wave have few requirements: it may be positive, negative or biphasic in most leads, his amplitude cannot be greater than 1/4 of amplitude of the corresponding R-wave, should be positive in the lead RV2 and negative V10, except in Chihuahuas in witch should be positive.

This possible exception or "peculiarity" of Chihuahuas have been replicated in many subsequent publications (Ettinger & Sutter, 1970; Bolton, 1975; Tilley et al., 1985; Miller & Tilley, 1988; Ware, 1994; Smith Jr. & Hadlock, 1995; 1; Smith Jr. & Fox, 1999; Nelson 2000; Montoya & Ramirez, 2007; Cotté & Ettinger, 2008; Filippi 2011; Macintire et al., 2012; Mazzini & Prada, 2020; Pascon 2021; Schroeder, 2021). Contradicting this discrepancy, Dijkstra and Szatmári (2009) reported that in Chihuahuas the T-wave in lead V10 is usually negative, rather than positive; therefore, it would not constitute an exception among the different canine breeds.

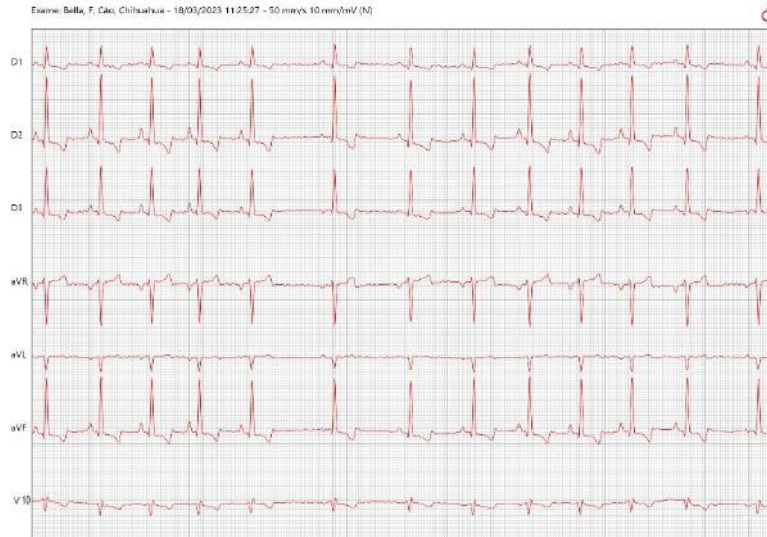
This research study aimed to clarify the polarity and shape of the T-wave in the lead V-10 in a group of healthy Chihuahuas. It followed the ethical principles of the Resolução Nº 55, de 5 de outubro de 2022 (Ministério da Ciência, Tecnologia e Inovações/Conselho Nacional de Controle de Experimentação Animal).

2. Material and Methods

Retrospective study with a convenient sample of 20 private client-owned Chihuahuas (10 female), in a random order. The group aged between one and 14-years (mean 4.8 years), considered healthy on the base of anamnesis, physical examination, systolic blood pressure measurement by the Doppler method (Doppler Flow Detector Model 811-B, Parks Medical Electronics Inc., Aloha-USA), and computed electrocardiography (Electrocardiograph In Cardio®, InPulse Animal Health, Florianópolis-Brazil). The ECG examination included the standard scalar limb leads D1, DII, DIII, aVR, aVL, aVF, and the thoracic V10 lead (figure 01), velocity of 50 mm/sec and sensitivity of 1cm=1 mV. The patients were restrained on right lateral recumbency during the procedure, according to Hellerstein & Hamlin (1960), and Hill (1968). The orthogonal modified lead system X, Y and Z was used to determine the spatial direction of the mean QRS-T vectors (figure 3). This system consists in that Lead X= lead I: right (-) to left (+); Lead Y= lead aVF: cranial (-) to caudal (+); Lead Z= lead V10:

ventral (-) to dorsal (+) as described by Hellerstein and Hamlin (1960); Detweiller and Patterson (1965); Tilley (1985); Trautvetter et al. (1981).

Figure 1 - 6-lead electrocardiogram of a healthy 8-year-old female Chihuahua.



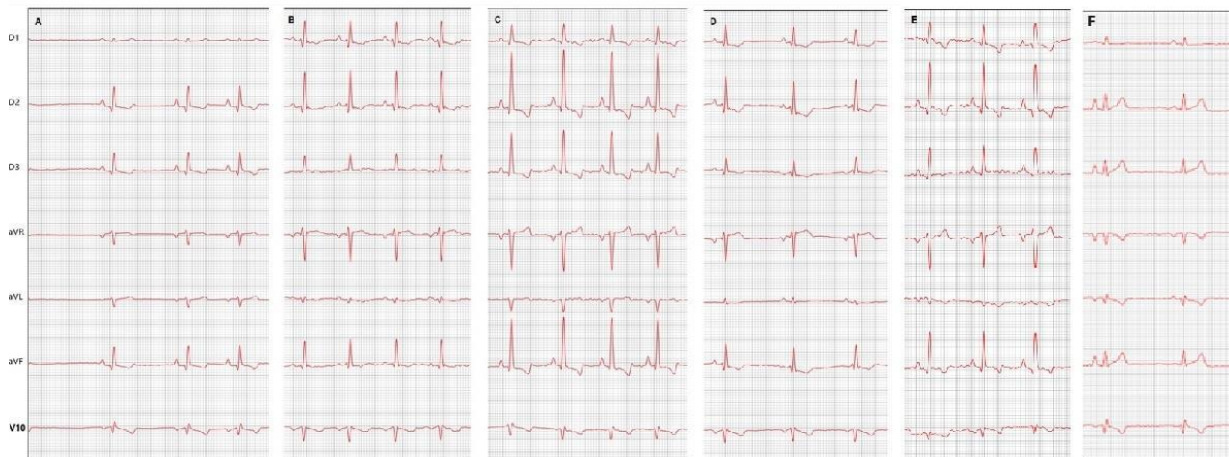
Source: Authors (2022).

ECG tracing showing sinus arrhythmia; HR= 153 bpm; QRS=54 msec. P duration=40 msec. Mean QRS axis= +76°; P axis =+74 ° (frontal plane); Qt=174ms; QTc=186 msec. PR= 60 msec. (lead D2). Note that the heart rate, rhythm, voltage, duration and shape of the QRS-T complexes exhibit a normal pattern for the species.

3. Results

All electrocardiographic values were within the normal reference ranges for the canine general population (Hill, 1968; Ettinger & Sutter, 1970; Tilley et al., 1992; Tilley et al., 2008; Willis R., 2018; Santilli et al., 2020, Romito et al., 2022). Six representatives ECG tracings of studied dogs are seen on the Figure 2.

Figure 2 - ECGs of six healthy Chihuahuas.

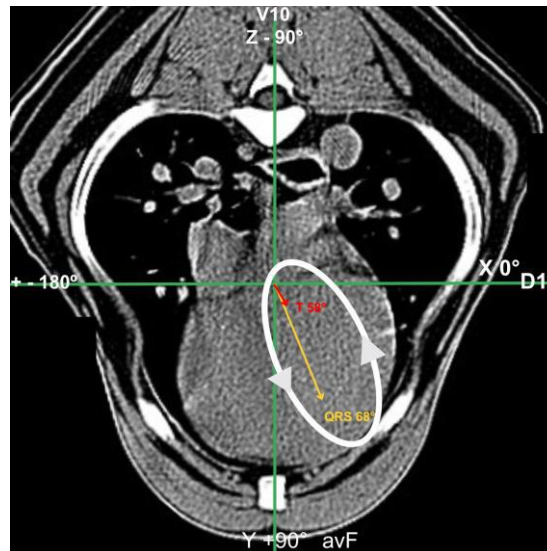


Source: Authors (2022).

Note the uniformity characteristics the QRST waves in the lead V10 lead from the Figure 2.

By using the scalar electrocardiogram (leads D1, aVF and V10) of the Figure 1, an illustrative vectorcardiogram was constructed (Figure 3).

Figure 3 - Tomographic view of the canine thorax, with vectorcardiogram constructed from the scalar leads of the Figure 1.



Source: Authors (2022).

As seen in the Figure 3, the mean vectors of QRS (yellow arrow) and T (red arrow) are both pointing to the left inferior quadrant. The mean QRS-vector is orientated at $+68^{\circ}$, while the mean T-vector is at $+58^{\circ}$. Arrowheads indicate the usual orientation of the QRS loop.

Specifically in relation to T waves in lead V10, all tracings showed Qr pattern, with polarity systematically negative, while the shape was asymmetrical, type “slow/fast” and “down/up”. There was a remarkable uniformity in the configuration of the QRS-T deflections of the V10 lead, in all ECG tracings (Figures 1 and 2).

4. Discussion

Because all Chihuahuas presented negative T-wave, i.e. his polarity was concordant to the polarity of QRS in the lead V10, it also contradicts several modern publications. In fact, our findings are in line with a previous report of Hill (1968) who, in a study with 25 different breeds, including Chihuahuas, first stated that T wave in lead V10 is primarily negative while in lead RV2 is positive. Our data are also concordant with Brownlie (2000), and with Digtsra & Zatmari (2009) who reported that the polarity of the T wave in V10 in healthy Chihuahuas is not positive. Because T-positivity in V10 could be indicative of right ventricular hypertrophy (Hill, 1971), was speculated that the Chihuahuas studied by Detweiller and Patterson (1965) could have silent right ventricular hypertrophy and was not detected, since echocardiography was not available at that time (Digtsra & Zatmari 2009).

Ventricular depolarization and repolarization are three-dimensional phenomena by nature and can be represented, therefore, by projection of QRS-T forces onto the three orthogonal planes X, Y and Z, in order to generate the vectorcardiogram (VCG) (Riera et al 2007).

The vectorcardiogram is a form of electrocardiography that represents the direction and values of vectorial forces generated during the cardiac electrical activation, moment-to-moment, and is analyzed in the planes transverse, frontal and sagittal (Riera et al 2007).

In the VCG of normal dogs the direction of the mean QRS vector forces are usually orientated leftward, ventral and caudal, giving QRS positivity in D1, D2, and D3, and in V10 negativity (Hamlin & Smith, 1960; Trautvetter et al., 1981). In fact, the direction of the QRS-T vectors in the transverse plane are scattered between 45 and 90 degrees (Hellerstein & Hamlin, 1960; Detweiller 2010). In this case, the rationale is that the polarity of the QRS and of T should be concordant with each other in lead V-10, as shown in the figure 3, in which the modal QRS and T vectors are projecting to the same quadrant.

In adult normal dogs and cats, as well as in humans, the loop of ventricular activation is orientated in counter-clockwise rotation, considering the three orthogonal planes (Detweiller 2010; Ettinger and Sutter, 1970; Hellerstein H. K. and Hamlin, 1960; Pastore C.A. et al., 2019). Regarding morphology of the T-wave in lead V10, all ECGs presented asymmetrical pattern, with two components, type “down/up and slow/fast”, which is in line with study of Romito et al, 2022.

5. Conclusion

The results obtained in this study confirm that, in adult healthy Chihuahuas, the polarity of T wave in the lead V10 is usually negative, concordant with QRS polarity, his morphology is asymmetric, type “down/up and slow/fast”.

Conflict of interest

There is no conflict of interest relative to this work.

References

- Bestermann E. & Creese R. (1979). *Waller--pioneer of electrocardiography*. *Br Heart J.* 42(1): 61–64. 10.1136/hrt.42.1.61.
- Bolton G. R. (1975). Interpreting the electrocardiogram. *Handbook of canine electrocardiography*. WB Saunders. 39-87.
- Brownlie S. (2000). Electrocardiografía. In: *Manual de medicina y cirugía cardiorespiratoria en pequeños animales*. Fuentes V.L. & Swift S. Editora Harcourt. Madrid. pg. 83-92.
- Detweiler K. & Patterson D. F. (1965). The prevalence and types of cardiovascular diseases of dogs. *Annals of the New York Academy of Sciences*. Volume (127): 481–516.
- Detweiller D. K. (2010). The Dog Electrocardiogram. A Critical Review. In: *Comprehensive Electrocardiology*. Macfarlane, P.W., van Oosterom, A., Pahlm, O., Kligfield, P., Janse, M., Camm, J. (Eds.) Springer, London. <https://doi.org/10.1007/978-1-84882-046-3-41>.
- Dijkstra M. & Szatmári V. (2009). The T wave in the V-10 precordial electrocardiographic lead is negative in healthy Chihuahua dogs. *J. Vet. Cardiol.* 11(2): 123-127. DOI: 10.1016/j.jvc.2009.04.004.
- Einthoven W. (1902). Galvanometrische registratie van het menschelijk electrocardiogram. In: *Herinneringsbundel SS* ed. Rosenstein: Leiden Eduard Ijdo Leiden, 1902:101–106.
- Ettinger S. J. & Sutter P. F. (1970). Electrocardiography. In: *Canine Cardiology*. pp. 102-169.
- Filippi L. H. (2011). Traçado Eletrocardiográfico Normal. In: *O Eletrocardiograma na Medicina Veterinária*. Editora Rocca. 69-88.
- Hamlin L. R & Smith C. R. (1960). Anatomical and physiologic basis for interpretation of the electrocardiogram. *Am J Vet Res.* 21:701–708.
- Hellerstein H. K. & Hamlin R. (1960). Component of the Spatial Vectorcardiogram and of the Spatial Magnitude and Velocity Electrocardiograms of the Normal Dog. *Am J Cardiol.* (6),1049-61. 10.1016/0002-9149(60)90360-x.
- Hill J. D. (1968). The Electrocardiogram in Dogs with Standardized Body and Limb Positions. *J. Electrocardiology* 1(2), 347-357.
- Hill J. D. (1971). Electrocardiographic Diagnosis of Right Ventricular Enlargement in Dogs. *J. Electrocardiology* 4 (4), 347-357.
- Lannek, N. (1949). *A clinical and experimental study on the electrocardiogram in dogs*. Thesis, Stockholm.
- Macintire D. K, Drobatz J. K., Haskins S. C. & Saxon W. D. (2012). Normal Values for the Canine and Feline Electrocardiogram. *Animal Emergency and Critical Care Medicine*, Second Edition. John Wiley & Sons, Inc.

- Mazzini A. M. & Prada D. G. (2020). Eletrocardiografia. In: Larsson MHMA Organizadora. *Tratado de Cardiologia de Cães e Gatos*. p. 61-85. Interbook Editorial. São Paulo.
- Miller M. S., Tilley L. P., Smith Jr. & F. W. K., & Fox P. R. (1999). Electrocardiography. In: *Textbook of Canine and Feline Cardiology. Principles and Clinical Practice*. Second edition.
- Fox P F. Et al., Eletrocardiography. In: *Textbook of Canine and Feline Cardiology*, Sisson D. and Moise N.S. Eds. W.B. Saunders Company. Philadelphia. New York. 67-105.
- Montoya Alonso J. A. & Ramirez I. (2007). Complejo QRS. In: *Manual Practico de Electrocardiografia em Pequenos Animales*. Elsevier-Masson, Barcelona. 85-96.
- Oliveira P. (2018). *Guide to Canine and Feline Electrocardiography*. Ruth Willis, Pedro Oliveira & Antonia Mavropoulou. Wiley & Sons Ltd. John Wiley & Sons Ltd.
- Pascon J. P. E. (2021). Módulo de Eletrocardiografia. *Terapia Antiarrítmica- Cães e gatos*. Editora Equalis.
- Pastore C. A. et al. (2019). ECG/VCG in the current clinical practice. *Arq. Bras. Cardiol*. 113(1): 87-99.
- Romito G., Castagna P., Pelle N. G., Testa F, Sabetti M. C., & Cipone M. (2022). The canine T wave: a retrospective analysis on qualitative and quantitative T wave variables obtained in 129 healthy dogs and proposed reference intervals. *Journal of Veterinary Cardiology* 42: 52-64.
- Santilli R, et al. (2021). *Eletrocardiografia de cães e gatos. Diagnóstico de arritmias*. Segunda Edição. Med-Vet.
- Schroeder N. *Interpretation of the Electrocardiogram in Small Animals*. John Wiley & Sons Inc. Hoboken, NJ 07030, USA.
- Tilley L. P. (1985). Analysis of P-QRS-T deflections. *Essentials of canine and feline electrocardiography*. Second ed., Lea and Febiger, Philadelphia, USA, pp. 57-97.
- Tilley L P, Miller M S & Smith Jr. F W K (1993). *Canine and Feline Arrhythmias*. Lea & Febiger Eds., Pensilvania.
- Tilley L. P., Francis W. K. Smith Jr. & F. W. K. (2008). Chapter 3. Electrocardiography.in: *Manual of Canine and Feline Cardiology*. Fourth Edition by: Tilley L.P., Smith Jr. F.W.K. Sleeper M.M.
- Trautvetter E., Detweiler D. K. & Patterson D. F. (1981). Evolution of the electrocardiogram in young dogs during the first 12 weeks of life. *Journal of Electrocardiology*. Volume 14, Issue 3: 267-274.
- Waller A. D. (1888). Introductory address on the electromotive properties of the human heart. *The British Medical Journal*, October: 751-754.
- Ware W. (1994). Distúrbios do Sistema Cardiovascular. In: *Fundamentos de Medicina Interna de Pequenos Animais*. Nelson R. and Couto C.G. Guanabara Koogan Editora. Rio de Janeiro.
- Willis R. (2018). Electrocardiography. In: *Guide to Canine and Feline Electrocardiography* Willis R., Oliveira P. and Mavropoulou A. (Eds.). Wiley & Sons Ltd. Oxford, UK.