

An eye-tracking and questionnaire study of how facial pigmentation spot are perceived by laypeople

Um estudo de rastreamento do olhar e questionário sobre como manchas de pigmentação facial são percebidas por leigos

Un estudio de seguimiento ocular y cuestionario sobre cómo las manchas de pigmentación facial son percibidas por los legos

Received: 12/16/2023 | Revised: 12/29/2023 | Accepted: 01/02/2024 | Published: 01/05/2024

Orlando Motohiro Tanaka

ORCID: <https://orcid.org/0000-0002-1052-7872>
Pontifícia Universidade Católica do Paraná, Brazil
E-mail: tanakaom@gmail.com

Gil Guilherme Gasparello

ORCID: <https://orcid.org/0000-0002-8955-6448>
Pontifícia Universidade Católica do Paraná, Brazil
E-mail: gilguilhermeg@hotmail.com

Augusto Hideki Berlesi

ORCID: <https://orcid.org/0009-0001-3489-6752>
Pontifícia Universidade Católica do Paraná, Brazil
E-mail: berlesiaugusto1@gmail.com

Luiz Gustavo Healt de Lima

ORCID: <https://orcid.org/0009-0005-9869-2707>
Pontifícia Universidade Católica do Paraná, Brazil
E-mail: luizhealt@hotmail.com

Gabriel Ingles Buche

ORCID: <https://orcid.org/0009-0009-8554-5539>
Pontifícia Universidade Católica do Paraná, Brazil
E-mail: gab.buche19@gmail.com

Luiz Fernando Iyda Miyagusuku

ORCID: <https://orcid.org/0009-0005-3812-2665>
Pontifícia Universidade Católica do Paraná, Brazil
E-mail: luizmiyagfernando@gmail.com

Matheus Melo Pithon

ORCID: <https://orcid.org/0000-0002-8418-4139>
Southwest Bahia State University, Brazil
E-mail: matheuspithon@gmail.com

Abstract

Facial skin pigmentation is one of the most prominent visible features in everyday interactions and often influences the perception of beauty. There is currently no evidence on how facial pigmentation spots can influence aesthetic perception. The objective was to evaluate the perception of aesthetics and the attractiveness of smiling photos with the presence of facial pigmentation spots in different locations on the face. Four images of the smiling face were used in the frontal pattern, standardized and modified with the help of Photoshop®: no pigmentation spots, spots below the right perioral region, above the upper left perioral region, and in both the lower right region and upper left region of the face. The Eye-tribe hardware and Ogama software were used for eye-tracking, and a questionnaire with two questions — “Judging aesthetic aspects, do you consider this person attractive and beautiful?” and “What stood out the most about this image?” were applied to laypeople observers with a word cloud typed on the Mentimeter. The dot maps showed that in all pigmentation spots positions, the right eye and the smile in the area of the central incisors attracted the most attention of laypeople. The smile was the most cited, with emphasis on the words 'eyes' and 'teeth' in Mentimeter. Facial pigmentation spots in different locations did not interfere with aesthetic perception. The face without the presence of nevi was considered the most attractive, and the smile, teeth, and eyes were the structures that most caught the attention of the laypeople.

Keywords: Eye-tracking; Attractiveness; Facial esthetics; Pigmentation spots.

Resumo

A pigmentação da pele facial é uma das características visíveis mais proeminentes nas interações cotidianas e frequentemente influencia a percepção de beleza. Atualmente, não há evidências sobre como manchas de pigmentação

facial podem influenciar a percepção estética. O objetivo foi avaliar a percepção estética e a atratividade de fotos sorridentes com a presença de manchas de pigmentação facial em diferentes localizações no rosto. Quatro imagens do rosto sorridente foram usadas no padrão frontal, padronizadas e modificadas com a ajuda do Photoshop®: sem manchas de pigmentação, manchas abaixo da região perioral direita, acima da região perioral superior esquerda e em ambas as regiões inferior direita e superior esquerda do rosto. O hardware Eye-tribe e o software Ogama foram usados para rastreamento ocular, e um questionário com duas perguntas — “Julgando aspectos estéticos, você considera esta pessoa atraente e bonita?” e “O que mais chamou sua atenção nesta imagem?” — foram aplicados a observadores leigos com uma nuvem de palavras digitada no Mentimeter. Os mapas de pontos mostraram que, em todas as posições das manchas de pigmentação, o olho direito e o sorriso na área dos incisivos centrais atraíram mais a atenção dos leigos. O sorriso foi o mais citado, com ênfase nas palavras 'olhos' e 'dentes' no Mentimeter. Manchas de pigmentação facial em diferentes localizações não interferiram na percepção estética. O rosto sem a presença de nevos foi considerado o mais atraente, e o sorriso, os dentes e os olhos foram as estruturas que mais chamaram a atenção dos leigos.

Palavras-chave: Rastreamento ocular; Atratividade estética facial; Manchas de pigmentação.

Resumen

La pigmentación de la piel facial es una de las características visibles más prominentes en las interacciones cotidianas y a menudo influye en la percepción de la belleza. Actualmente, no hay evidencias sobre cómo las manchas de pigmentación facial pueden influir en la percepción estética. Evaluar la percepción estética y la atracción de fotos sonrientes con la presencia de manchas de pigmentación facial en diferentes ubicaciones en el rostro. Métodos: Se utilizaron cuatro imágenes de la cara sonriente en el patrón frontal, estandarizadas y modificadas con la ayuda de Photoshop®: sin manchas de pigmentación, manchas debajo de la región perioral derecha, encima de la región perioral superior izquierda y en ambas regiones inferior derecha y superior izquierda de la cara. Se utilizaron el hardware Eye-tribe y el software Ogama para el seguimiento ocular, y se aplicó un cuestionario con dos preguntas: “¿Juzgando aspectos estéticos, ¿considera usted a esta persona atractiva y hermosa?” y “¿Qué fue lo que más le llamó la atención de esta imagen?” a observadores legos con una nube de palabras escrita en Mentimeter. Los mapas de puntos mostraron que en todas las posiciones de las manchas de pigmentación, el ojo derecho y la sonrisa en el área de los incisivos centrales atrajeron más la atención de los legos. La sonrisa fue lo más citado, con énfasis en las palabras 'ojos' y 'dientes' en Mentimeter. Las manchas de pigmentación facial en diferentes ubicaciones no interfirieron en la percepción estética. El rostro sin la presencia de nevos fue considerado el más atractivo, y la sonrisa, los dientes y los ojos fueron las estructuras que más captaron la atención de los legos.

Palabras clave: Seguimiento ocular; Atractivo; Estética facial; Manchas de pigmentación.

1. Introduction

Skin well-being and esthetics significantly impact one's confidence and interpersonal relationships (Gupta & Gilcrest, 2005). As society increases the value of a younger appearance, facial appearance is important to many individuals: especially women (Coma et al., 2014).

The skin is important in regulating body temperature and provides immune protection. It contains sensory and autonomic nerves, as well as sensory receptors, which detect touch, vibration, pressure, temperature, pain, and itching stimuli, and due to its role in health, great care must be taken with it (Khavkin & Ellis, 2011).

The dysplastic nevus (Clark's nevus) (Clark et al., 1978) is described as the accumulation of dermal melanocytes, arising from melanoma cell families. Despite studies dealing with their histological and morphological analysis (Bierhoff, 2015a; Conway et al., 2011) the aesthetic impact of the nevus, here nominated pigmentation spot has not been explored.

Photographs are used to assess several variables in the face, such as smile aesthetics and facial symmetry (Jarosz et al., 2018). Photographs may be associated with eye-tracking technology to assess visual perception of facial and dental structures (Fudalej, 2008). Eye-tracking is a system used in dentistry which captures eye movements through a device that projects images for analysis (Yamamoto et al., 2017). Current research has focused on how we visually perceive facial and dental features (Bastos et al., 2022; Wong et al., 2018), as used in the evaluation of orthodontic treatment (Richards et al., 2015). The use of this technology can complement the assessment of the visual analogue scale (VAS), enabling analysis that addresses the psychosocial aspect of facial and dental aesthetics.

The perception of beauty and attractiveness are affected by biological, psychological, cultural and social factors (Maymone et al., 2019). Although aesthetic standards may change over time (Bashour, 2006), characteristics commonly

considered favorable to beauty and facial attractiveness generally include skin symmetry and homogeneity (Maymone et al., 2019): that is, uniform color and texture (Samson et al., 2010). In addition, the perception of age plays an important role in beauty and attractiveness, with a youthful appearance positively influencing the perception of facial attractiveness (Bashour, 2006).

The effect of the presence of pigmentation on the skin can be subjectively perceived by individuals, and is commonly seen as a potential problem for everyday interactions, where subtle social signals are often important (Hess et al., 2012). Despite this, there is no research addressing how irregular pigmentation can influence aesthetic perception.

Therefore, the aim of this study was to evaluate the perception of aesthetics and attractiveness in photos of a young Caucasian female model, adopting a smiling face, with the presence of pigmentation spots across different regions of the face.

2. Methodology

The project was approved by the research ethics committee of the University (registration number: 3,729,413).

All models and participants gave written consent via signature. The photos were taken with a Canon Rebel XTI camera (Canon, Tokyo, Japan) of a smiling face of a young Caucasian female model from a frontal view. The selected images were standardized and modified, adding a pigmentation spots on the face, by using the Photoshop® program (Adobe Systems Inc, San Jose, California), with the main tools being ‘dissolve’, ‘stamp’, and ‘rectangular sign’. These modifications are seen in Figure 1: A. Upper left perioral region. B. Right cheek and upper left. C. Underneath the right perioral region. D. Without.

Figure 1 - Face with each different pigmentation spot position: A. Upper left perioral region. B. Right cheek and upper left. C. Underneath the right perioral region. D. Without.



Source: Authors.

Observers

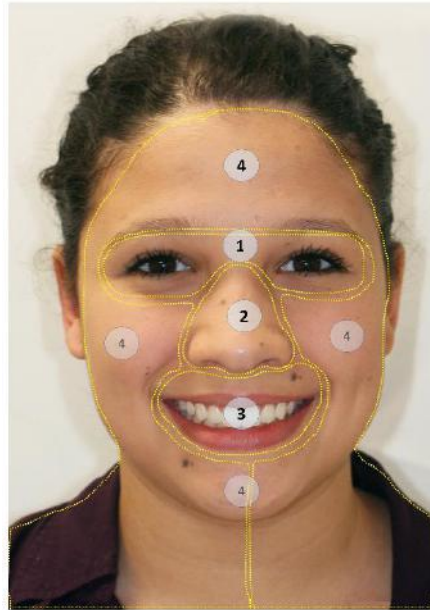
The number of lay observers included in this study was based on previous studies (de Oliveira et al., 2019), and in the present study, constituted 53 females (58.24%) and 38 males (41.76%). The youngest observer was 18 and the oldest was 67, with a mean age of 25.51 years old across the group. Regarding skin tone as a proxy for ethnicity, 75 self-declared as white, 2 as yellow, 13 as black or brown and 1 self-declared as “other”. Regarding the level of education, 55 had accessed incomplete higher education and 36 had completed higher education.

Data Collection

To use the Ogama software, areas of interest (AOI) were added in: 1 – Eyes; 2 – Nose; 3 – Smile; 4 – Other regions of the face (Figure 2). 91 laypeople participated without any prior knowledge of what they were evaluating. This number of subjects

was based on previous studies (de Oliveira et al., 2019). Observers signed their consent and stated they both had good vision and did not take medication that could interfere with cognitive or motor skills. As a prerequisite for correct and reliable tracking to occur, the software was calibrated to a degree considered "perfect".

Figure 2 - Areas of interest (AOI).



Source: Authors.

For the data collection, the observers were instructed to sit comfortably in a chair between 60-90 centimeters from a 17-inch Dell P2317H monitor (Dell Inc. Round Rock, Texas) in an upright position, where the images were then projected vertically to maintain their actual size. The Eye Tribe hardware (The Tribe Aps, Copenhagen, Denmark) was positioned just below the monitor as per the manufacturer's recommendations. The 4 photos, each shown for 5 seconds, were projected individually to the observers.

Questionnaire

In the second stage of data collection, the observers were invited to answer 2 questions (Meira et al., 2021) about attractiveness. For these questions a visual analog scale was used in which 0 denoted least attraction and 10 denoted most attraction: 1. "Judging aesthetic aspects, do you consider this person attractive and beautiful?" 2. "Where does your attention go to in this image?" The answers were used to create word clouds on the Mentimeter online platform.

Statistical Analysis

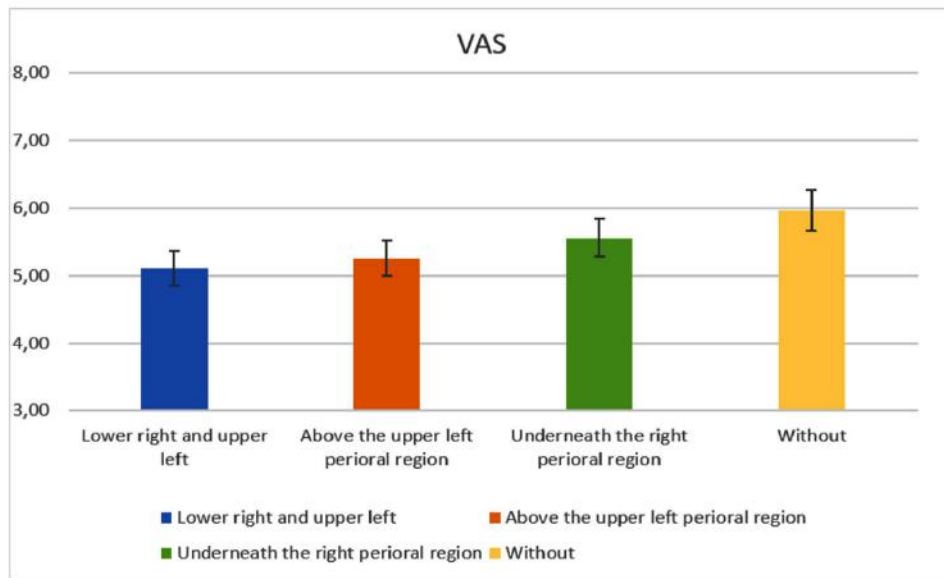
For the statistical analysis, all the data were formatted in Microsoft Excel and analyzed in the Statistical Package for Social Sciences version 25 (SPSS; SPSS Inc., Chicago, IL) program. One-way analysis of variance (ANOVA) was applied for the VAS score. Post-hoc testing was conducted to identify statistical differences; in the event of a homogeneous population, Tukey's honestly significant difference was used, and in the event of a heterogeneous population, Games-Howell test was applied.

3. Results

30 laypeople replied to the questionnaires twice, with a 20-day interval in between, to perform the test and retest. The questionnaire showed a good level of internal consistency (Cronbach alfa 0.84).

Regarding VAS, no statistical difference was found ($p = 0.130$), (Figure 3), meaning for all images, the facial nevi were not an essential detail determining attractiveness. However, sexual dimorphism ($p < 0.001$) was recorded, in which the females (mean = 6.17) tended to score higher points than the males (mean = 4,96). Further, the educational background did not show differences for VAS between graduate and non-graduate participants ($p > 0.05$). (Figure 3).


Figure 3 - VAS scores.



Source: Authors.

In the analysis of the results, when assessing the dots maps (which showed where each point of the tracking was registered), it was observed that in all spots positions, the right eye and the smile in the area of the central incisors drew more attention from the observers, as characterized by the higher density of points (Figure 4).

Figure 4 - Point maps: A. Upper left perioral region. B. Right cheek and upper left. C. Underneath the right perioral region. D. Without.




Source: Authors.

In the analysis of Figure 3, it is possible to observe very similar scores for all images: the face with no pigmentation spots had higher scores, but with a small difference when compared to the other images. The question “Where does your attention go to in this image?” was asked when showing images: With the spot underneath the right perioral region. Without the spots. With the spot in the upper left perioral region. With spots in the right cheek and upper left regions.

The answers were then collected in the Mentimeter word cloud, in which the observers marked “the smile” as the most cited answer, with emphasis on the words 'eyes' and 'teeth'. The word spot was mentioned, but only with limited frequency, proving not to be the central focus in the perception of attractiveness (Figure 5).

Figure 5 - Word clouds on the Mentimeter online platform. A. Upper left perioral region. B. Right cheek and upper left. C. Underneath the right perioral region. D. Without.



Source: Authors.

4. Discussion

The present study had the participation of 91 laypeople, with the objective of evaluating, via eye-tracking, how the presence of pigmentation spots in the perioral region may interfere with the perception of the attractiveness of the face as modeled in photographs of a female individual smiling.

The impact of pigmentation spots on social perception remains a topic of much discussion, but the results of this survey demonstrate that facial pigmentation spots are not perceived differently, or to have negative or unfavorable aesthetics, by lay observers.

Aesthetic appearance has been prioritized with increasing frequency in orthodontic treatment (de Oliveira et al., 2019) and in dentistry generally (Blatz et al., 2019). Pigmentation spots are more prevalent in the young population, between 30 and 40 years of age, and usually start at puberty (Arumi-Uria, 2008; Naeyaert & Brochez, 2003). The incidence may vary from 1.5% to 18%, which makes their appearance relatively common (Rezze et al., 2010).

These spots must be not evaluated solely for aesthetics purposes: the lesions can be indicators of an increased risk of melanoma or direct biological precursors of malignant melanomas (Bierhoff, 2015b). The aesthetic perception of pigmentation spots are also important, but they should primarily be investigated by a trained professional to help prevent malignant disease.

Many patients express the desire to remove the melanocytic nevus, especially those located on the face. Nevi over 5 millimeters in diameter are a major complaint of patients and, consequently, patients often desire their removal (Ozaki et al.,

2014). This significance of size may be mirrored in the results of the present study, in which the observers did not notice aesthetic impairment, with the nevi being smaller than 5 millimeters in diameter.

During an interpersonal interaction, an individual's focus is primarily on the other person's eyes and mouth, with little time spent looking at other facial features (Ioi et al., 2012), with a tendency to prefer the left direction over the right and clockwise (Karim et al., 2016). In the present study, a greater tendency to fix the gaze on the right eye of the image was observed, followed by the left eye and the smile region, and in the images with the pigmentation spots, the observers visualized mostly either in the upper left, lower right or in the presence of both.

Although the eyes are considered the region with the highest tendency for initial visualization in social contact (Ioi et al., 2012), the observers recorded the word "smile" as the most striking in the images evaluated without the presence of pigmentation spots. This may be explained in the way that the presence of pigmentation spots in the perioral region led observers to perceive that other facial features drew greater attention.

Regarding the gingival exposure in the smile morphology used in the present study, the normal amount of gingiva exposed in a vertical smile was considered, as the upward or straight curvature of the upper lip has a positive impact on the perception of the aesthetics of the smile (Valverde-Montalva et al., 2021).

While symmetry is considered an important prerequisite for an attractive face, many asymmetrical faces are still considered beautiful. This factor was considered in the present smiling face, although some studies have mirrored the right and left sides of the face, becoming perfectly symmetrical (Gasparello et al., 2022), to minimize bias of observation.

Facial cross-sectional studies with completely symmetrical composite faces do not allow consideration of small asymmetries such as a "beauty spot" or an asymmetrically slanted eye (Perrett et al., 1994). Springer et al. (Springer et al., 2007) analyzed how a single pigmentation spot can be considered a "beauty spot" and how asymmetrically slanted eyes can still be perceived as attractive and concluded that a unilateral facial pigmentation spot that can be considered a "beauty spot", while a symmetrical facial pigmentation spot that can be considered a "beauty spot" in the same position receives worse ratings. The closer to the midline a unilateral pigmentation spot is, the less attractive it is considered.

When looking at an inanimate object, the contours and prominent ornaments are the preferred targets of the gaze (Mertens et al., 1993), suggesting that, for human faces the midline area plays a crucial role in judgments of attractiveness (Springer et al., 2007), and as observed in the present study.

In the present study, the face without the pigmentation spots was the most attractive, in agreement with Springer et al (Springer et al., 2007). Even on the face with the presence of two pigmentation spots, the smile was the main focus, although the word "spot" was noticed by observers. A convex smile with an aligned teeth is often the point of focus for the laypeople observers.

While symmetrical faces are the most attractive, there are other characteristics that have not yet been objectively defined, such as skin texture (Penton-Voak et al., 2001), and in the present study, a natural face was used, without the mirroring of the right and left hemi-faces, keeping the asymmetries in the hair, cheeks and ears. Only the pigmentation spot positioning was added virtually by computer.

Teeth color and shape, tooth spacing or missing teeth, and prominent maxillary anterior teeth were the most common dentofacial features that contributed to self-harm as a result of bullying in Jordan (Al-Bitar et al., 2022), bringing into question how the results of these malocclusions might interact with the presence of pigmentation spots as evaluated in different cultures.

Adolescents are shown to place great importance on dental appearance (Phillips & Beal, 2009), and healthy, well-groomed teeth were important in appearance (Grzywacz, 2003), as an adolescent's self-perception of attractiveness level for the dentofacial region was an important factor which contributed to their self-esteem. (Badran, 2010) Further, in the present study,

the presence of pigmentation spots was in the background, and one of the reasons may be the fact that teeth alignment in a smile consonant with high levels of attractiveness (Tanaka et al., 2022).

However, it may be that the presence of pigmentation spots in teeth with malocclusions such as diastema, missing teeth and altered coloration influence perceived attractiveness levels. In this case, lesions may need to be removed by clinicians, with biopsy use in doubtful cases (Guder & Guder, 2022).

This study's limitations include the possibility that participants might respond differently to images on a screen compared to real-life encounters at social events. This adds to the inherent subjectivity in judging attractiveness. However, despite this issue, the findings from eye-tracking are credible as they represent the perspective of an average layperson's point of view.

The present study addressed an important issue for society, and for dentists, dermatologists, and plastic surgeons, among other professionals who work directly with the face and attractiveness, as it showed how the presence of pigmentation spots influences facial and smile attractiveness. However, regardless of where the spot is located, the main points observed and the focus of the observers' perception remain the same.

5. Conclusions

Pigmentation spots in different sites did not interfere with aesthetic perception. The smile without the presence of pigmentation spots was considered the most attractive, and the smile, teeth, and eyes were the structures that most caught the attention of the observers. A smile with aligned teeth is the point of focus for laypeople observers.

References

- Al-Bitar, Z. B., Sonbol, H. N., Al-Omari, I. K., Badran, S. A., Naini, F. B., Al-Omiri, M. K., et al. (2022). Self-harm, dentofacial features, and bullying. *Am J Orthod Dentofacial Orthop*, 162(1), 80-92. [10.1016/j.ajodo.2021.02.025](https://doi.org/10.1016/j.ajodo.2021.02.025).
- Arumi-Uria, M. (2008). Dysplastic nevus: the eye of the hurricane. *J. Cutan. Pathol*, 35, 16-19. [10.1111/j.1600-0560.2008.01142](https://doi.org/10.1111/j.1600-0560.2008.01142).
- Badran, S. A. (2010). The effect of malocclusion and self-perceived aesthetics on the self-esteem of a sample of Jordanian adolescents. *Eur J Orthod*, 32(6), 638-644. [10.1093/ejo/cjq014](https://doi.org/10.1093/ejo/cjq014).
- Bashour, M. (2006). History and current concepts in the analysis of facial attractiveness. *Plast Reconstr Surg*, 118(3), 741-756. [10.1097/01.prs.0000233051.61512.65](https://doi.org/10.1097/01.prs.0000233051.61512.65).
- Bastos, S. Q., Tanaka, O. M., Kirsten, G. A., Gasparello, G. G., Meira, T. M., Camargo, E. S., et al. (2022). Esthetic perception of gummy smile with the application of botulinum toxin, via eye-tracking. *Research, Society and Development*, 11(6), e56111629518. <https://doi.org/10.33448/rsd-v11i6.29518>.
- Bierhoff, E. (2015a). Dysplastic melanocytic nevus. *Der Pathologe*, 36(1), 46-50, 52. [10.1007/s00292-014-2061-5](https://doi.org/10.1007/s00292-014-2061-5)
- Bierhoff, E. (2015b). Dysplastischer melanozytärer Nävus. *Der Pathologe*, 36(1), 46-52. [10.1007/s00292-014-2061-5](https://doi.org/10.1007/s00292-014-2061-5).
- Blatz, M., Chiche, G., Bahat, O., Roblee, R., Coachman, C., & Heymann, H. (2019). Evolution of aesthetic dentistry. *J Dent Res*, 98(12), 1294-1304. [10.1177/0022034519875450](https://doi.org/10.1177/0022034519875450).
- Clark, W. H., Reimer, R. R., Greene, M., Ainsworth, A. M., & Mastrangelo, M. J. (1978). Origin of familial malignant melanomas from heritable melanocytic lesions: The BK mole syndrome. *Arch Dermatol*, 114(5), 732-738.
- Coma, M., Valls, R., Mas, J. M., Pujol, A., Herranz, M. A., Alonso, V., et al. (2014). Methods for diagnosing perceived age on the basis of an ensemble of phenotypic features. *Clin Cosmet Invest Dermatol*, 7, 133-137. [10.2147/CCID.S52257](https://doi.org/10.2147/CCID.S52257).
- Conway, K., Edmiston, S. N., Khondker, Z. S., Groben, P. A., Zhou, X., Chu, H., et al. (2011). DNA-methylation profiling distinguishes malignant melanomas from benign nevi. *Pigment cell & melanoma research*, 24(2), 352-360. [10.1111/j.1755-148X.2011.00828.x](https://doi.org/10.1111/j.1755-148X.2011.00828.x).
- de Oliveira, W. L., Saga, A. Y., Ignácio, S. A., Justino, E. J. R., & Tanaka, O. M. (2019). Comparative study between different groups of esthetic component of the Index of Orthodontic Treatment Need and eye tracking. *Am J Orthod Dentofacial Orthop*, 156(1), 67-74. [10.1016/j.ajodo.2018.07.026](https://doi.org/10.1016/j.ajodo.2018.07.026).
- Fudalej, P. (2008). Long-term changes of the upper lip position relative to the incisal edge. *Am J Orthod Dentofacial Orthop*, 133(2), 204-209; quiz 328 e201. [10.1016/j.ajodo.2006.04.040](https://doi.org/10.1016/j.ajodo.2006.04.040).
- Gasparello, G. G., Acciaris, F., Mota-Júnior, S. L., Castilhos, J. S., Bark, M. J., Hartmann, G. C., et al. (2022). Perception of mandibular position in Caucasian models in a sagittal view via eye-tracking. *Research, Society and Development*, 11(6), e15411629036. [10.33448/rsd-v11i6.29036](https://doi.org/10.33448/rsd-v11i6.29036).

- Gasparello, G. G., Junior, S. L. M., Hartmann, G. C., Meira, T. M., Camargo, E. S., Pithon, M. M., et al. (2022). The influence of malocclusion on social aspects in adults: study via eye tracking technology and questionnaire. *Prog Orthod*, 23(1), 4. 10.1186/s40510-022-00399-3.
- Grzywacz, I. (2003). The value of the aesthetic component of the Index of Orthodontic Treatment Need in the assessment of subjective orthodontic treatment need. *Eur J Orthod*, 25(1), 57-63. 10.1093/ejo/25.1.57.
- Guder, S., & Guder, H. (2022). "Mole removal" on Instagram Hashtags: A Cross-sectional Analysis: Nevus Treatment Methods on Instagram. *Dermatol Pract Concept*, 12(1), e2022066. 10.5826/dpc.1201a66.
- Gupta, M. A., & Gilcrest, B. A. (2005). Psychosocial aspects of aging skin. *Dermatol Clin*, 23(4), 643-648. 10.1016/j.det.2005.05.012.
- Hess, U., Adams, R. B., Jr., Simard, A., Stevenson, M. T., & Kleck, R. E. (2012). Smiling and sad wrinkles: Age-related changes in the face and the perception of emotions and intentions. *J Exp Soc Psychol*, 48(6), 1377-1380. 10.1016/j.jesp.2012.05.018.
- Ioi, H., Kang, S., Shimomura, T., Kim, S. S., Park, S. B., Son, W. S., et al. (2012). Effects of buccal corridors on smile esthetics in Japanese and Korean orthodontists and orthodontic patients. *Am J Orthod Dentofacial Orthop*, 142(4), 459-465. 10.1016/j.ajodo.2012.05.011.
- Jaroszk, K. F., Bosio, J. A., Bloomstein, R., Jiang, S. S., Vakharia, N. S., & Cangialosi, T. J. (2018). Perceptions of chin asymmetries among dental professionals and laypersons. *Am J Orthod Dentofacial Orthop*, 154(2), 201-212. 10.1016/j.ajodo.2017.11.029.
- Karim, A. R., Proulx, M. J., & Likova, L. T. (2016). Anticlockwise or clockwise? A dynamic Perception-Action-Laterality model for directionality bias in visuospatial functioning. *Neuroscience & Biobehavioral Reviews*, 68, 669-693. <https://doi.org/10.1016/j.neubiorev.2016.06.032>
- Khavkin, J., & Ellis, D. A. (2011). Aging skin: histology, physiology, and pathology. *Facial Plast Surg Clin North Am*, 19(2), 229-234. 10.1016/j.fsc.2011.04.003.
- Maymone, M. B., Laughter, M., Dover, J., & Vashi, N. A. (2019). The malleability of beauty: perceptual adaptation. *Clin Dermatol*, 37(5), 592-596. 10.1016/j.clindermatol.2019.05.002.
- Meira, T. M., Prestes, J., Gasparello, G. G., Antelo, O. M., Pithon, M. M., & Tanaka, O. M. (2021). The effects of images posted to social media by orthodontists on public perception of professional credibility and willingness to become a client. *Prog Orthod*, 22(1), 7. 10.1186/s40510-021-00353-9.
- Mertens, I., Siegmund, H., & Grusser, O. J. (1993). Gaze motor asymmetries in the perception of faces during a memory task. *Neuropsychologia*, 31(9), 989-998. 10.1016/0028-3932(93)90154-r.
- Naeyaert, J., & Brochez, L. (2003). CPDN. *N Engl J Med*, 349(23), 2233-2240.
- Ozaki, M., Suga, H., Eto, H., Kobayashi, Y., Watanabe, R., Takushima, A., et al. (2014). Efficacy of serial excisions of melanocytic nevi on the face using a carbon dioxide laser: a cosmetic point of view. *Aesthetic Plast Surg*, 38(2), 316-321. 10.1007/s00266-014-0303-9.
- Penton-Voak, I. S., Jones, B. C., Little, A. C., Baker, S., Tiddeman, B., Burt, D. M., et al. (2001). Symmetry, sexual dimorphism in facial proportions and male facial attractiveness. *Proc Biol Sci*, 268(1476), 1617-1623. 10.1098/rspb.2001.1703.
- Perrett, D. I., May, K. A., & Yoshikawa, S. (1994). Facial shape and judgements of female attractiveness. *Nature*, 368(6468), 239-242. <https://doi.org/10.1038/368239a0>
- Phillips, C., & Beal, K. N. (2009). Self-concept and the perception of facial appearance in children and adolescents seeking orthodontic treatment. *Angle Orthod*, 79(1), 12-16. 10.2319/071307-328.1
- Rezze, G. G., Leon, A., & Duprat, J. (2010). Dysplastic nevus (atypical nevus). *Anais Brasileiros de Dermatologia*, 85, 863-871.
- Richards, M. R., Fields, H. W., Jr., Beck, F. M., Firestone, A. R., Walther, D. B., Rosenstiel, S., et al. (2015). Contribution of malocclusion and female facial attractiveness to smile esthetics evaluated by eye tracking. *Am J Orthod Dentofacial Orthop*, 147(4), 472-482. 10.1016/j.ajodo.2014.12.016.
- Samson, N., Fink, B., & Matts, P. J. (2010). Visible skin condition and perception of human facial appearance. *Int J Cosmet Sci*, 32(3), 167-184. 10.1111/j.1468-2494.2009.00535.x
- Springer, I. N., Wannicke, B., Warnke, P. H., Zernial, O., Wiltfang, J., Russo, P. A., et al. (2007). Facial attractiveness: visual impact of symmetry increases significantly towards the midline. *Ann Plast Surg*, 59(2), 156-162. 10.1097/01.sap.0000252041.66540.ec
- Tanaka, O. M., Ribeiro, V. G., Gasparello, G. G., Reyes, A. A., Taffarel, I. A., & Vitral, R. W. F. (2022). Smile arc esthetics in middleaged man from the layperson's perspective via eye-tracking. *Pesqui Bras Odontopediatria Clín Integr*, 22, e210138. <https://doi.org/10.1590/pboci.2022.026>
- Valverde-Montalva, S. H., Flores-Mir, C., Rinchuse, D., & Arriola-Guillén, L. E. (2021). Influence of upper lip curvature on smile attractiveness in patients with different degrees of gingival smiles: A cross-sectional study with opinions from oral health providers and laypersons. *Am J Orthod Dentofacial Orthop*, 159(4), e321-e329. 10.1016/j.ajodo.2020.10.022,
- Wong, L., Ryan, F. S., Christensen, L. R., & Cunningham, S. J. (2018). Factors influencing satisfaction with the process of orthodontic treatment in adult patients. *Am J Orthod Dentofacial Orthop*, 153(3), 362-370. 10.1016/j.ajodo.2017.07.017.
- Yamamoto, M., Torii, K., Sato, M., Tanaka, J., & Tanaka, M. (2017). Analysis of gaze points for mouth images using an eye tracking system. *J Prosthodont Res*. 61(4):379-386. 10.1016/j.jpor.2016.12.005.