

## Comparative analysis of alveolar preservation using leukocyte-platelet rich fibrin during maxillary canine distalization: A retrospective study

Análise comparativa da preservação alveolar usando fibrina rica em leucócitos e plaquetas durante a distalização de caninos superiores: Um estudo retrospectivo

Análisis comparativo de la preservación alveolar utilizando fibrina rica en leucocitos y plaquetas en la extracción de dientes ortodóncicos: Un estudio retrospectivo

Received: 01/23/2024 | Revised: 01/31/2024 | Accepted: 02/01/2024 | Published: 02/04/2024

**Ariel Adriano Reyes Pacheco**

ORCID: <https://orcid.org/0000-0003-0699-8759>  
Pontificia Universidade Católica do Paraná, Brazil  
E-mail: [drarielreyes@gmail.com](mailto:drarielreyes@gmail.com)

**James Rudolph Collins**

ORCID: <https://orcid.org/0000-0001-7448-2784>  
Pontificia Universidad Católica Madre y Maestra, Dominican Republic  
E-mail: [jamesCollins@pucmm.edu.do](mailto:jamesCollins@pucmm.edu.do)

**Nelsida Contreras**

ORCID: <https://orcid.org/0009-0002-0861-7024>  
Pontificia Universidad Católica Madre y Maestra, Dominican Republic  
E-mail: [nelsidacontreras@gmail.com](mailto:nelsidacontreras@gmail.com)

**Astrid Lantigua**

ORCID: <https://orcid.org/0009-0005-7093-1809>  
Pontificia Universidad Católica Madre y Maestra, Dominican Republic  
E-mail: [astridlantiguav@gmail.com](mailto:astridlantiguav@gmail.com)

**Oscar Mario Antelo**

ORCID: <https://orcid.org/0000-0001-8944-5329>  
Universidad Católica Boliviana "San Pablo", Bolivia  
E-mail: [oarortodoncia@hotmail.com](mailto:oarortodoncia@hotmail.com)

**Gil Guilherme Gasparello**

ORCID: <https://orcid.org/0000-0002-8955-6448>  
Pontificia Universidade Católica do Paraná, Brazil  
E-mail: [gilguilhermeg@hotmail.com](mailto:gilguilhermeg@hotmail.com)

**Orlando Motohiro Tanaka**

ORCID: <https://orcid.org/0000-0002-1052-7872>  
Pontificia Universidade Católica do Paraná, Brazil  
E-mail: [tanakaom@gmail.com](mailto:tanakaom@gmail.com)

### Abstract

**Objective:** This study evaluated alveolar preservation using leukocyte-platelet rich fibrin (L-PRF) in adult patients, comparing it to control alveoli. **Methods:** Conducted from 2016 to 2018, the study included 17 adult patients, aged between 20 and 45 years, diagnosed with either Class I or Angle Class II-1 malocclusion. Participants underwent first premolar extractions, with L-PRF treatment applied to one side of their mouth, while the other side served as a control. This retrospective study compared tomography data from these patients, who also underwent maxillary canine retraction. One side of the mouth was treated as an experimental alveolus, preserved with L-PRF, and the other as a control. Data normality was assessed using the Shapiro-Wilk test. The Wilcoxon test was used for group comparisons, and the McNemar test was applied to fenestrations. **Results:** No statistically significant differences were observed in root length changes and surrounding bone tissue between the two sides ( $P > 0.05$ ). **Conclusion:** The study found no significant differences in root length reduction and changes in supporting bone tissue between the experimental and control sides. This suggests that alveolar preservation with L-PRF does not alleviate the deleterious effects observed during maxillary canine distalization.

**Keywords:** Cuspid; Tooth movement techniques; Platelet rich fibrin; Root resorption; Orthodontics.

### Resumo

**Objetivo:** Este estudo avaliou a preservação alveolar utilizando fibrina rica em leucócitos e plaquetas (L-PRF) em pacientes adultos, comparando-a com alvéolos controle. **Métodos:** Realizado de 2016 a 2018, o estudo incluiu 17 pacientes adultos, com idades entre 20 e 45 anos, diagnosticados com maloclusão Classe I ou Classe II-1 de Angle. Os participantes foram submetidos à extração do primeiro pré-molar, com tratamento L-PRF aplicado em um lado da boca, enquanto o outro lado serviu como controle. Este estudo retrospectivo comparou dados tomográficos desses pacientes,

que também passaram por retração de caninos maxilares. Um lado da boca foi tratado como um alvéolo experimental, preservado com L-PRF, e o outro como controle. A normalidade dos dados foi avaliada usando o teste de Shapiro-Wilk. O teste de Wilcoxon foi usado para comparações entre grupos, e o teste de McNemar foi aplicado a fenestrões. Resultados: Não foram observadas diferenças estatisticamente significativas nas alterações do comprimento radicular e tecido ósseo circundante entre os dois lados ( $P > 0,05$ ). Conclusão: O estudo não encontrou diferenças significativas na redução do comprimento radicular e nas mudanças no tecido ósseo de suporte entre os lados experimental e controle. Isso sugere que a preservação alveolar com L-PRF não alivia os efeitos deletérios observados durante a distalização do canino maxilar.

**Palavras-chave:** Dente canino; Técnicas de movimentação dentária; Fibrina rica em plaquetas; Reabsorção da raiz; Ortodontia.

### Resumen

Objetivo: Este estudio evaluó la preservación alveolar utilizando fibrina rica en leucocitos y plaquetas (L-PRF) en pacientes adultos, comparándola con alvéolos de control. Métodos: Realizado de 2016 a 2018, el estudio incluyó a 17 pacientes adultos, de entre 20 y 45 años, diagnosticados con maloclusión de Clase I o Clase II-1 de Angle. Los participantes se sometieron a extracciones del primer premolar, con tratamiento de L-PRF aplicado en un lado de la boca, mientras que el otro lado sirvió como control. Este estudio retrospectivo comparó datos tomográficos de estos pacientes, que también se sometieron a retracción de caninos maxilares. Un lado de la boca fue tratado como un alvéolo experimental, preservado con L-PRF, y el otro como control. La normalidad de los datos se evaluó utilizando la prueba de Shapiro-Wilk. La prueba de Wilcoxon se utilizó para comparaciones entre grupos, y la prueba de McNemar se aplicó a las fenestraciones. Resultados: No se observaron diferencias estadísticamente significativas en los cambios de longitud de la raíz y el tejido óseo circundante entre ambos lados ( $P > 0,05$ ). Conclusión: El estudio no encontró diferencias significativas en la reducción de la longitud de la raíz y los cambios en el tejido óseo de soporte entre los lados experimental y control. Esto sugiere que la preservación alveolar con L-PRF no alivia los efectos deletéreos observados durante la distalización del canino maxilar.

**Palabras clave:** Diente canino; Técnicas de movimiento dental; Fibrina rica en plaquetas; Reabsorción radicular; Ortodoncia.

## 1. Introduction

External apical root resorption (EARR) affects 46% of orthodontic patients (I Castro, Valladares-Neto, & Estrela, 2015; Reitan, 1974). It involves root exposure during orthodontic movement, leading to irreversible damage. EARR has mechanical factors (force amount, direction, duration) and biological factors (genetic predisposition, age, root shape, retained teeth, gender). (Al-Qawasmi et al., 2003; Reitan, 1957; Sameshima & Sinclair, 2001a). Extraction of premolars prolongs treatment especially in adults and increases EARR risk, as it requires closing the extraction spaces and ensuring correct root alignment (Fisher et al., 2010; Mavreas & Athanasiou, 2008; Sameshima & Sinclair, 2001b).

Dehiscences occur when there is a loss of the bone cortex on the vestibular or lingual surface, leading to root exposure and marginal bone loss. In contrast, fenestrations involve the presence of marginal bone tissue with root exposure. (Evangelista et al., 2010) Teeth affected by these defects are more prone to relapse and may exhibit an unaesthetic appearance due to gingival recession resulting from inadequate bone tissue support (Wennström, 1996). The use of leukocyte-platelet rich fibrin membrane in treating gingival recessions has been observed to have beneficial effects (Munhoz et al., 2022).

Cone-beam computed tomography (CBCT) is particularly effective in diagnosing EARR (I Castro et al., 2015; Yi et al., 2017) and can also detect the presence of dehiscences and fenestrations before or during orthodontic treatment (Castro et al., 2016; Evangelista et al., 2010).

Leukocyte-platelet rich fibrin (L-PRF) is a second-generation biomaterial based on blood plasma. L-PRF consists of blood without the addition of any other components. The most significant advantages of L-PRF are the ease and low cost of producing the plasma membrane through centrifugation (Dohan et al., 2006a). It contains bioactive components, including proteases, antiproteases, cytokines, chemokines, and growth factors, which collectively contribute to angiogenesis, bone formation, cell proliferation, wound healing, and bone repair (Dohan et al., 2006b, 2006c).

Although the use of blood derivatives, such as platelet-rich plasma (PRP), injectable PRP (i-PRP), and L-PRF, to accelerate orthodontic movement has been explored, the evidence from human studies remains limited and inconclusive (El-

Timamy et al., 2020; Pacheco et al., 2020; Zeitounlouian et al., 2021). Studies evaluating the effects of these blood derivatives on orthodontic movement, root length, and adjacent bone have yielded controversial findings, making it necessary to further investigate the potential benefits they may offer to patients during treatment.

Therefore, the objective of this study was to compare changes in root length and surrounding bone tissue during distalization in alveoli preserved with L-PRF versus control alveoli in adult patients. The null hypothesis (H<sub>0</sub>) assumes no significant difference between the two groups.

## 2. Methodology

The retrospective study was performed using samples from a randomized controlled clinical trial of a split-mouth design that assessed the rate of maxillary canine distalization in adult patients (Pacheco et al., 2020). Patients with Angle Class I and II malocclusion were treated with the extraction of their first premolars, followed by alveolar preservation using L-PRF on the experimental side. The other side served as the control, with only a blood clot present. The randomization sequence of the sides was generated using an Excel spreadsheet that used the random number generation function.

The study was conducted at the (name was omitted). This study was approved by the bioethics committee (ID: COBE-FACS-M.EST-CSTA-004-2-2015-2016) and was performed between 2016 and 2018. All patients signed an informed consent form before the study commenced.

The study included a sample of 17 adult patients (12 females and five males) aged between 20 and 45 years (mean age  $33 \pm 5.9$  years). The patients were diagnosed with either Class I malocclusion (n=14) or Angle Class II-1 malocclusion (n=3). All the patients required orthodontic treatment involving extractions of their maxillary first premolars.

The patients received treatment with pre-adjusted MBT prescription brackets with a 0.022" inch (ABZIL Kirium, 3M, Brazil). The archwire sequence used was nickel-titanium (NiTi) 0.014", 0.016", and stainless steel 0.018", 0.020", and 0.019 x 0.025". Maxillary canine distalization was initiated 15 days after the extraction of the first premolars and the placement of the L-PRF membrane on the experimental side. To achieve the distalization of canines, a force of 150 g/f was applied using chain elastics from the second premolar to the canine, as described previously (Burrow, 2010; Mezomo et al., 2011). The first molar and second premolar were tied with a 0.008" metal ligature wire as an anchorage unit, while the canines were tied to the distal wing of its brackets. Activations were performed once a month for a total of 5 months, with force measurements taken using the Correx tensiometer (50-250 g; Haag Streit, Bern, Switzerland).

To obtain L-PRF, the collected blood was centrifuged in an IntraSpin device (Boca Raton, FL, USA) for 12 min at 2,700 RPM, in accordance with the manufacturer's specifications. The experimental socket was preserved with the L-PRF membrane. The edges of the socket were brought together and sutured with Nylon 4-0 (Mononylon-Ethicon, Johnson & Johnson, New Brunswick, NJ, USA) to promote healing.

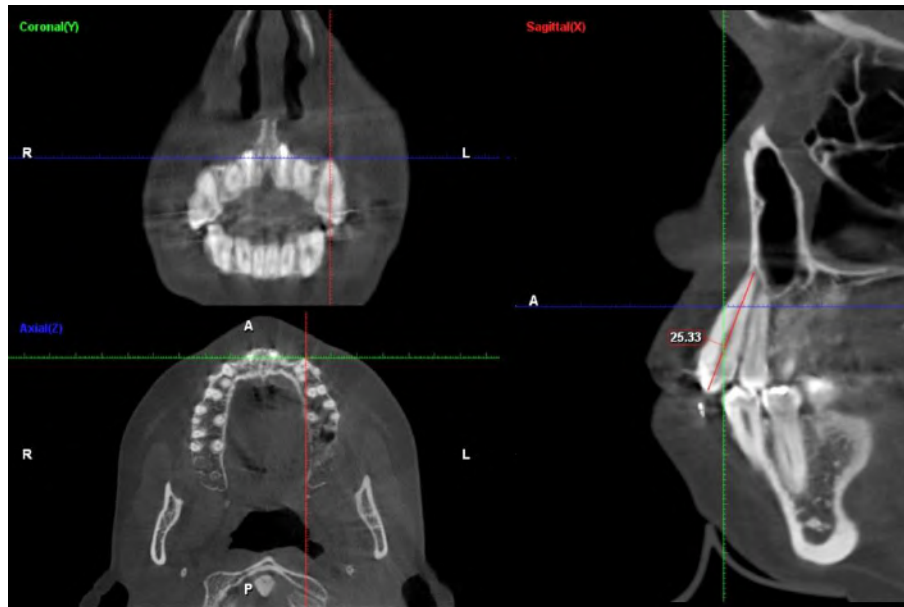
CBCT scans were taken prior to the extraction of the first premolars, after the alignment and leveling phase was completed (T<sub>1</sub>), and again 5 months later (T<sub>2</sub>). The scans were performed using the Plan Meca ProMax 3D Max machine, with a field of view measuring  $\varnothing 23 \times 26$  cm, exposure time of 18-30 s, voxel size of 0.200, reconstruction time of 30-150 s, and radiation dose ranging between 101-252 mSv.

### Root length

To evaluate the possible presence of root resorption, the maximum linear root length of the pre- and post-distalized canines was measured. A line was traced on the long axis of each tooth from the apex to the cusp. The teeth were located using axial navigation guidance from the multi-planar reconstruction (axial, sagittal, and coronal) of the CBCT (Castro et al., 2013; Castro et al., 2015). The distances between reference points were measured (mm) using Romexis Viewer 3.8.2 software

(Planmeca, Helsinki, Finland) (Figure 1). The difference in root length between T1-T2 represented the amount of root resorption that occurred during distalization.

**Figure 1** - Multiplanar reconstruction was used to mark Cusp-apex reference points to measure maximum linear root length (pre & post distalization) of maxillary canines on both sides to assess the possible root resorption.

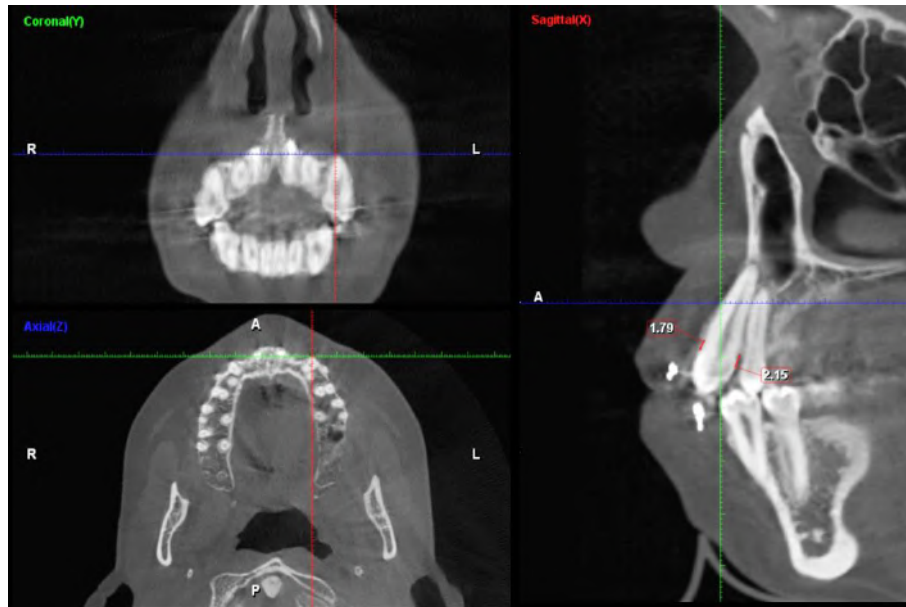


Source: Research data

### Dehiscences and fenestrations

The assessment of alveolar bone dehiscences was carried out as previously described. The long axis of the tooth was located through guided axial navigation with multi-planar reconstruction. Subsequently, a line was drawn from the apex of the tooth to the cusp, which served as a reference point for measuring the vestibular and palatal distances from the cemento-enamel junction to the bone crest in the sagittal section (Figure 2). Distances  $\leq 2$  mm were considered normal, while distances  $> 2$  mm were considered alveolar bone dehiscences. (Castro et al., 2016).

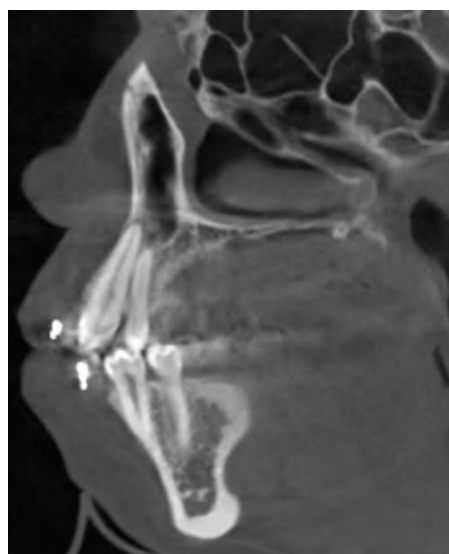
**Figure 2** - Multiplanar reconstruction for assessment of bone dehiscence on the buccal and palatal sides of the maxillary right canine in the sagittal plane. Distances greater than 2mm were considered has dehiscences.



Source: Research data.

The frequencies of fenestrations were recorded using tomography scans, following the criteria established by Evangelista et al. (Evangelista et al., 2010) for classifying bone surface defects. Both axial and sagittal planes were used to capture the images. Images that showed the absence of cortical bone on the root surface, while maintaining cervical bone in at least three consecutive image sections, were identified as fenestrations (Figure 3).

**Figure 3** - Evaluation of the continuity of the buccal and palatal cortical bone of the maxillary canine searching for bone fenestrations using the sagittal plane.



Source: Research data.

### Statistical analyses

In the assessment of root length, the intra-class correlation coefficient (ICC) was calculated to verify the reliability of the measurements taken by the operator. High reliability and homogeneity of the measurements was evident (experimental side

= 0.87 / control side = 0.81). The Shapiro–Wilk test was applied to evaluate the distribution of the data, which showed a non-normal distribution. Subsequently, the Wilcoxon signed rank test was performed to compare the differences in root length between the canines.

Regarding dehiscences, the reliability of the measurements was assessed by calculating the ICC, which yielded a value of 0.88 for the control side and 0.72 for the experimental side. The Shapiro–Wilk test indicated that the sample had a non-normal distribution. Therefore, the non-parametric Wilcoxon signed rank test was used to compare the two groups. The frequency of fenestrations between the groups was compared using the McNemar test.

All statistical analyses were conducted using IBM® SPSS® Statistics software (Release 21.0.0; SPSS Inc., Chicago, IL, USA) with a significance level of 0.05.

### 3. Results

#### Root length

The sample comprised 34 maxillary canines (17 from the control group and 17 from the experimental group), collected from 17 patients. The average reduction in root length of the distalized canines was similar in both groups (experimental group = 1.32 mm, control group = 1.41 mm;  $P > 0.05$ ), with a difference of 0.09 mm between the groups. The control group demonstrated a normal distribution of the data (0.385) and had a minimum reduction in root length of 0.62 mm and a maximum reduction of 2.72 mm.

In the experimental group, the distribution of data was non-normal (0.003), with a minimum reduction in the length of the root of 0.45 mm and a maximum reduction of 3.36 mm. The values for both groups are provided in Table 1.

**Table 1** - Comparison of root length before (T1) and after (T2) distalization of maxillary canines.

Side	n	Minimum	Maximum	Mean	Wilcoxon signed rank Test (P-value)
Control	17	0.62	2.72	1.41	0.687
Experimental	17	0.45	3.36	1.32	

p =significance level of 0.05. Source: Research data.

After 5 months of distalization, no statistically significant difference ( $P = 0.687$ ) was observed between the experimental and control sides. Thus, the null hypothesis of no difference in canine root length between the two groups was maintained.

#### Dehiscences

Sixty-eight root surfaces were evaluated and compared at T1 and T2. An increase in the distance from the cemento-enamel junction to the alveolar crest was observed in 27 surfaces (39.70%) at T1 and 32 (47.05%) at T2.

On the control side, the values of the cemento-enamel junction to the marginal alveolar crest exceeded 2 mm (dehiscences present) in 11 of 34 root surfaces at T1, and 16 of 34 root surfaces on the experimental side. The frequency of dehiscences increased at T2 on both sides (Table 2).

**Table 2** - Absolute frequency and percentage of distances >2 mm from the cemento-enamel junction to the bone crest on buccal and palatal surfaces of distalized maxillary canines.

Side	T1 (n=17)	T1 (n=17)	T2 (n=17)	T2 (n=17)
	<i>f(a)</i>	<i>fr%</i>	<i>f(a)</i>	<i>fr%</i>
<b>Control</b>				
Buccal	5	7.35	7	10.29
Palatal	6	8.82	7	10.29
<b>Experimental</b>				
Buccal	7	10.29	8	11.64
Palatal	9	13.23	10	14.70
Total	27	39.7	32	47

Source: Research data.

On the control side, there was a non-normal distribution on the buccal surface (0.01) and a normal distribution on the palatal surface (0.159). On the experimental side, the distribution was non-normal on both root surfaces.

On the control side, the values of the distance from the cemento-enamel junction to the bone crest increased by 0.41 mm on the buccal surface and 0.42 mm on the palatal surface. On the experimental side, the values of the distance from the cemento-enamel junction to the bone crest increased by 0.02 mm on the buccal surface and 0.29 mm on the palatal surface.

The descriptive statistics of the sample are presented in Table 3. Positive values indicate a decrease in the distance from the cemento-enamel junction to the bony crest. Negative values indicate an increase in the distance. No statistically significant differences were evident between the groups on the buccal surface ( $P=0.365$ ) and palatal surface ( $P=0.733$ ). Thus, the null hypothesis of no difference between the sides was maintained.

### Fenestrations

Thirty-four root surfaces were evaluated for lack of continuity in the cortical bone on both the buccal and palatal sides in T1 and T2. Fenestrations were observed in five surfaces (14.70%) in T1 and in eight surfaces (23.52%) in T2. All were located on the buccal surface. No statistically significant differences were observed between the sides ( $P = 0.35$ ), supporting the null hypothesis that there is no difference in the frequency of fenestrations.

On the control side, the lack of bone continuity was observed in two surfaces in T1 and in six surfaces in T2. All were found in the middle and apical thirds of the roots. On the experimental side, the continuity was not observed in three surfaces in T1, and two surfaces remained in T2, with the third surface showing evidence of bone repair.

**Table 3** – Values of the distance from the cemento-enamel junction to the bone crest on the buccal and palatal surfaces of distalized maxillary canines.

	Buccal					Palatal					
	N	Mean Dif. T1-T2	Max.	Min.	Stand. D.	Wilcoxon Signed Rank Test (P-value)	Mean Dif. T1-T2	Max.	Min.	Stand. D.	Wilcoxon Signed Rank Test (P-value)
Control	17	-0.41	0.53	-2.72	0.90	0.365	-0.42	1.08	-2.33	0.90	0.733
Experimental	17	-0.06	2.07	-1.72	0.75		-0.29	1.50	3.06	0.99	

Note: Values are presented in millimeters. Min, minimum; Max, maximum; Stand. D, standard deviation. Negative values indicate the increase in millimeters from T1 to T2. P =significance level of 0.05. Source: Research data.

#### 4. Discussion

In orthodontics, studies of the use of blood derivatives and their relationships to tooth movement have become a recent focus of research. The results have been conflicting (Liu et al., 2021; Pacheco et al., 2020; Tehranchi et al., 2018; Zeitounlouian et al., 2021). Little is known about the effects of the placement of these biomaterials on root length of the moved tooth and on the surrounding supporting bone tissue during orthodontic movement. This study aimed to evaluate and compare these effects after distalization of maxillary canines in alveoli preserved with L-PRF and control alveoli in adult patients using CBCT. To the best of our knowledge, this is the second study to evaluate these variables with blood derivatives and the first to use L-PRF. The first study was performed with i-PRF applied monthly for 3 months (Zeitounlouian et al., 2021).

Both PRP and L-PRF derivatives are used to support the regeneration of bone defects. However, L-PRF has a higher concentration of platelets and leukocytes, which are retained within a fibrin mesh created by blood centrifugation, allowing for a more gradual and sustained release of growth factors compared to PRP (Dohan Ehrenfest et al., 2012). This study focused on L-PRF, which is a second-generation blood derivative that accelerates angiogenesis, chemotaxis, mitosis, and cell proliferation. These phenomena could be beneficial during orthodontic treatment for adult patients, as the prevalence of bone defects tends to increase with age, and since orthodontic treatment can potentially increase the risk of apical root resorption and loss of bone crest height.(Harris & Baker, 1990) All patients in this study were adults who underwent extraction of maxillary first premolars, which is a procedure that tends to increase the treatment time. Longer treatment duration is associated with an increased risk of EARR (Deng et al., 2018; Sameshima & Sinclair, 2001b). The regenerative potential of L-PRF motivated this research.

CBCT is a useful tool for evaluating changes in root length of teeth and surrounding bone tissue.(I Castro et al., 2015; L. Castro et al., 2016; Evangelista et al., 2010) The voxel size of 0.2 mm was chosen for its optimal accuracy in measuring alveolar bone height with soft tissue present, as compared to the 0.4 mm voxel.(Wood et al., 2013) The use of a 0.4 mm voxel may lead to overestimation of bone dehiscences (Sun et al., 2011).

The use of tomography eliminates distortion and magnification of the obtained images, providing real anatomical measurements (1:1) in both vertical and horizontal dimensions. Therefore, the use of CBCT is preferred over two-dimensional images in clinical practice for these types of measurements (Alqerban et al.,2011).

During orthodontic treatment, a common side effect is the reduction of root length, often caused by orthodontically-induced inflammatory root resorption, which tends to be more severe in patients undergoing treatment (Weltman et al., 2010). Previous studies have shown that cytokines such as interleukin (IL)-1 $\beta$ , IL-6, and tumor necrosis factor-alpha released from L-PRF (Dohan et al., 2006c) which have therapeutic and anti-inflammatory properties, could potentially decrease this deleterious effect. However, in the present study, the experimental group did not experience a significant decrease in root length compared



to the control group, with a mean decrease of 1.32 mm and 1.41 mm, respectively. These findings are consistent with a previous study that evaluated the distalization of maxillary canines using i-PRF injected on the buccal and palatal surfaces, which found no significant difference between the experimental and control groups. Therefore, while cytokines released from L-PRF may have potential therapeutic benefits, they do not seem to have a significant effect on reducing orthodontically-induced inflammatory root resorption in the context of this study.

After tooth extraction, the alveolar ridge decreases in size in both width and height, with the most significant loss in width (Van der Weijden et al., 2009). Vertical bone loss is typically observed on the buccal surface. Orthodontic tooth movement can worsen pre-existing bone dehiscences and fenestrations (Wang, 2020). If teeth are moved through atrophic alveolar ridges, the incidence of these bone defects can be increased (Ramos et al., 2020).

In all patients included in this study, maxillary canine distalization was performed using 0.020" stainless steel wires, applying 150 g of force with the use of an elastic chain, which is an option along with nickel-titanium springs, producing similar effects on distalization, rotation, and angulation rate (Barsoum et al., 2021). Vertical bone and thickness loss during the retraction of anterior teeth is common and is due to the concentration of orthodontic forces in the cervical region (Guo et al., 2021) which represents 60% of the tooth's periodontal support (Consolaro, 2019). In adult orthodontic patients, there is an increase in the distance from the cement-enamel junction to the marginal bone crest compared to adolescents, resulting in decreased bone support (Harris & Baker, 1990). In these patients, the alveolar bone becomes denser, and the periodontal ligament becomes more acellular and fibrotic, leading to the release of inflammatory markers such as cytokines and osteoclasts, which are maintained continuously and for longer periods in adults than in adolescents. The inflammatory process is more prolonged in adults, which may explain the occurrence of these deleterious effects in our patients.

The maxillary canines are one of the teeth with the highest risk of vertical bone loss on the buccal surface during orthodontic treatment with fixed appliances (Castro et al., 2016; Jäger et al., 2017). However, in cases where first premolars are extracted, the bone height significantly increases on the buccal surface (Guo et al., 2021). In the present study, the frequency of dehiscence in patients was similar on both sides, indicating that the regenerative properties of L-PRF did not limit the vertical reduction of alveolar bone. The frequency of pre-distalization dehiscences exceeded 10%, which agrees with the value of 11% in a previous study (Castro et al., 2016). While this value may seem high for the number of patients in this study, it can be attributed to the sample size, previous orthodontic treatment during the alignment and leveling phases, dental extractions, and because all patients were adults.

The incidence of fenestrations in this study (14.6%) differs from the 36.51% reported by Evangelista et al.<sup>16</sup> in adult patients with untreated Angle Class I and II malocclusion. The frequency of fenestrations increased at T2 due to orthodontic treatment, likely because of using 0.020" stainless steel wire, which may have led to a lack of three-dimensional control and subsequently the increased exposure of the root in its middle to apical third.

From a statistical standpoint, our null hypothesis of no difference between the control and experimental sides was maintained. However, from a clinical perspective and based on the results of this study, the use of L-PRF to prevent a decrease in root length and the occurrence of bone defects (dehiscences and fenestrations) for alveolar preservation may not be justified.

### **Limitations**

To expand the sample size in future research is advisable.

### **5. Conclusions**

The null hypothesis was maintained. Over a five-month period, maxillary canine distalization in alveoli preserved with L-PRF demonstrated comparable outcomes in both root length and adjacent bone tissue as those observed in untreated alveoli.

Further investigations could include larger sample sizes, diverse patient demographics, and longer follow-up periods to assess the long-term efficacy. Explore the molecular and cellular responses of alveolar bone to various preservation materials could also yield valuable information for developing more effective clinical protocols for dental and orthodontic treatments.

## References

- Al-Qawasmi, R., Hartsfield Jr, J., Everett, E., Flury, L., Liu, L., Foroud, T., & Roberts, W. (2003) Genetic predisposition to external apical root resorption. *Am J Orthod Dentofacial Orthop*, 123(3), 242-252. 10.1067/mod.2003.42
- Alqerban, A., Jacobs, R., Fieuws, S., & Willems, G. (2011). Comparison of two cone beam computed tomographic systems versus panoramic imaging for localization of impacted maxillary canines and detection of root resorption. *Eur J Orthod*, 33(1), 93-102. 10.1093/ejo/cjq034
- Barsoum, H., ElSayed, H., El Sharaby, F., Palomo, J., & Mostafa, Y. (2021). Comprehensive comparison of canine retraction using NiTi closed coil springs vs elastomeric chains. *Angle Orthod*, 91(4), 441-448. 10.2319/110620-916.1
- Burrow, S. (2010). Canine retraction rate with self-ligating brackets vs conventional edgewise brackets. *Angle Orthod*, 80(4), 626–633. 10.2319/060809-322.1
- Castro, I., Alencar, A., Valladares-Neto, J., & Estrela, C. (2013). Apical root resorption due to orthodontic treatment detected by cone beam computed tomography. *Angle Orthod.*, 83(2), 196–203. 10.2319/032112-240.1
- Castro, I., Valladares-Neto, J., & Estrela, C. (2015). Contribution of cone beam computed tomography to the detection of apical root resorption after orthodontic treatment in root-filled and vital teeth. *Angle Orthod.*, 85(5), 771–776. 10.2319/042814-308.1
- Castro, L., Castro, I., de Alencar, A., Valladares-Neto, J., & Estrela, C. (2016). Cone beam computed tomography evaluation of distance from cemento-enamel junction to alveolar crest before and after nonextraction orthodontic treatment. *Angle Orthod*, 86(4), 543–549. 10.2319/040815-235.1
- Consolaro, A. (2019). Extreme root resorption in orthodontic practice: teeth do not have to be replaced with implants. *Dental Press J Orthod*, 24(5), 20-28. 10.1590/2177-6709.24.5.020-028.oim
- Deng, Y., Sun, Y., & Xu, T. (2018). Evaluation of root resorption after comprehensive orthodontic treatment using cone beam computed tomography (CBCT): a meta-analysis. *BMC Oral Health*, 18(1), 1-14. 10.1186/s12903-018-0579-2
- Dohan, D., Choukroun, J., Diss, A., Dohan, S., Dohan, A., Mouhyi, J., & Gogly, B. (2006a). Platelet-rich fibrin (PRF): A second-generation platelet concentrate. Part I: Technological concepts and evolution. *Oral Surg Oral Med Oral Pathol Oral Radiol Endod*, 101(3), E37-44. 10.1016/j.tripleo.2005.07.008
- Dohan, D., Choukroun, J., Diss, A., Dohan, S., Dohan, A., Mouhyi, J., & Gogly, B. (2006b). Platelet-rich fibrin (PRF): A second-generation platelet concentrate. Part II: Platelet-related biologic features. *Oral Surg Oral Med Oral Pathol Oral Radiol Endod*, 101(3), E45-50. 10.1016/j.tripleo.2005.07.009
- Dohan, D., Choukroun, J., Diss, A., Dohan, S., Dohan, A., Mouhyi, J., & Gogly, B. (2006c). Platelet-rich fibrin (PRF): A second-generation platelet concentrate. Part III: Leucocyte activation: A new feature for platelet concentrates? *Oral Surg Oral Med Oral Pathol Oral Radiol Endod*, 101(3), E51-55. 10.1016/j.tripleo.2005.07.010
- Dohan Ehrenfest, D., Bielecki, T., Jimbo, R., Barbé, G., Del Corso, M., Inchingolo, F., & Sammartino, G. (2012). Do the fibrin architecture and leukocyte content influence the growth factor release of platelet concentrates? An evidence-based answer comparing a pure platelet-rich plasma (P-PRP) gel and a leukocyte- and platelet-rich fibrin (L-PRF). *Curr Pharm Biotechnol*, 13(7), 1145-1152. 10.2174/138920112800624382
- El-Timamy, A., El Sharaby, F., Eid, F., El Dakrouy, A., Mostafa, Y., & Shakere, O. (2020). Effect of platelet-rich plasma on the rate of orthodontic tooth movement: A split-mouth randomized trial. *Angle Orthod*, 90(3), 354–361. 10.2319/072119-483.1
- Evangelista, K., Faria Vasconcelos, K., Bumann, A., Hirsch, E., Nitka, M., & Silva, M. (2010). Dehiscence and fenestration in patients with Class I and Class II Division 1 malocclusion assessed with cone-beam computed tomography. *Am J Orthod Dentofacial Orthop* ;138:, 138(2), 133.e131-133.e137. 10.1016/j.ajodo.2010.02.021
- Fisher, M., Wenger, R., & Hans, M. (2010). Pretreatment characteristics associated with orthodontic treatment duration. *Am J Orthod Dentofacial Orthop*, 137(2), 178-186. 10.1016/j.ajodo.2008.09.028
- Guo, R., Zhang, L., Hu, M., Huang, Y., & Li, W. (2021). Alveolar bone changes in maxillary and mandibular anterior teeth during orthodontic treatment: A systematic review and meta-analysis. *Orthod Craniofac Res*, 24(2), 165-179. 10.1111/ocr.12421
- Harris, E., & Baker, W. (1990). Loss of root length and crestal bone height before and during treatment in adolescent and adult orthodontic patients. *Am J Orthod Dentofacial Orthop*. 98(5), 463-469. 10.1016/s0889-5406(05)81656-7
- Jäger, F., Mah, J., & Bumann, A. (2017). Peridental bone changes after orthodontic tooth movement with fixed appliances: A cone-beam computed tomographic study. *Angle Orthod*, 87(5), 672-680. 10.2319/102716-774.1
- Liu, L., Kuang, Q., Zhou, J., & Long, H. (2021). Is platelet-rich plasma able to accelerate orthodontic tooth movement? *Evid Based Dent*, 22(1), 36-37. 10.1038/s41432-021-0160-8
- Mavreas, D., & Athanasiou, A. (2008). Factors affecting the duration of orthodontic treatment: a systematic review. *Eur J Orthod*, 30, 386–395. 10.1093/ejo/cjn018
- Mezomo, M., de Lima, E., de Menezes, L., Weissheimer, A., & Allgayer, S. (2011). Maxillary canine retraction with self-ligating and conventional brackets- A randomized clinical trial. *Angle Orthod*, 81(2), 292–297. 10.2319/062510-348.1

- Munhoz, G. C., Oliveira, R. dos S., Decósimo, A. L., Ito, F. A. N., Costa, P. P., Pedriali, M. B. B. P. (2022) Use of leukocyte-platelet rich fibrin membrane in the treatment of gingival recession: a case report. *Research, Society and Development*, 11(8), e29811830779. 10.33448/rsd-v11i8.30779. Disponível em: <https://rsdjournal.org/index.php/rsd/article/view/30779>.
- Pacheco, A., Collins, J., Contreras, N., Lantigua, A., Python, M., & Tanaka, O. (2020). Distalization rate of maxillary canines in an alveolus filled with leukocyte-platelet-rich fibrin in adults: A randomized controlled clinical split-mouth trial. *Am J Orthod Dentofacial Orthop*, 158(2), 182-191. 10.1016/j.ajodo.2020.03.020
- Ramos, A., Dos Santos, M., de Almeida, M., & Mir, C. (2020). Bone dehiscence formation during orthodontic tooth movement through atrophic alveolar ridges. *Angle Orthod*, 90(3), 321-329. 10.2319/063019-443.1
- Reitan, K. (1957). Some factors determining the evaluation of forces in orthodontics. *Am. J. Orthod*, 43(1), 32-45. 10.1016/0002-9416(57)90114-8
- Reitan, K. (1974). Initial Tissue Behavior During Apical Root Resorption. *Angle Orthod*, 44(1), 68-82. 10.1043/0003-3219(1974)044<0068:ITBDAR>2.0.CO;2
- Sameshima, G., & Sinclair, P. (2001a). Predicting and preventing root resorption: Part I. Diagnostic factors. *Am J Orthod Dentofacial Orthop*, 119(5), 505-510. 10.1067/mod.2001.113409
- Sameshima, G., & Sinclair, P. (2001b). Predicting and preventing root resorption: Part II. Treatment factors. *Am J Orthod Dentofacial Orthop*, 119(5), 511-515. 10.1067/mod.2001.113410
- Skidmore, K., Brook, K., Thomson, W., & Harding, W. (2006). Factors influencing treatment time in orthodontic patients. *Am J Orthod Dentofacial Orthop* 129(2), 230-238. 10.1016/j.ajodo.2005.10.003
- Sun, Z., Smith, T., Kortam, S., Kim, D., Tee, B., & Fields, H. (2011). Effect of bone thickness on alveolar bone-height measurements from cone-beam computed tomography images. *Am J Orthod Dentofacial Orthop*, 139(2), e117-127. 10.1016/j.ajodo.2010.08.016
- Tang, Z., Liu, X., & Chen, K. (2017). Comparison of digital panoramic radiography versus cone beam computerized tomography for measuring alveolar bone. *Head Face Med*, 13(1), 1-7. 10.1186/s13005-017-0135-3
- Tehranchi, A., Behnia, H., Pourdanesh, F., Behnia, P., Pinto, N., & Younessian, F. (2018). The effect of autologous leukocyte platelet rich fibrin on the rate of orthodontic tooth movement: A prospective randomized clinical trial. *Eur J Dent*, 12(3), 350-357. 10.4103/ejd.ejd\_424\_17
- Van der Weijden, F., Dell'Acqua, F., & Slot, D. (2009). Alveolar bone dimensional changes of post-extraction sockets in humans: a systematic review. *J Clin Periodontol*, 36(12), 1048-1058. 10.1111/j.1600-051X.2009.01482.x
- Vig, P., Weintraub, J., Brown, C., & Kowalski, C. (1990). The duration of orthodontic treatment with and without extractions: A pilot study of five selected practices. *Am J Orthod Dentofacial Orthop*, 97(1), 45-51. 10.1016/S0889-5406(05)81708-1
- Wang CW, Y. S., Mandelaris GA, Wang HL. (2020). Is periodontal phenotype modification therapy beneficial for patients receiving orthodontic treatment? An American Academy of Periodontology best evidence review. *J Periodontol*, 91(3), 299-310. 10.1002/JPER.19-0037
- Weltman, B., Vig, K., Fields, H., Shanker, S., & Kaizar, E. (2010). Root resorption associated with orthodontic tooth movement: a systematic review. *Am J Orthod Dentofacial Orthop*, 137(4). 10.1016/j.ajodo.2009.06.021
- Wennström, J. (1996). Mucogingival Considerations in Orthodontic Treatment. *Semin Orthod*, 2(1), 46-54. 10.1016/s1073-8746(96)80039-9
- Wood, R., Sun, Z., Chaudhry, J., Tee, B., Kim, D., Leblebicioglu, B., & England, G. (2013). Factors affecting the accuracy of buccal alveolar bone height measurements from cone-beam computed tomography images. *Am J Orthod Dentofacial Orthop*, 143(3), 353-363. 10.1016/j.ajodo.2012.10.019
- Yi, J., Sun, Y., Li, Y., Li, C., Li, X., & Zhao, Z. (2017). Cone-beam computed tomography versus periapical radiograph for diagnosing external root resorption: A systematic review and meta-analysis. *Angle Orthod*, 87(2), 328-337. 10.2319/061916-481.1
- Zeitounlouian, T., Zeno, K., Brad, B., & Haddad, R. (2021). Three dimensional evaluation of the effects of injectable platelet rich fibrin (i-PRF) on alveolar bone and root length during orthodontic treatment: a randomized split mouth trial. *BMC Oral Health* 21, 92. 10.1186/s12903-021-01456-9