

Clinical manifestations and management of *Tityus* species envenoming: A systematic review

Manifestações clínicas e manejo do envenenamento por espécies do gênero *Tityus*: Uma revisão sistemática

Manifestaciones clínicas y manejo del envenenamiento por especies de *Tityus*: Una revisión sistemática

Received: 02/21/2024 | Revised: 02/27/2024 | Accepted: 02/28/2024 | Published: 03/01/2024

Ione Maria de Matos

ORCID: <https://orcid.org/0000-0002-1904-5001>
Universidade Federal de Juiz de Fora, Brazil
E-mail: ione.matos@ufjf.br

Filipe Ferreira Santos

ORCID: <https://orcid.org/0009-0001-6430-2919>
Universidade Federal de Juiz de Fora, Brazil
E-mail: 13754385658@estudante.ufjf.br

Fernanda Lima Marçal

ORCID: <https://orcid.org/0000-0003-0257-6460>
Universidade Federal de Juiz de Fora, Brazil
E-mail: fernandalm2@hotmail.com

Letícia Duarte Silva

ORCID: <https://orcid.org/0000-0001-9511-039X>
Universidade Federal de Juiz de Fora, Brazil
E-mail: leticiauarte00@hotmail.com

Maisa Silva

ORCID: <https://orcid.org/0000-0003-3996-159X>
Universidade Federal de Juiz de Fora, Brazil
E-mail: maisa.silva@ufjf.br

Abstract

Scorpionism, or a clinical picture of envenomation caused by a scorpion sting, is a public health problem in South America. The manifestations clinical and management are varied and complex and there is still no consensus in the literature on these aspects. The aim of this systematic review is to describe the clinical manifestations, as well as treatment after scorpion envenomation by *Tityus* species. The online databases of PubMed, Scopus, Web of Science, and SciELO were systematically searched for relevant publications until march 2022. No language and age restrictions were imposed. The literature search generated 476 references and 23 studies were included in the systematic review, according to the inclusion criteria of this review. The number of participants studied was 7,781. The specie *Tityus serrulatus* was found in more studies. The time elapsed between the accident and medical care ranged from 15 minutes to more than 6 hours. The treatments performed in selected studies include scorpion antivenoms, corticosteroids, anesthetics, antiemetics agents, inotropics, antihypertensives and benzodiazepines drugs. In six studies, fatal cases were observed in five children aged 1 to 6-y and one in children < 14 y. We concluded that management of *Tityus* species envenoming is supportive and focused on the patient's symptoms. In severe cases, antivenoms, if available, are indicated. Medications to monitor vagal and adrenergic symptoms are encouraged. This study has the potential to help professionals who deal with envenomations caused by the genus *Tityus*.

Keywords: Clinical manifestations; Scorpions; Scorpion stings; Systematic review.

Resumo

Escorpionismo, ou quadro clínico de envenenamento causado por picada de escorpião, é um problema de saúde pública na América do Sul. As manifestações clínicas e de manejo são variadas e complexas e ainda não há consenso na literatura sobre esses aspectos. O objetivo desta revisão sistemática é descrever as manifestações clínicas, bem como o tratamento após envenenamento por escorpião pelo gênero *Tityus*. As bases de dados online PubMed, Scopus, Web of Science e SciELO foram sistematicamente pesquisadas em busca de publicações relevantes até março de 2022. Não foram impostas restrições de idioma e idade. A busca na literatura gerou 476 referências e 23 estudos foram incluídos na revisão sistemática, de acordo com os critérios de inclusão desta revisão. O número de participantes estudados foi 7.781. A espécie *Tityus serrulatus* foi encontrada na maioria dos estudos. O tempo decorrido entre o acidente e o atendimento médico variou de 15 minutos a mais de 6 horas. Os tratamentos realizados nos estudos selecionados

incluem soro antiescorpiônico, corticosteroides, anestésicos, antieméticos, agentes inotrópicos, anti-hipertensivos e benzodiazepínicos. Em seis estudos, foram observados casos fatais em cinco crianças de 1 a 6 anos e um, em crianças < 14 anos. Concluímos que o manejo do envenenamento pelo gênero *Tityus* é de suporte e focado nos sintomas do paciente. Em casos graves, são indicados antivenenos, se disponíveis. Medicamentos para monitorar sintomas vagais e adrenérgicos são incentivados. Este estudo tem potencial para auxiliar profissionais que lidam com envenenamentos causados pelo gênero *Tityus*.

Palavras-chave: Manifestações clínicas; Escorpiões; Picadas de escorpião; Revisão sistemática.

Resumen

El escorpionismo, o cuadro clínico de intoxicación por picadura de alacrán, es un problema de salud pública en América del Sur, las manifestaciones clínicas y el manejo son variados y complejos y aún no existe consenso en la literatura sobre estos aspectos. El objetivo de esta revisión sistemática es describir las manifestaciones clínicas así como el tratamiento posterior al envenenamiento por escorpiones del género *Tityus*. Se buscaron sistemáticamente publicaciones relevantes en las bases de datos en línea PubMed, Scopus, Web of Science y SciELO hasta marzo de 2022. No se impusieron restricciones de idioma ni edad. La búsqueda bibliográfica generó 476 referencias y 23 estudios fueron incluidos en la revisión sistemática, según los criterios de inclusión de esta revisión. El número de participantes estudiados fue 7.781. En la mayoría de los estudios se encontró la especie *Tityus serrulatus*. El tiempo transcurrido entre el accidente y la atención médica osciló entre 15 minutos y más de 6 horas. Los tratamientos realizados en los estudios seleccionados incluyen suero antiescorpión, corticoides, anestésicos, antieméticos, inotrópicos, antihipertensivos y benzodiazepinas. En seis estudios, se observaron casos mortales en cinco niños de 1 a 6 años y uno en niños < 14 años. Concluimos que el manejo del envenenamiento por *Tityus* es de apoyo y se centra en los síntomas del paciente. En casos graves, están indicados los antivenenos, si están disponibles. Se recomienda el uso de medicamentos para controlar los síntomas vagales y adrenérgicos. Este estudio tiene el potencial de ayudar a los profesionales que se ocupan de las intoxicaciones provocadas por el género *Tityus*.

Palabras clave: Manifestaciones clínicas; Escorpiones; Picaduras de escorpión; Revisión sistemática.

1. Introduction

Scorpions are among the oldest terrestrial animals on the planet. Their long evolutionary path has allowed a complex selection of toxins with very high affinity for the excitable cells of the human body (Casewell et al., 2013; Inceoglu et al., 2003; Zhang et al., 2016). Pathogenetic species of scorpions are opportunistic and generalists, showing high resistance to the rapid and profound environmental changes promoted by man, occupying with high efficiency several artificial microhabitats in rural, peri-urban and urban environments (Lourenço, 2008; Souza et al., 2012). The World Health Organization (WHO) recognizes scorpion stings as a global medical-sanitary problem in many tropical and subtropical countries (Chippaux & Goyffon, 2008). It is estimated that 1.2 million people are stung by scorpions annually (Boubekeur et al., 2020). According to the SINAN (Sistema de Informação de Agravos de Notificação) database from the Brazilian Ministry of Health, that reports scorpion accidents, the number of Brazilian scorpion stings has surpassed 120,000 cases in 2017.

Scorpionism, or a clinical picture of envenomation caused by a scorpion sting, is a public health problem in South America, where the most important cases are attributed to the genus *Tityus* (Oliveira et al., 2013). The clinical presentation of most scorpion stings ranges from mild local manifestations to systemic manifestations including severe cardiovascular and neuromuscular toxic effects (Isbister & Bawaskar, 2014). Systemic manifestations occur in about 5% of cases after a scorpion sting (Abroug et al., 1999). The severity of envenomation is related to cardiorespiratory dysfunction, with cardiogenic shock and pulmonary edema being the main causes of death.

In South America, the genus *Tityus*, with about 225 species, is responsible for severe scorpionism, having more medical importance because of the frequency of accidents that cause in adults and children and a significant potential of lethality when cardio-respiratory symptoms are present. Therefore, the clinical question we seek to address in this research is to establish the best therapeutic practice for treating scorpion envenoming and its outcomes. Thus, this systematic review aims to summarize clinical symptoms and therapeutic data after envenoming by *Tityus* species.

2. Methodology

The present systematic review was conducted according to the Preferred Reporting Items for Systematic reviews and Meta-Analyses (PRISMA) guidelines (Liberati et al., 2009) and the PRISMA 2020 check list (Page et al., 2021). The review has been registered at PROSPERO (www.crd.york.ac.uk/prospero/), registration number CRD42022353937.

Search strategy and selection criteria

We systematically PubMed, Scopus, Web of Science, and SciELO, for relevant studies published before march 2022, by using the ‘Tityus’ and ‘symptomatic treatment’ or ‘antivenom serum’ or ‘cardiorespiratory support’ or ‘envenoming’ or ‘trial’ or ‘treatment’ or ‘treatment strategy’ or ‘immunotherapy’. A manual review of the reference lists in each identified study was also conducted. When applicable, attempts were also made to contact investigators for clarification or additional unpublished data. No language and age restrictions were imposed.

The search was performed independently by four authors (A.D.S., N.O.I. and I.M.M.). In case of disagreement, a fourth investigator was consulted (M.S.). Any discrepancies among the reviewers were resolved through consensus.

Inclusion/exclusion criteria

We included the studies that met the following criteria: incidents in human involving scorpion stings involving *Tityus* spp., studies dealing with signs and symptoms, and therapeutics of incidents involving scorpions; and prospective or retrospective observational studies (descriptive or analytical), case series, as well as clinical trials, and antivenom safety, tolerability, and efficacy. Letters, short communications, animal and in vitro studies were excluded from the analysis. We also exclude molecular epidemiology and purely mechanistic pathogenesis studies, duplicate studies and trials without sufficient data.

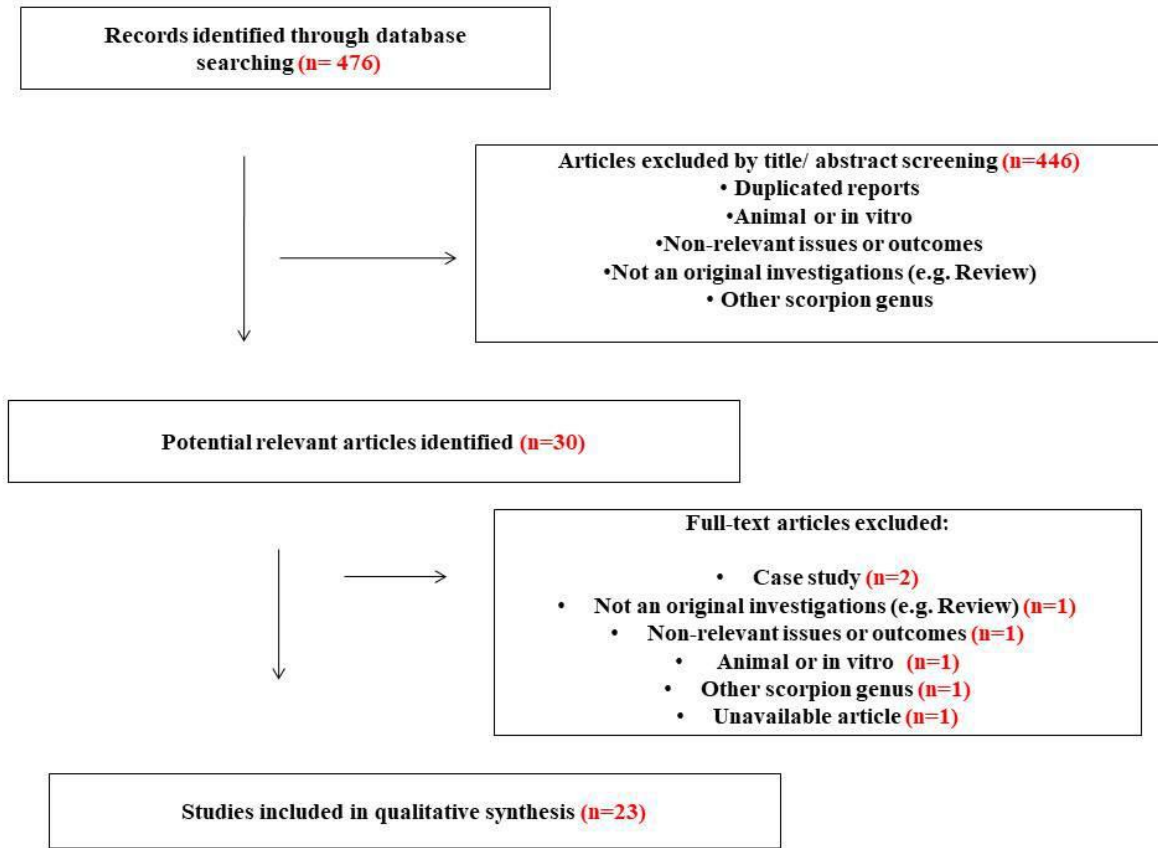
Data extraction

Data extraction was performed by five independent investigators. The extracted included the study characteristics (authors and publication year), study design, geographic area, scorpion species, number of subjects, mean age, symptoms or clinical manifestations, interventions or treatment, outcomes, mortality (%), time between the sting and hospital arrival and study duration.

3. Results

The literature search generated 476 references (Figure 1). After removing that did not meet the inclusion criteria, 30 references remained. The 30 potentially relevant articles were examined for full text assessment. After evaluation, 6 articles were excluded for the following reasons: two studies were case studies, one not original investigations, one not relevant issues or outcomes, one study in animals or in vitro, one was about another scorpion genus, and an unavailable article. Thus, 23 studies were included in the systematic review (Table 1).

Figure 1 - Flow diagram of studies included in the systematic review.



Source: Authors.

Table 1 - Characteristics of included studies.

First author, publication year	Design	Geographic area	Scorpion species	Subjects	Mean age or range (years)	Study duration
Gomes et al. 2020	Case series	Two cities in the Western Brazilian Amazon	<i>Tityus</i>	151	5 to 49 years	June 2014 to December 2019
Frassone et al. 2019	Retrospective study	Cordoba, Argentina	<i>T. trivittatus</i>	450	25 to 52 years	December 2014 to February 2015
Roman et al. 2018	Retrospective study	Amazonian province of Morona Santiago, southeastern Ecuador.	<i>T. obscurus</i>	20	1 to 40 years	January 2015 to December 2016
Coelho et al. 2016	Prospective and observational study	Belém and Ananindeua, Pará state, Brazil	<i>T. silvestres</i>	13	9 to 57 years	2007 to 2011
Torrez et al. 2015	Prospective and observational study	Santarem, Pará state, Brazil	<i>T. obscurus</i>	58	1 to 90 years	April, 2008 to January, 2014.
Borges et al. 2015	Case series	Chone and Flavio, Manabí state, Ecuador	<i>T. asthenes</i>	5	1.9 to 16 years	August to November 2014
Bucaretschi et al. 2014	Retrospective study	Campinas, São Paulo state, Brazil,	<i>T. bahiensis</i> and <i>T. serrulatus</i>	1327	15 to 42 years	1994 - 2011
Pardal et al. 2014	Prospective, case series.	Two areas of the state of Pará, Brazil	<i>T. obscurus</i>	48	Median of 31.5 (23–41) years in the east, and 31.5 (20–50) years in the west, but the accidents happened mainly to patients older than 15 in both areas.	January 2008 to July 2011.
Gomez et al. 2010	Retrospective and prospective	Mutata, Colombia	<i>T. asthenes</i>	80	Twenty-five bites (31.2%) were in children under 15 years of age and 55 (68.8%) in adults between the ages of 15 and 77.	September 2005 to February 2007
Cupo et al. 2007	Prospective and experimental.	Ribeirão Preto, São Paulo state, Brazil	<i>T. serrulatus</i>	12	1 to 12 years	May and June 2006
De Souza et al. 2007	Case series	Village of La Sierra, Margarita Island, State of Nueva Esparta,	<i>T. neoespartanus</i>	2	8 and 13-years	January 1990 to December 1992

Northeastern, Venezuela						
Fukuhara et al. 2003	Case-control	Ribeirão Preto, São Paulo state, Brazil	<i>T. serrulatus</i>	27	(n=15, mean age=42.2 years), (n=8, mean age=26 years) e (n=4, mean age=14 years).	NA
D'Suze et al. 2003	NA	Los Teques, Venezuela and Caracas, Venezuela	<i>T. discrepans</i>	205	NA	January 1999 to August 2000
Dávila et al. 2002	Cross-sectional	Merida state, Venezuela	<i>T. zulianus</i>	16	7.6 ±3.4 (mean±SD)	NA
Cupo et al. 2002	Case series	Ribeirão Preto, São Paulo state, Brazil	<i>T. serrulatus</i>	8	2 to 9	1990 to 1996
Reyes-Lugo et al. 2001	Descriptive study	Northern coastal region of Venezuela	<i>T. discrepans</i> Pocock	1045	18.4% (0-5 years), 13.6% (6-10 years), 9.6% (11-15 years), 11% (16-20 years), 11.4% (21-25 years), 8.3% (26-30 years), 7.8% (31-35 years), 6% (36-40 years) and 13.9% (>41 years)	January 1982 to December 1995
Lira-da-Silva et al. 2000	Retrospective study	Bahia state, Brazil	<i>T. stigmurus</i>	237	0 to 7 years - 12 % 8 to 14 years - 19 % > 14 years - 69 %	June 1998
Magalhães et al. 1999	Case series	Belo Horizonte, Minas Gerais state, Brazil and Campinas, São Paulo state, Brazil	<i>T. serrulatus</i>	17	Mild case - 9.8 ± 10.0 (mean±SD) years Moderate cases - 6.4± 2.6 years Severe case - 6 years	January 1992 to December 1993
De Rezende et al. 1996	Retrospective study	Belo Horizonte, Minas Gerais state, Brazil	<i>T. serrulatus</i>	56	1 to 40 years	January to May 1994
Bucarechi et al. 1995	Retrospective study	Campinas, São Paulo state, Brazil	<i>T. bahiensis</i> and <i>T. serrulatus</i>	17	<15 years	NA
Freire-Maia et al. 1994	Retrospective study	Belo Horizonte, Minas Gerais state, Brazil	<i>T. serrulatus</i>	3860 - (2822 adults and 1038 children)	3860 - (2822 adults and 1038 children)	1972- 1987
Amaral et al. 1994	Retrospective study	Belo Horizonte, Minas Gerais state, Brazil	<i>T. serrulatus</i>	103	<15 years	April 1990, to November 1992
Hering et al. 1993	NA	Ribeirão Preto, São Paulo state, Brazil	<i>T. serrulatus</i>	12	4 to 18 years	November 1988 to November 1991

NA - not available. Source: Authors.

Eight selected studies were retrospective studies (Amaral et al., 1994; Bucarechi et al., 1995; Bucarechi et al., 2014; De Rezende et al., 1996; Frassone et al., 2019; Freire-Maia et al., 1994; Lira-da-Silva et al., 2000; Román et al., 2018), six were case series (Borges et al., 2015; Cupo & Hering, 2002; De Sousa et al., 2007; Gomes et al., 2020; Magalhães et al., 1999; Pardal et al., 2014), two prospective and observational studies (Coelho et al., 2016; Torrez et al., 2015), one study with retrospective and prospective data (J. P. Gómez et al., 2010), a prospective and experimental study (Cupo et al., 2007), a case-control study (Fukuhara et al., 2003), a cross-sectional study (Mazzei de Dávila et al., 2002), a descriptive study (Reyes-Lugo & Rodriguez-Acosta, 2001), and finally, two studies with uninformed designs (D'Suze et al., 2003; Hering et al., 1993). As for the place of completion, Brazil contributed with 15 studies (Amaral et al., 1994; Bucarechi et al., 1995; Bucarechi et al., 2014; Coelho et al., 2016; Cupo et al., 2007; Cupo & Hering, 2002; De Rezende et al., 1996; Freire-Maia et al., 1994; Fukuhara et al., 2003; Gomes et al., 2020; Hering et al., 1993; Lira-da-Silva et al., 2000; Magalhães et al., 1999; Pardal et al., 2014; Torrez et al., 2015), Venezuela with four works (D'Suze et al., 2003; De Sousa et al., 2007; Mazzei de Dávila et al., 2002; Reyes-Lugo & Rodriguez-Acosta, 2001), Ecuador with two (Borges et al., 2015; Román et al., 2018) and Argentina and Colombia with one study each (Frassone et al., 2019; J. P. Gómez et al., 2010).

About accident-causing species, eight studies were with the species *T. serrulatus* (Amaral et al., 1994; Cupo et al., 2007; Cupo & Hering, 2002; De Rezende et al., 1996; Freire-Maia et al., 1994; Fukuhara et al., 2003; Hering et al., 1993; Magalhães et al., 1999). Another three were with the species *T. obscurus* (Pardal et al., 2014; Román et al., 2018; Torrez et al., 2015), two were *T. asthenes* (Borges et al., 2015; J. P. Gómez et al., 2010) and nine studies with each of these species: *T. trivittatus* (Frassone et al., 2019), *T. silvestres* (Coelho et al., 2016), *T. bahiensis* and *T. serrulatus* (Bucarechi et al., 2014), *T. neoespartanus* (De Sousa et al., 2007), *T. discrepans* (D'Suze et al., 2003), *T. zulianus* (Mazzei de Dávila et al., 2002), *T. discrepans* Pocock (Reyes-Lugo & Rodriguez-Acosta, 2001), *T. stigmurus* (Lira-da-Silva et al., 2000), *T. bahiensis* and *T. serrulatus* (Bucarechi et al., 1995). In addition, one study reported the genus, without mentioning the specie (Gomes et al., 2020).

The number of participants studied ranged from 2 to 3860, totaling 7,781 participants. Nine articles were carried out with children (14, 22, 24, 25, 26, 27, 32, 34, 37), two studies with adults (17, 28), and eleven studies with children and adults (12, 23, 18, 19, 29, 20, 21, 30, 31, 33, 35).

Clinical characteristics of envenoming

The time elapsed between the accident and medical care ranged from 15 minutes to more than 6 hours. Symptoms and clinical manifestations were classified as mild, moderate and severe in 13 studies (Cupo et al., 2007; Cupo & Hering, 2002; D'Suze et al., 2003; De Sousa et al., 2007; Frassone et al., 2019; Freire-Maia et al., 1994; Fukuhara et al., 2003; J. P. Gómez et al., 2010; Lira-da-Silva et al., 2000; Magalhães et al., 1999; Pardal et al., 2014; Reyes-Lugo & Rodriguez-Acosta, 2001; Torrez et al., 2015), or divided into classes I, II and III in 4 studies (Borges et al., 2015; Bucarechi et al., 2014; Coelho et al., 2016; Gomes et al., 2020; Román et al., 2018). Another five studies reported symptoms, but did not classify in any category (Amaral et al., 1994; Bucarechi et al., 1995; De Rezende et al., 1996; Hering et al., 1993; Mazzei de Dávila et al., 2002) (Table 2). Briefly, mild envenoming cases (Class I) are envenomation with manifestations only at the bite site including pain at the sting site, edema, paresthesia. Moderate envenoming cases (Class II) are envenomation with minor systemic manifestations, not life threatening, such as sialorrhea, diaphoresis, somnolence, hypo- and hypertension, tachycardia, tachypnea. Severe envenoming (Class III) includes life-threatening manifestations as cardiac insufficiency, respiratory and/or neurological failure (J. P. Gómez et al., 2010; Khattabi et al., 2011).

Table 2 - Clinical characteristics of included studies.

First author, publication year	Time between accident and hospital arrival	Symptoms or clinical manifestation	Interventions or treatment	Outcomes	Mortality (%)
Gomes et al. 2020	≤ 6h in 92.1% of the cases	Cases were mostly class I (122; 80.8%) and class II (24; 15.9%). Five (3.3%) class III cases were reported	Antivenom treatment was given to the patients in doses corresponding to moderate or severe envenomation, after pre-medication with hydrocortisone (500 mg), dexchlorpheniramine (50 mg, iv) and ranitidine (50 mg, iv)	Antivenoms showed little efficacy in the treatment of envenoming by some Amazonian scorpions'	0%
Frassone et al. 2019	NA	5 patients (<1%) were diagnosed as moderate cases. All other cases were diagnosed as mild	Moderate cases received antivenom, steroids, antihistamines, tetanus booster.	No hospital admissions, and no need for continuous cardiac monitoring. No deaths.	0%
Roman et al. 2018	8.3h ± 6.2 (mean±SD)	One patient was classified as Class I, 18 patients as Class II and one patient as Class III which proved fatal	All patients were hydrated with saline solution, and treated with paracetamol or tramadol as analgesic, and metoclopramide hydrochloride as antiemetic. No patients received scorpion antivenom, as it is not available in Ecuador	One death (a 4- year-old male)	5%
Coelho et al. 2016	2h	Ten patients were classified as Class I and three patients as Class II.	All patients with local manifestations were treated with analgesics and under clinical observation for 3 to 6h. Of the 3 severe cases, only the one with malaise, nausea and prostration was treated with two ampoules of specific antivenom.	All victims had a favorable outcome. All patients had clinical improvement and were discharged from the hospital within 6h of admission.	0%
Torrez et al. 2015	26.4% were admitted in <3 h	15 (25.8%) patients had mild, 28 (48.3%) had moderate, and 15 (25.8%) had severe envenoming	Hydrocortisone - 74.1%; Anti-histamine 53.4%; Intravenous analgesic 43.1%; Scorpion antivenom or Aracnicid antivenom 91.4%; Benzodiazepine 53.4%	Antivenom and benzodiazepines, intravenously, with progressive reduction in the clinical manifestations.	NA
Borges et al. 2015	0.5-2.5h	Three Class II (moderate) and two in Class III (severe) envenoming	Vital support measures and pharmacological management. Acetaminophen 125, 240 or 500 mg (orally), dexamethasone (3.5 mg i.m. or 8 mg i.v.); Hydrocortisone (500 mg intravenously), ketorolac (60 mg i.v., Clemastine (1 mg i.m.) metoclopramide (i.v.), loratadine (orally)]- no scorpion antivenom is currently available in Ecuador.	A child one year and eleven months old male died.	20%
Bucaretechi et al. 2014	0.75-2.7h	Dry stings - 3.4%, class I - 79.6%, class II - 15.1%, class III - 1.8% and fatal - 0.1%.	Scorpion antivenom in all children who developed systemic clinical manifestations and for severe cases in adults. Of the 25 patients with severe envenomation, 22 received dobutamine, 13 were given furosemide and 17 were intubated.	Of the 25 patients with severe envenomation: The median length of the hospital stay was five days. The fatal case involved an 6-year-old girl.	0,1%
Pardal et al. 2014	0.3-2.0h	Level I: 75%	Patients with only local manifestations were treated with	All patients evolved to healing	0%

		Level 2: 25%	analgesics. Patients with local and systemic manifestations were treated as follows: vital functions monitored and received supportive care; benzodiazepines to those with myoclonus; and 15 ml of scorpion antivenom which was infused intravenously over a 20-minute period.	after treatment.	
Gomez et al. 2010	Mean- 55 min	Mild cases - 88% Moderate cases - 11.2%.	Serotherapy in moderate and severe cases. Mild cases: 59% Oral and parenteral analgesics (2% lidocaine without vasoconstrictor). Severe cases: antiemetic (metoclopramide), antihypertensive drugs (prazosin and nifedipine), hydration, oxygen therapy, antihistamines and corticosteroids	There were no deaths or sequels.	0%
Cupo et al. 2007	1- 4h	severe cases	All received Antivenom. dobutamine, 5–7.5 µg/kg/min, for 24–48 h in addition to support treatment.	All patients had a satisfactory outcome	0%
De Souza et al. 2007	NA	Moderately to severe and developed pancreatic involvement and electrocardiographic abnormalities	Hydrated, cimetidine and metoclopramide intravenously. 13 years old patient received three ampoules (5ml each) of anti-scorpion antivenom (anti-Tityus discrepans).	8 years old patient - was discharged on 3 day and had spontaneous evolution, since no anti-scorpion antivenom was administered. 13 years old patient – The clinical and electrocardiographic manifestations disappeared two hours after antivenom administration.	0%
Fukurama et al. 2003	NA	mild (n =15), moderate (n =8), severe (n=4) envenomation.	Patients presenting with moderate or severe envenomation were treated with antivenom against Ts. The antivenom was given intravenously 30 min after premedication consisting of 5 mg dexchlorpheniramine, 50 mg ranitidine and 500 mg hydrocortisone.	NA	0% NA
G D'Suze et al. 2003	Group A- 4.5h ± 3.3 Group B- 1.2h ± 0.4	local symptomatology (n = 164), moderate systemic symptomatology (n= 36) and cases with severe systemic symptomatology (n=5).	NA	NA	NA
Dávila et al. 2002	0.83-5 h	10 patients had cardiovascular manifestations of pulmonary edema and Six patients had no cardiovascular manifestations.	Antivenin	All patients survived the accident, chest X-rays cleared and left ventricular wall motion and function returned to normal within 4–6 days.	0%

Cupo et al. 2002	6 h (61% of the patients);	All patients with severe envenoming showed clinical manifestations of cardiac dysfunction and five developed pulmonary edema	All received antivenom and corticosteroid. Patients with pulmonary edema received dobutamine.	All patients showed improvement in general clinical symptoms after antivenom therapy.	0%
Reyes Lugo et al. 2001	NA	Light Scorpion Envenoming - 72.06% Moderate Scorpion Envenoming - 16.55%: Intense Scorpion Envenoming - 9.95% and Severe Scorpion Envenoming -with 1.44%	In all cases antivenom scorpion was applied.	Most of patients had a satisfactory outcome. A death recorded -a 5-year-old boy.	0,096%
Lira-da-Silva et al. 2000	Mild cases: 2.02h±1.3 Moderate cases 1.82h±0.9 Severe case (n=1): 0.5h	Pain (94.4%), numbness (30%), edema (17.8%), erythema (17.8%) and paresthesia (15.6%) and general: headache (14%), vomiting (4. 4%) and sweating (3.3%).	92.5% of the patients did not use the antivenom scorpion. Among those, who received antivenom scorpion, 1.1% received 2 to 4 ampoules and 6.4% received 5 to 10 ampoules.	Most (94%) were mild and all progressed to a cure.	0%
Magalhães et al. 1999	After a mean time of 1.5 h	Mild (n = 6), moderate (n = 10) and severe cases (n = 1).	Treated with of scorpion antivenom - moderate and severe cas. And treated with symptomatic measures and support for vital functions as required.	NA	NA
De Rezende et al. 1996	NA	Patients with only local pain at the site of the sting (n = 37), and patients with systemic manifestations of envenoming (n = 19).	Patients with systemic manifestations - scorpion antivenom and symptomatic measures and support of vital functions	Although all patients recovered completely, cardiorespiratory manifestations were still present in some patients after neutralization of venom antigens.	
Bucarechi et al. 1995	Retrospective study	Vomiting (17), diaphoresis (15), tachycardia (14), prostration (10), tachypnea (8), arterial hypertension (7), arterial hypotension (5), tremors (5), hypothermia (4), sinusal tachycardia (16/17) and a myocardial infarction-like pattern (11/17).	Antivenom, and five children with pulmonary edema were treated with mechanical ventilation and positive inotropic drugs. A two-year-old child with severe respiratory failure, pulmonary edema, vomiting, was treated with scorpion antivenin, parenteral administration of fluids, mechanical ventilation, dobutamine infusion and furosemide administration.	A child aged two-years old died 65 h after a <i>T. serrulatus</i> sting.	5,88%
Freire-Maia et al. 1994	NA	Lung edema was unilateral in several cases, with the presence of air bronchograms and a peripheral distribution	Symptomatic measures, support of vital functions and Antivenom. Pain was treated with i.v . dipyron. Vomiting, was treated with i.v . injection of metoclopramide (0 .5-1 .0 mg/kg) followed by oral administration of the same drug 2-3 times per day. Hyperthermia was controlled with i .v . injection of dipyron (40 mg/kg day) and/or tepid water sponging.	Low incidence of early anaphylactic reactions following antivenom administration.	Children-1% and rate in the total number of patient was

0.28%.

Amaral et al. 1994	NA	Group 1 (n = 28) when they presented only local pain Group 2 (n = 75) when they presented systemic involvement.	Antivenom. At the first sign of anaphylactic reaction, 0.01 ml/kg of body weight of 0.1 % adrenaline was injected s.c . followed by i .m . injection of promethazine (0 .5 mg/kg/dose).	children with adrenergic manifestations after T. serrulatus scorpion sting had significantly lower anaphylactic reactions to antivenom than those without these manifestations.	NA
Hering et al. 1993	0.25-6.5 h	These patients had important echocardiographic evidence of moderate to severe left ventricular (LV) dysfunction with diffuse LV hypokinesia and reduced ejection fraction. Seven developed pulmonary edema	All patients received intravenous scorpion anti venom on admission immediately after administration of corticosteroids and H 1- and H2-receptor antagonists. A local anaesthetic was used to control pain when necessary, together with anti-emetic agents and parenteral hydration.	All patients had a satisfactory course and were discharged within 1 week.	0%

NA - not available. Source: Authors.

All cases of scorpion stings should be treated based on the relief of the signs and symptoms of envenomation, neutralization of circulation venom and supporting the vital functions (Marangoni et al., 1990). The treatments performed in the studies that make up this review include scorpion antivenoms (Amaral et al., 1994; Bucarechi et al., 1995; Bucarechi et al., 2014; Coelho et al., 2016; Cupo et al., 2007; Cupo & Hering, 2002; De Rezende et al., 1996; De Sousa et al., 2007; Frassone et al., 2019; Freire-Maia et al., 1994; Fukuhara et al., 2003; Gomes et al., 2020; Hering et al., 1993; Lira-da-Silva et al., 2000; Magalhães et al., 1999; Mazzei de Dávila et al., 2002; Pardal et al., 2014; Reyes-Lugo & Rodriguez-Acosta, 2001; Torrez et al., 2015), corticosteroids (Borges et al., 2015; Cupo & Hering, 2002; Fukuhara et al., 2003; Gomes et al., 2020; Hering et al., 1993; Torrez et al., 2015), anesthetics (Coelho et al., 2016; J. P. Gómez et al., 2010; Hering et al., 1993; Pardal et al., 2014; Román et al., 2018; Torrez et al., 2015), antiemetics agents (Borges et al., 2015; De Sousa et al., 2007; Frassone et al., 2019; Fukuhara et al., 2003; Gomes et al., 2020; Juan P Gómez et al., 2010; Hering et al., 1993; Román et al., 2018; Torrez et al., 2015), inotropics (Bucarechi et al., 1995; Bucarechi et al., 2014; Cupo et al., 2007; Cupo & Hering, 2002), antihypertensives (J. P. Gómez et al., 2010) and benzodiazepines (26, 28) drugs. In six studies, fatal cases were observed (Borges et al., 2015; Bucarechi et al., 1995; Bucarechi et al., 2014; Freire-Maia et al., 1994; Reyes-Lugo & Rodriguez-Acosta, 2001; Román et al., 2018) (Table 2). Among the fatal cases, most were children 1 to 6 - y. The exception is in one study that did not inform the age, but reported that it was a child < 14 y. All of them developed severe cases of scorpionism, being that three accidents were caused by *T. serrulatus* (15, 18, 19), one by *Tityus asthenes* (22), one by *Tityus discrepans* (33), and one by *Tityus obscurus* (14). The causes of death were pulmonary edema and refractory shock (18), severe respiratory failure (15), cardiorespiratory failure (14, 22).

4. Discussion

In Brazil, Argentina and Colombia, many studies used the classification of envenoming as mild, moderate and severe. However, some studies published after 2011 show the classification of accidents according to the Scorpion Consensus Expert Group (Khattabi et al., 2011). We believe that these consensus-based tools are important to every healthcare professional in the worldwide world, classifying scorpion stings and their clinical signs and symptoms unequivocally.

Intravenous administration of scorpion antivenom was used to treat the majority of patients with moderate or severe envenomation is an exception in Ecuador because there, scorpion antivenom is not available. Antivenom therapy has been advocated as an important treatment for scorpion stings. Antivenom is appropriate, both curative because it eliminates the venom and preventive because it reduces the risk of subsequent complications (Chippaux, 2012). In Brazil, the Ministry of Health recommends that scorpion antivenom treatment must be given as soon as possible (Nascimento et al., 2006). However, *T. obscurus* venom is poor recognition by the antiserum raised against other species of the *Tityus* genus. The venom composition of *T. serrulatus* and *T. obscurus* are considerably similar in terms of the major classes of proteins produced and secreted, but their individual toxin sequences are considerably divergent (Abroug et al., 2020; Khattabi et al., 2011).

In this review, four studies mentioned using antihistamines as premedication in combination with antivenoms (Fukuhara et al., 2003; Gomes et al., 2020; Hering et al., 1993; Torrez et al., 2015). Furthermore, in two studies, ranitidine and hydrocortisone were used as premedication in combination with antihistamines (Fukuhara et al., 2003; Gomes et al., 2020). In antivenom treatment, promethazine and chlorpheniramine are most frequently used as premedication (Khattabi et al., 2011). From a theoretical perspective, antihistamine premedication can block or reduce the undesirable effects of histamine, but has no influence on the effects of other mediators such as prostaglandins and leukotriene (Kalapothakis et al., 2021).

Although in the selected studies most cases were classified as mild or class I, only in six studies (Coelho et al., 2016; J. P. Gómez et al., 2010; Hering et al., 1993; Pardal et al., 2014; Román et al., 2018; Torrez et al., 2015), the use of anesthetics

for local pain was reported. In one study (Román et al., 2018), the use of paracetamol or tramadol was mentioned. Acetaminophen was used in one study (Borges et al., 2015). Dipyrrone or topical 2% lidocaine without vasoconstrictor was used in another two studies respectively (Freire-Maia et al., 1994; J. P. Gómez et al., 2010). A randomized trial comparing intravenous paracetamol, topical lidocaine, and ice application for treatment of pain associated with scorpion stings revealed that topical lidocaine is superior to both intravenous paracetamol and local ice application and its effect lasts several hours after envenomation. However, this one excluded patients with severe envenoming (Aksel et al., 2015). Use of analgesics and anesthetics varies because it depends on each person's pain threshold.

The use of Clemastine, loratadine, dexchlorpheniramine, all H1 antihistaminic agents, cimetidine and ranitidine, both H2 antihistaminic agents were used to treat emesis. Four studies (Borges et al., 2015; De Sousa et al., 2007; Román et al., 2018) have reported the use of metoclopramide as an antiemetic agent. If profuse vomiting does not cease after scorpion antivenom, antiemetics can be used (Cupo, 2015).

Glucocorticoids was used as a premedication in seven studies (Borges et al., 2015; Cupo & Hering, 2002; Fukuhara et al., 2003; Gomes et al., 2020; Hering et al., 1993; Torrez et al., 2015), among which hydrocortisone and dexamethasone were most used. In 2 studies (Borges et al., 2015; Román et al., 2018), carried out in Ecuador, the use of antihistamines, antiemetics agents and glucocorticoids for the treatment of scorpionism is demonstrated to be important, since scorpion antivenom is not available there (Table 2). In each study, one death was reported in children. The use of dexamethazone is controversial, but in situations in which delayed antivenom treatment increases the risk of death, this use is encouraged (Reis et al., 2020). However, other studies demonstrate that dexamethasone doesn't have any benefits in the management of scorpion sting (Bahloul et al., 2013; Malaque et al., 2015).

The severity of ventricular dysfunction is usually treated with inotropic drugs. Dobutamine was used in four studies (Bucarechi et al., 1995; Bucarechi et al., 2014; Cupo et al., 2007; Cupo & Hering, 2002). Some studies (Elatrous et al., 1999; Isbister & Bawaskar, 2014; Shaw et al., 1987) have demonstrated that the use of dobutamine had beneficial effects on left and right ventricle function with a significant improvement in the ejection fraction.

One study (J. P. Gómez et al., 2010) reported the use of prazosin and nifedipine drugs in severe cases in combination with antiemetic (metoclopramide), antihistamines, corticosteroids and serotherapy. Hypertension is common and occurs early in response to sympathetic stimulation (Isbister & Bawaskar, 2014). When present, high blood pressure should not be systematically treated and antihypertensive medication administered only in patients with pre-existing chronic hypertension, hypertensive crises, or with acute pulmonary edema (40). Prazosin is recommended for the treatment of scorpion envenoming, especially in India (Bawaskar & Bawaskar, 1996). A meta-analysis showed a significant benefit for the antivenom and prazosin combination in accidents caused by an Indian scorpion, *Hottentotta tamulus* (Rodrigo & Gnanathan, 2017).

In two studies by the same author (Bucarechi et al., 1995; Bucarechi et al., 2014), furosemid was used in severe envenomation (class III). However, it was demonstrated that diuretics associated with beta-adrenergic agonists increase sympathetic activation and mortality in the presence of left ventricular dysfunction (Abraham et al., 2005; Francis et al., 1985). Accordingly, Santiago et al. (2010) amiodarone, by acting as a neuromodulator, is very likely responsible for the early and progressive decrease of serum norepinephrine patients with acutely depressed left ventricular function secondary to scorpion envenomation (Santiago et al., 2010).

In the state of Pará, northern Brazil, many envenomations are caused by *Tityus obscurus*. Patients stung by that scorpion usually present numerous neurological symptoms such as myoclonus, dysmetria, dysarthria, ataxia, and hyperreflexia (Torrez et al., 2015). To treat myoclonus, 2 studies (Pardal et al., 2014; Torrez et al., 2015) reported using benzodiazepines. Torrez et al. (Torrez et al., 2015), described 58 accidents presumably caused by *Tityus obscurus*, and the vast majority of

patients presented a clinical picture compatible with acute cerebellar dysfunction. They affirm that antivenom did not significantly reduce the severity of the cerebellar-muscular manifestations after the antivenom administration. For this reason, they used benzodiazepines, intravenously, to reduce the progress of these abnormalities.

5. Conclusion

In summary, our systematic review shows in prospective or retrospective observational studies the clinical manifestations and management of the *Tityus* scorpion sting. The majority of scorpion envenomation by *Tityus* spp. is mild. Although they are not the majority, severe and moderate cases can cause death. Management of *Tityus* scorpion envenoming is supportive and focused on the patient's symptoms. In severe cases, antivenoms, if available, are indicated. Medications to monitor vagal and adrenergic symptoms are encouraged. The severity of ventricular dysfunction is usually treated with dobutamine, while antiemetics can be used to treat emesis. The use of diuretics is controversial. We have not found clinical trials for stings by *Tityus* spp. scorpion. In addition, this review included studies that only considered treatment for stings caused by the *Tityus* genus, so the results obtained have the potential to help professionals who deal with envenoming caused by *Tityus* scorpions.

Based on studies included in this review, we concluded that management of *Tityus* scorpion envenoming is supportive and focused on the patient's symptoms. In severe cases, antivenoms, if available, are indicated. Medications to monitor vagal and adrenergic symptoms are encouraged. This study has the potential to help professionals who deal with envenoming caused by the genus *Tityus*.

Animal venoms contain a complex mixture of bioactive molecules, many of which have evolved to immobilize or kill prey. However, some of these venom components also exhibit properties that make them promising candidates for drug development and therapeutic applications. Therefore, we suggest research and systematic reviews that explore the therapeutic potential of animal toxins.

Acknowledgments

We thank Rachel Campos Ornelas, graduate student at the Federal University of Juiz de Fora, GV *Campus*, for helping with the creation of the manuscript.

References

- Abraham, W. T., Adams, K. F., Fonarow, G. C., Costanzo, M. R., Berkowitz, R. L., LeJemtel, T. H., & Group, A. S. (2005). In-hospital mortality in patients with acute decompensated heart failure requiring intravenous vasoactive medications: an analysis from the Acute Decompensated Heart Failure National Registry (ADHERE). *Journal of the American College of Cardiology*, *46*(1), 57-64.
- Abroug, F., ElAtrous, S., Nouria, S., Haguiga, H., Touzi, N., & Bouchoucha, S. (1999). Serotherapy in scorpion envenomation: a randomised controlled trial. *The Lancet*, *354*(9182), 906-909.
- Abroug, F., Ouanes-Besbes, L., Tilouche, N., & Elatrous, S. (2020). Scorpion envenomation: state of the art. *Intensive Care Med*, *46*(3), 401-410. <https://doi.org/10.1007/s00134-020-05924-8>
- Aksel, G., Güler, S., Doğan, N., & Çorbacıoğlu, Ş. (2015). A randomized trial comparing intravenous paracetamol, topical lidocaine, and ice application for treatment of pain associated with scorpion stings. *Human & Experimental Toxicology*, *34*(6), 662-667.
- Amaral, C. F., Dias, M. B., Campolina, D., Proietti, F. A., & de Rezende, N. A. (1994). Children with adrenergic manifestations of envenomation after *Tityus serrulatus* scorpion sting are protected from early anaphylactic antivenom reactions. *Toxicon*, *32*(2), 211-215. [https://doi.org/10.1016/0041-0101\(94\)90110-4](https://doi.org/10.1016/0041-0101(94)90110-4)
- Bahloul, M., Chaari, A., Ammar, R., Allala, R., Dammak, H., Turki, O., & Bouaziz, M. (2013). Severe scorpion envenomation among children: does hydrocortisone improve outcome? A case-control study. *Transactions of the royal society of tropical medicine and hygiene*, *107*(6), 349-355.
- Bawaskar, H., & Bawaskar, P. (1996). Severe envenoming by the Indian red scorpion *Mesobuthus tamulus*: the use of prazosin therapy. *QJM: An International Journal of Medicine*, *89*(9), 701-704.

- Borges, A., Morales, M., Loor, W., & Delgado, M. (2015). Scorpionism in Ecuador: First report of severe and fatal envenoming cases from northern Manabí by *Tityus asthenes* Pocock. *Toxicon*, *105*, 56-61. <https://doi.org/10.1016/j.toxicon.2015.08.019>
- Boubekour, K., L'Hadj, M., & Selmane, S. (2020). Demographic and epidemiological characteristics of scorpion envenomation and daily forecasting of scorpion sting counts in Touggourt, Algeria. *Epidemiology and health*, *42*.
- Bucarechi, F., Baracat, E. C., Nogueira, R. J., Chaves, A., Zambrone, F. A., Fonseca, M. R., & Tourinho, F. S. (1995). A comparative study of severe scorpion envenomation in children caused by *Tityus bahiensis* and *Tityus serrulatus*. *Rev Inst Med Trop Sao Paulo*, *37*(4), 331-336. <https://doi.org/10.1590/s0036-46651995000400008>
- Bucarechi, F., Fernandes, L. C., Fernandes, C. B., Branco, M. M., Prado, C. C., Vieira, R. J., & Hyslop, S. (2014). Clinical consequences of *Tityus bahiensis* and *Tityus serrulatus* scorpion stings in the region of Campinas, southeastern Brazil. *Toxicon*, *89*, 17-25. <https://doi.org/10.1016/j.toxicon.2014.06.022>
- Casewell, N. R., Wüster, W., Vonk, F. J., Harrison, R. A., & Fry, B. G. (2013). Complex cocktails: the evolutionary novelty of venoms. *Trends in ecology & evolution*, *28*(4), 219-229.
- Chippaux, J.-P., & Goyffon, M. (2008). Epidemiology of scorpionism: a global appraisal. *Acta tropica*, *107*(2), 71-79.
- Chippaux, J. P. (2012). Emerging options for the management of scorpion stings. *Drug Des Devel Ther*, *6*, 165-173. <https://doi.org/10.2147/dddt.s24754>
- Coelho, J. S., Ishikawa, E. A., Dos Santos, P. R., & Pardal, P. P. (2016). Scorpionism by *Tityus silvestris* in eastern Brazilian Amazon. *J Venom Anim Toxins Incl Trop Dis*, *22*(1), 24. <https://doi.org/10.1186/s40409-016-0079-2>
- Cupo, P. (2015). Clinical update on scorpion envenoming. *Rev Soc Bras Med Trop*, *48*(6), 642-649. <https://doi.org/10.1590/0037-8682-0237-2015>
- Cupo, P., Figueiredo, A. B., Filho, A. P., Pintya, A. O., Tavares Júnior, G. A., Caligaris, F., & Simões, M. V. (2007). Acute left ventricular dysfunction of severe scorpion envenomation is related to myocardial perfusion disturbance. *Int J Cardiol*, *116*(1), 98-106. <https://doi.org/10.1016/j.ijcard.2006.02.015>
- Cupo, P., & Hering, S. E. (2002). Cardiac troponin I release after severe scorpion envenoming by *Tityus serrulatus*. *Toxicon*, *40*(6), 823-830. [https://doi.org/10.1016/s0041-0101\(02\)00080-6](https://doi.org/10.1016/s0041-0101(02)00080-6)
- D'Suze, G., Moncada, S., González, C., Sevcik, C., Aguilar, V., & Alagón, A. (2003). Relationship between plasmatic levels of various cytokines, tumour necrosis factor, enzymes, glucose and venom concentration following *Tityus* scorpion sting. *Toxicon*, *41*(3), 367-375. [https://doi.org/10.1016/s0041-0101\(02\)00331-8](https://doi.org/10.1016/s0041-0101(02)00331-8)
- De Rezende, N. A., Chavéz-Olortegui, C., & Amaral, C. F. S. (1996). Is the severity of *Tityus serrulatus* scorpion envenoming related to plasma venom concentrations? *Toxicon*, *34*(7), 820-823.
- De Sousa, L., Boadas, J., Kiriakos, D., Borges, A., Boadas, J., Marcano, J., & De Los Ríos, M. (2007). Scorpionism due to *Tityus neoespartanus* (Scorpiones, Buthidae) in Margarita Island, northeastern Venezuela. *Revista da Sociedade Brasileira de Medicina Tropical*, *40*(6), 681-685.
- Elatrous, S., Noura, S., Besbes-Ouanes, L., Boussarsar, M., Boukef, R., Marghli, S., & Abroug, F. (1999). Dobutamine in severe scorpion envenomation: effects on standard hemodynamics, right ventricular performance, and tissue oxygenation. *Chest*, *116*(3), 748-753.
- Francis, G. S., Siegel, R. M., Goldsmith, S. R., Olivari, M. T., Levine, T. B., & Cohn, J. N. (1985). Acute vasoconstrictor response to intravenous furosemide in patients with chronic congestive heart failure: activation of the neurohumoral axis. *Annals of internal medicine*, *103*(1), 1-6.
- Frassone, N. E., Ford, J. S., Villalon, D., Barnes, A., Debes, J. D., & Marianelli, L. G. (2019). Evaluation of Scorpion Envenomation by *Tityus trivittatus* in Adults: An Analysis of Variables Related to Severity of Clinical Presentation. *Wilderness Environ Med*, *30*(3), 274-280. <https://doi.org/10.1016/j.wem.2019.05.007>
- Freire-Maia, L., Campos, J., & Amaral, C. (1994). Approaches to the treatment of scorpion envenoming. *Toxicon*, *32*(9), 1009-1014.
- Fukuhara, Y. D., Reis, M. L., Dellalibera-Joviliano, R., Cunha, F. Q., & Donadi, E. A. (2003). Increased plasma levels of IL-1beta, IL-6, IL-8, IL-10 and TNF-alpha in patients moderately or severely envenomed by *Tityus serrulatus* scorpion sting. *Toxicon*, *41*(1), 49-55. [https://doi.org/10.1016/s0041-0101\(02\)00208-8](https://doi.org/10.1016/s0041-0101(02)00208-8)
- Gomes, J. V., Fé, N. F., Santos, H. L. R., Jung, B., Bisneto, P. F., Sachett, A., & de Oliveira Pardal, P. P. (2020). Clinical profile of confirmed scorpion stings in a referral center in Manaus, Western Brazilian Amazon. *Toxicon*, *187*, 245-254.
- Gómez, J. P., Quintana, J. C., Arbeláez, P., Fernández, J., Silva, J. F., Barona, J., & Otero, R. (2010). Picaduras por escorpión *Tityus asthenes* en Mutatá, Colombia: aspectos epidemiológicos, clínicos y toxicológicos. *Biomédica*, *30*(1), 126-139.
- Gómez, J. P., Quintana, J. C., Arbeláez, P., Fernández, J., Silva, J. F., Barona, J., & Otero, R. (2010). [Tityus asthenes scorpion stings: epidemiological, clinical and toxicological aspects]. *Biomédica*, *30*(1), 126-139.
- Hering, S. E., Jurca, M., Vichi, F. L., Azevedo-Marques, M. M., & Cupo, P. (1993). 'Reversible cardiomyopathy' in patients with severe scorpion envenoming by *Tityus serrulatus*: evolution of enzymatic, electrocardiographic and echocardiographic alterations. *Annals of tropical paediatrics*, *13*(2), 173-182.
- Inceoglu, B., Lango, J., Jing, J., Chen, L., Doymaz, F., Pessah, I. N., & Hammock, B. D. (2003). One scorpion, two venoms: pre venom of *Parabuthus transvaalicus* acts as an alternative type of venom with distinct mechanism of action. *Proceedings of the National Academy of Sciences*, *100*(3), 922-927.
- Isbister, G. K., & Bawaskar, H. S. (2014). Scorpion envenomation. *New England journal of medicine*, *371*(5), 457-463.
- Kalapothis, Y., Miranda, K., Pereira, A. H., Witt, A. S. A., Marani, C., Martins, A. P., & Kalapothis, E. (2021). Novel components of *Tityus serrulatus* venom: A transcriptomic approach. *Toxicon*, *189*, 91-104. <https://doi.org/10.1016/j.toxicon.2020.11.001>

- Khattabi, A., Soulaymani-Bencheikh, R., Achour, S., Salmi, L. R., & Group, S. C. E. (2011). Classification of clinical consequences of scorpion stings: consensus development. *Trans R Soc Trop Med Hyg*, 105(7), 364-369. <https://doi.org/10.1016/j.trstmh.2011.03.007>
- Liberati, A., Altman, D. G., Tetzlaff, J., Mulrow, C., Gøtzsche, P. C., Ioannidis, J. P. A., & Moher, D. (2009). The PRISMA statement for reporting systematic reviews and meta-analyses of studies that evaluate health care interventions: explanation and elaboration. *Annals of internal medicine*, 151(4), W65. <https://doi.org/10.7326/0003-4819-151-4-200908180-00136>
- Lira-da-Silva, R. M., Amorim, A. M., & Brazil, T. K. (2000). [Poisonous sting by *Tityus stigmurus* (Scorpiones; Buthidae) in the state of Bahia, Brazil]. *Rev Soc Bras Med Trop*, 33(3), 239-245. <https://doi.org/10.1590/s0037-86822000000300001>
- Lourenço, W. (2008). Parthenogenesis in scorpions: some history-new data. *Journal of Venomous Animals and Toxins including Tropical Diseases*, 14, 19-44.
- Magalhães, M. M., Pereira, M. E., Amaral, C. F., Rezende, N. A., Campolina, D., Bucarechi, F., & Cunha-Melo, J. R. (1999). Serum levels of cytokines in patients envenomed by *Tityus serrulatus* scorpion sting. *Toxicon*, 37(8), 1155-1164. [https://doi.org/10.1016/s0041-0101\(98\)00251-7](https://doi.org/10.1016/s0041-0101(98)00251-7)
- Malaque, C. M. S. A., de Bragança, A. C., Sanches, T. R., Volpini, R. A., Shimizu, M. H., Hiyane, M. I., & Andrade, L. (2015). The role of dexamethasone in scorpion venom-induced deregulation of sodium and water transport in rat lungs. *Intensive Care Medicine Experimental*, 3(1), 1-14.
- Marangoni, S., Ghiso, J., Sampaio, S. V., Arantes, E. C., Giglio, J. R., Oliveira, B., & Frangione, B. (1990). The complete amino acid sequence of toxin TsTX-VI isolated from the venom of the scorpion *Tityus serrulatus*. *Journal of protein chemistry*, 9, 595-601.
- Mazzei de Dávila, C. A., Dávila, D. F., Donis, J. H., de Bellabarba, G. A., Villarreal, V., & Barboza, J. S. (2002). Sympathetic nervous system activation, antivenin administration and cardiovascular manifestations of scorpion envenomation. *Toxicon*, 40(9), 1339-1346. [https://doi.org/10.1016/s0041-0101\(02\)00145-9](https://doi.org/10.1016/s0041-0101(02)00145-9)
- Nascimento, D. G., Rates, B., Santos, D. M., Verano-Braga, T., Barbosa-Silva, A., Dutra, A. A., & Pimenta, A. M. (2006). Moving pieces in a taxonomic puzzle: venom 2D-LC/MS and data clustering analyses to infer phylogenetic relationships in some scorpions from the Buthidae family (Scorpiones). *Toxicon*, 47(6), 628-639.
- Oliveira, F. N., Mortari, M. R., Carneiro, F. P., Guerrero-Vargas, J. A., Santos, D. M., Pimenta, A. M., & Schwartz, E. F. (2013). Another record of significant regional variation in toxicity of *Tityus serrulatus* venom in Brazil: a step towards understanding the possible role of sodium channel modulators. *Toxicon*, 73, 33-46. <https://doi.org/10.1016/j.toxicon.2013.06.021>
- Page, M. J., McKenzie, J. E., Bossuyt, P. M., Boutron, I., Hoffmann, T. C., Mulrow, C. D., & Brennan, S. E. (2021). The PRISMA 2020 statement: an updated guideline for reporting systematic reviews. *Bmj*, 372.
- Pardal, P. P., Ishikawa, E. A., Vieira, J. L., Coelho, J. S., Dórea, R. C., Abati, P. A., & Chalkidis, H. M. (2014). Clinical aspects of envenomation caused by *Tityus obscurus* (Gervais, 1843) in two distinct regions of Pará state, Brazilian Amazon basin: a prospective case series. *J Venom Anim Toxins Incl Trop Dis*, 20(1), 3. <https://doi.org/10.1186/1678-9199-20-3>
- Reis, M. B., Rodrigues, F. L., Lautherbach, N., Kanashiro, A., Sorgi, C. A., Meirelles, A. F., & Ramos, S. G. (2020). Interleukin-1 receptor-induced PGE2 production controls acetylcholine-mediated cardiac dysfunction and mortality during scorpion envenomation. *Nature communications*, 11(1), 1-12.
- Reyes-Lugo, M., & Rodriguez-Acosta, A. (2001). Scorpion envenoming by *Tityus discrepans* Pocock, 1897 in the northern coastal region of Venezuela. *Revista Científica-Universidad del Zulia Facultad de Ciencias Veterinarias División de Investigacion*, 11(5), 412-417.
- Rodrigo, C., & Gnanathanan, A. (2017). Management of scorpion envenoming: a systematic review and meta-analysis of controlled clinical trials. *Systematic reviews*, 6(1), 1-12.
- Román, J. P., García, F., Medina, D., Vásquez, M., García, J., Graham, M. R., & Borges, A. (2018). Scorpion envenoming in Morona Santiago, Amazonian Ecuador: Molecular phylogenetics confirms involvement of the *Tityus obscurus* group. *Acta tropica*, 178, 1-9.
- Santiago, J. J., Dávila, C. A., Davila, D. F., Donis, J. H., & Villaroel, V. (2010). Antiadrenergic rescue therapy with amiodarone in children with severe left ventricular dysfunction secondary to scorpion envenomation. *Arquivos Brasileiros de Cardiologia*, 94, 18-24.
- Shaw, T., Rafferty, P., & Tait, G. (1987). Transient shock and myocardial impairment caused by phaeochromocytoma crisis. *Heart*, 57(2), 194-198.
- Souza, C. M., Vieira, J. R., Souza, J. R., Sales, L. S., & Cunha, L. E. (2012). 169. *Tityus serrulatus* Scorpion Laboratory Breeding and Venom Collection for Antivenom Production and Research. *Toxicon*, 2(60), 182.
- Torrez, P. P., Quiroga, M. M., Abati, P. A., Mascheretti, M., Costa, W. S., Campos, L. P., & França, F. O. (2015). Acute cerebellar dysfunction with neuromuscular manifestations after scorpionism presumably caused by *Tityus obscurus* in Santarém, Pará / Brazil. *Toxicon*, 96, 68-73. <https://doi.org/10.1016/j.toxicon.2014.12.012>
- Zhang, X. G., Wang, X., Zhou, T. T., Wu, X. F., Peng, Y., Zhang, W. Q., & Zhao, J. (2016). Scorpion Venom Heat-Resistant Peptide Protects Transgenic *Caenorhabditis elegans* from β -Amyloid Toxicity. *Front Pharmacol*, 7, 227. <https://doi.org/10.3389/fphar.2016.00227>