

## Included canine in the palate, a surgical challenge: Case report

Canino incluso no palato, um desafio cirúrgico: Relato de caso

Canino incluido en el paladar, un desafío quirúrgico: Informe de un caso

Received: 03/03/2024 | Revised: 03/11/2024 | Accepted: 03/12/2024 | Published: 03/14/2024

### **Andressa Ferreira Martins**

ORCID: <https://orcid.org/0009-0002-6002-8497>

Universidade Paulista, Brasil

E-mail: [andressaf.martins@hotmail.com](mailto:andressaf.martins@hotmail.com)

### **Lívia Prates Soares**

ORCID: <https://orcid.org/0000-0003-4931-1195>

Escola Baiana de Medicina e Saúde Pública, Brasil

E-mail: [liviapsoares@hotmail.com](mailto:liviapsoares@hotmail.com)

### **Mayara Rodrigues de Lira**

ORCID: <https://orcid.org/0009-0007-2277-6335>

Centro Universitário Alfredo Nasser, Brasil

E-mail: [mayararlira19@gmail.com](mailto:mayararlira19@gmail.com)

### **Amanda Barreira Silva**

ORCID: <https://orcid.org/0009-0005-0158-8621>

Centro Universitário Alfredo Nasser, Brasil

E-mail: [odonto.amandabarreira@gmail.com](mailto:odonto.amandabarreira@gmail.com)

### **Daiany de Mendonça Silva**

ORCID: <https://orcid.org/0009-0003-3411-3978>

Centro Universitário Alfredo Nasser, Brasil

E-mail: [daiany.m.s14@hotmail.com](mailto:daiany.m.s14@hotmail.com)

### **Caroline Lemos Araújo Deveras Guimarães**

ORCID: <https://orcid.org/0009-0005-0746-0215>

Universidade UNIME, Brasil

E-mail: [carol.deveras@gmail.com](mailto:carol.deveras@gmail.com)

### **Maylon Luciano Garcia Barbosa**

ORCID: <https://orcid.org/0009-0006-0187-8191>

São Leopoldo Mandic, Brasil

E-mail: [maylonlgarcia@gmail.com](mailto:maylonlgarcia@gmail.com)

### **Abstract**

**Introduction:** The impaction of maxillary canines is a frequent occurrence, especially in the palatal region, even when there is sufficient space for their alignment in the dental arch. It can be caused by general or local factors, and its diagnosis should be made through clinical, radiographic and tomographic examinations. **Aim:** The aim of this study was to describe a clinical case of an impacted canine that had previously been unsuccessfully attempted to be orthodontically pulled. **Clinical case report:** A 19-year-old female patient was referred for extraction of an impacted element 13 on the palate, after attempted traction for two years, carried out as a prophylactic measure against resorption of adjacent dental elements. Careful removal was carried out with the aid of blood products for a better post-operative prognosis. **Conclusion:** Early diagnosis of dental inclusions is important to enable traction and prevent loss of units. However, when the inclusion does not allow the tooth to be used, it is important to remove it in a less invasive way and with the better possible post-operative outcome for the patient.

**Keywords:** Surgery, oral; Tooth, impacted; Tooth extraction; Platelet-Rich Fibrin; Bone transplantation.

### **Resumo**

**Introdução:** A impactação de caninos superiores é um acontecimento frequente, especialmente na região palatina, ainda que na presença de espaço suficiente para o seu alinhamento na arcada dentária. Pode ser causada por fatores de ordem geral ou local, sendo que seu diagnóstico deve ser realizado por meio de exames clínicos, radiográficos e tomográficos. **Objetivo:** O presente trabalho teve como objetivo descrever um caso clínico de canino impactado que já havia sofrido a tentativa de tracionamento ortodôntico prévio, sem sucesso. **Relato de caso clínico:** Paciente 19 anos, gênero feminino, com indicação de exodontia do elemento 13 impactado no palato, após tentativa de tracionamento durante dois anos, realizado como medida profilática à reabsorção dos elementos dentários adjacentes. A remoção cuidadosa foi realizada com auxílio de hemoderivados para um melhor prognóstico pós-operatório. **Conclusão:** Importante o diagnóstico precoce das inclusões dentárias para permitir o tracionamento e evitar a perda das unidades.

Porém quando a inclusão não possibilita o aproveitamento do dente, a importância recai na retirada de maneira menos invasiva e com um melhor pós-operatório possível para o paciente.

**Palavras-chave:** Cirurgia oral; Dente impactado; Extração dentária; Fibrina Rica em Plaquetas; Enxerto ósseo.

### Resumen

**Introducción:** La impactación de caninos maxilares es una ocurrencia frecuente, especialmente en la región palatina, aun cuando exista espacio suficiente para su alineamiento en la arcada dentaria. Puede ser causada por factores generales o locales, y su diagnóstico debe ser hecho a través de exámenes clínicos, radiográficos y tomográficos. **Objetivo:** El objetivo de este estudio fue describir un caso clínico de un canino impactado que previamente se había intentado extraer ortodóncicamente sin éxito. **Caso clínico:** Una paciente de 19 años de edad fue remitida para la extracción de un elemento 13 impactado en el paladar, tras un intento de tracción durante dos años, realizado como medida profiláctica contra la reabsorción de elementos dentales adyacentes. Se realizó una extracción cuidadosa con ayuda de hemoderivados para un mejor pronóstico postoperatorio. **Conclusión:** El diagnóstico precoz de las inclusiones dentales es importante para permitir la tracción y evitar la pérdida de las unidades. Sin embargo, cuando la inclusión no permite utilizar el dente, es importante extraerla de forma menos invasiva y con el mejor resultado postoperatorio posible para el paciente.

**Palabras clave:** Cirugía bucal; Diente impactado; Extracción dental; Fibrina Rica en Plaquetas; Trasplante óseo.

## 1. Introduction

Permanent maxillary canines play an important role in establishing and maintaining the form and function of the dentition, and their presence in the dental arch is fundamental for establishing a balanced dynamic occlusion, as well as aesthetics and facial harmony (Niklas et al., 2022; Cruz, 2019; Cappellette et al., 2008). Maxillary canines are the second teeth with the greatest tendency to become impacted, preceded by mandibular third molars (Pant et al., 2021; Baidas et al., 2022). In addition, epidemiological studies show that the incidence of impaction is higher in females and in the unilateral region. In the management of impacted canines, planning should be multidisciplinary, with assessment by the orthodontist, general dental surgeon and oral and maxillofacial surgeon, with the former playing an extremely important role in defining treatment options (Alberto, 2020). The types of management can be: preservation of the element, interception of positioning, surgical exposure with or without orthodontic alignment, autotransplantation and extraction of the impacted tooth (Afonso et al., 2023).

Clinical examination, together with imaging tests, are essential for diagnosing impacted teeth and assessing their position and proximity to other tissues, providing an accurate diagnosis, interdisciplinary planning and an expected prognosis to be presented to the patient (Almeida et al., 2021). In addition, according to Cappellette, et al (2008), early diagnosis can prevent a series of complications that an impacted canine can cause, such as ankylosis of the element itself, infectious processes and root resorption in adjacent teeth.

In radiographic investigation, it is necessary to observe some of the factors that the impacted tooth presents: its position in relation to the dental arch in the three planes of space, its relationship with adjacent teeth and noble structures, the shape and size of the tooth and the type of bone that surrounds it (Grisar et al., 2021). To this end, according to Manzi FR et al., 2011, computed tomography can show not only the location of the impacted canine in the buccal-palatal direction, but also its relationship with adjacent structures, especially if its crown is closely related to the incisor roots.

Extraction is an option for impacted teeth that cannot be moved orthodontically, in which case the space should be occupied by the premolar or a prosthesis/implant. Several factors should be considered, such as: direction and position of the unerupted tooth, degree of development of the root apex, eruption space, existence of a supernumerary tooth and presence of pathologies. (Bedoya & Park, 2009).

The aim of this study is to describe a clinical case of extraction of an impacted canine, after 2 years of attempted traction, with subsequent bone grafting with blood products and biomaterial.

## 2. Methodology

This is a clinical experience report based on scientific evidence. The study is based on the experience at a postgraduate teaching institution, after assessing feasibility, literature review, surgical indication, as well as the history of previously instituted treatments reported by the patient (Estrela, 2018). The report was developed in a fluid way, with details aimed at the reader's better visualization, based on CNS/CONEP resolution 466/2012, as well as the principles of the Research Ethics Committee.

### Case report

A patient, female, 17 years old, came to an educational institution in Goiânia seeking orthodontic treatment. After clinical assessment and complementary examinations, the presence of an impacted canine was found (unit 13). Based on the indications for traction, the patient was referred for orthodontic button bonding surgery. After about two years of trying, the traction was unsuccessful and the patient was then referred to the minor oral surgery course to have the element extracted.

After an updated Cone Beam CT scan (Figures 1A and 1B), it was possible to identify the proximity of the unit to the roots of the upper right lateral incisor and the ipsilateral first premolar. With a view to preserving the bone structure for the future installation of a dental implant, extraction was planned with immediate bone grafting combined with L-PRF membranes.

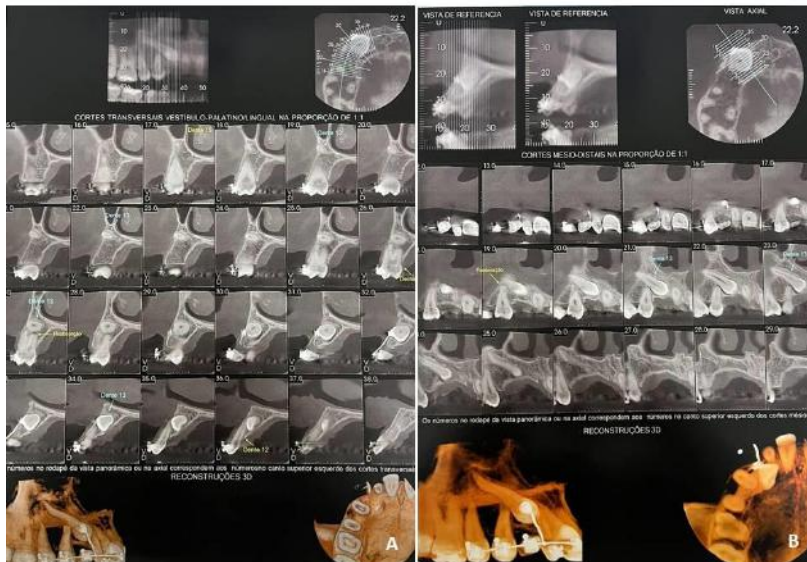
The patient came to the educational institution for the surgical procedures. She was medicated 60 minutes before the procedure with 02 tablets of Amoxicillin 500mg, 01 tablet of Trometamol Ketorolac 10 mg (sublingually) and 02 tablets of Dexamethasone 4 mg (orally). Blood was collected from the patient's left arm to obtain L-PRF membranes (Figures 2A and 2B) by centrifuging at 2500 rpm for 20 minutes in a centrifuge (Kasv<sup>®</sup> São José dos Pinhais - PR). The entire procedure was carried out in an outpatient setting under local anesthesia with 4% articaine and 1:100,000 epinephrine (DFL<sup>®</sup> - Rio de Janeiro - RJ/Brazil) using an infiltrative technique in the region of the bottom of the vestibule for anesthesia of the anterior superior alveolar nerve. An incision was made with a 15C blade (Solidor<sup>®</sup> - Osasco - SP/Brazil) intrasulcularly involving teeth 11, 12, passing through the edge of tooth 13 and extending to the mesial aspect of tooth 14, where a relaxing incision was made distally to avoid compromising the aesthetics of the smile. The tissue was peeled off using a Molt #9 peeler until the area where the crown of the 13th tooth was located was exposed, which was easily visualized by the presence of the orthodontic button that was still attached to the crown under the mucosa (Figure 3A). With the aid of a 702 carbide surgical drill for high rotation, an osteotomy was performed around the entire crown, with subsequent odontosection in 4 pieces (horizontally and vertically) which were then removed with a Seldin Straight Lever.

As it was distalized, the root of the unit to be removed was in close contact with the root of tooth 14, which required careful luxation and ended up limiting access to the remnant that was still in the alveolus. After a delicate osteotomy for buccal access, the root was avulsed using a straight seldin lever. The socket was cleaned with a Lucas curette, irrigated with plenty of saline solution (Figure 3B) and then filled with a two-phase calcium phosphate-based synthetic bone graft (FGM<sup>®</sup> Nanosynt Joinville - SC/Brazil) combined with L-PRF membranes (Figures 3C and 3D) to seal the socket. The area was sutured with single stitches using 5-0 Nylon thread (Ethicon<sup>®</sup> - São Paulo/Brazil).

The post-operative medication prescribed was 01 tablet of Amoxicillin 500mg every 8 hours for 07 days, 01 tablet of Dexamethasone 4mg every 24 hours for 03 days (orally) and 01 tablet of Trometamol Ketorolac 10mg (sublingually) in case of pain.

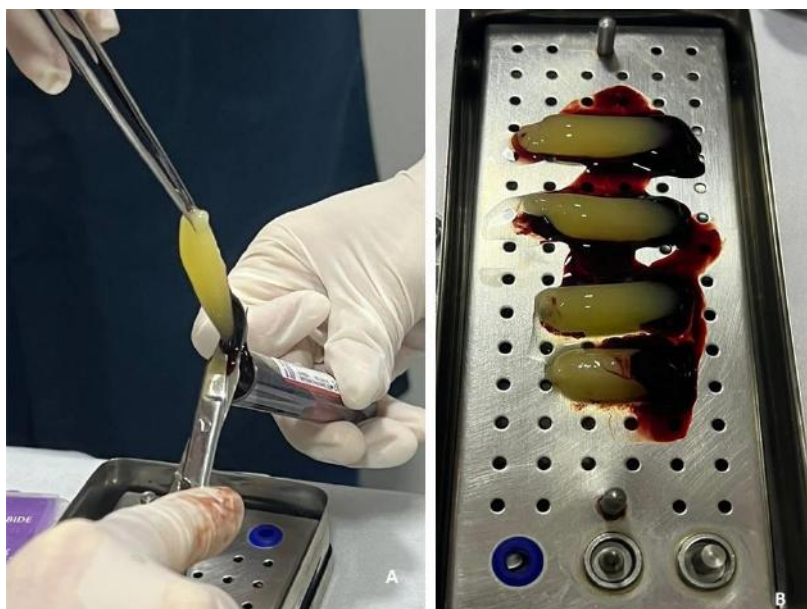In order to preserve the patient's aesthetics, the extraction of tooth 53 will not be carried out until it is possible to install a dental implant in the region of tooth.

**Figure 1** - Figure 1A and 1B: Cone Beam CT scan showing impacted tooth 13 and its relationship with neighboring teeth. The use of tomography was essential in identifying the best surgical approach, minimizing the risk of injury to adjacent structures.



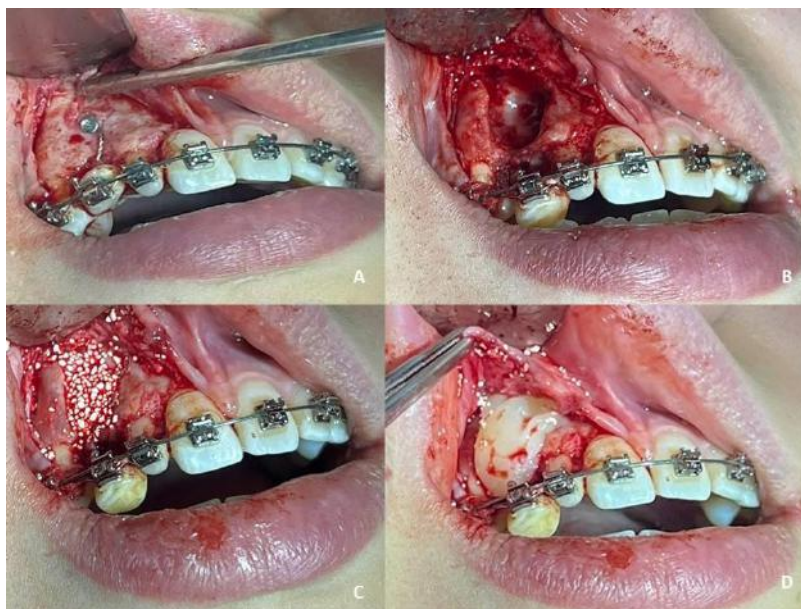
Source: Authors (2023).

**Figure 2** - Figura 2A and 2B - L-PRF membranes made from blood collected from the patient herself. The image illustrates the quality of the membranes that were obtained.



Source: Authors (2023).

**Figure 3** - Figure 3A - Region with surgical access, allowing visualization of the orthodontic button that had been installed during the traction attempt. Figure 3B - Empty socket after extraction of element 13. Figures 3C and 3D - Gap filled with biomaterial and covered with L-PRF membrane. The sequentially arranged images illustrate the entire surgical step by step, with good visualization and safety during the procedure.



Source: Authors (2023).

### 3. Results and Discussion

It is necessary to consider the complications that an impacted tooth can cause in order to decide whether to continue the orthodontic traction process or indicate extraction. Modern diagnostic tests and an appropriate therapeutic approach are of paramount importance (Grybieniė et al., 2019). Computed tomography was of paramount importance throughout the planning and execution process, allowing us to see the three-dimensional positioning of the impacted tooth, as well as the possible complications that its permanence could bring.

Balasupramaniam MT, Anitha A, Manovijay B, et al in 2023 discussed a series of cases of orthodontic manipulation of impacted canines, considering that some techniques may show better results, but that the possibility of failure should always be considered. Given the unsuccessful attempt at orthodontic traction for two years, extraction proved to be the best treatment plan for the case in question.

As the canine plays an important role, both functionally and aesthetically, and is considered a pillar of the smile, extraction of this impacted element can also result in complications to the alveolar bone structure that should be taken into consideration, drawing attention to the need for bone regeneration using bone substitutes (Moreno-Rodríguez et al., 2021). The use of bone grafting combined with blood products provides better bone regeneration and preservation of the alveolus post-exodontia.

To replace these teeth, dental implants are a popular and reliable method and grafting has been used to restore bone volume and enable the installation of implants. In this scenario, PRF, in addition to bone substitutes, is an autologous fibrin matrix used to improve bone regeneration (Lee et al., 2012). This post-extraction care aims to allow the future implant to be installed in its ideal three-dimensional position, with minimal damage to the remaining bone structure.

The use of L-PRF is actually tissue manipulation through the transformation of blood into a natural biomaterial, and then its use for in vivo purposes. With L-PRF, surgeons take control of the blood clot and can therefore improve the early

stages of healing. Logically, as natural bleeding is the key to efficient bone healing, the use of optimized blood clots can improve the natural healing process, either alone or in association with a bone substitute. L-PRF is very stable and homogeneous, since it has been prepared outside the surgical site, and this biomaterial is very easy to handle and place at the right time and in the right place. The L-PRF technique is simple, quick and inexpensive and is therefore perfectly suited to everyday clinical practice (Liu et al., 2019; Amaral et al., 2020; Damsaz et al., 2020; Barbosa et al., 2020; Melo-Ferraz et al., 2021).

The fact that the patient's deciduous tooth was not removed until the dental implant could be installed meant that the aesthetics were not compromised during the period of osseointegration of the graft and the occlusal/aesthetic adjustments that will still have to be made by orthodontics. The tooth extraction combined with the alveolar preservation that was carried out in our clinical case played a key role in improving the prognosis from a bone point of view, enabling the proper three-dimensional positioning of the future implant, which will make a significant aesthetic and functional contribution to the treatment.

#### 4. Conclusion

Impacted maxillary canines are not uncommon, with a predilection for females. A good clinical assessment and imaging tests with the correct indication are essential for creating and developing an assertive treatment plan. Early detection of impacted elements such as this is essential to prevent damage to adjacent teeth, and it is important to emphasize the need to draw up a treatment plan that allows the patient to be rehabilitated after extraction.

#### References

- Afonso, Á. de O., Silva, A. M. S., Araújo, F. R. da C., Costa, E. P., Silva, E. da, Araujo, J. G. de, Galisse, S. S., Dourado, Y. M., Silva, P. R. L., & Müller, I. (2023). Exposição cirúrgica de dentes impactados: uma revisão da literatura. *Research, Society and Development*, 12(1), e13012139628–e13012139628. <https://doi.org/10.33448/rsd-v12i1.39628>
- Alberto, P. L. (2020). Surgical Exposure of Impacted Teeth. *Oral and Maxillofacial Surgery Clinics of North America*, 32(4), 561–570. <https://doi.org/10.1016/j.joms.2020.07.008>
- Almeida, Rocha, A. T. M. da, Barboza, A. D., Fialho, P. V., & Vieira, T. S. L. S. (2021). Tratamento de dentes inclusos em proximidade a cavidade nasal e seio maxilar: relato de caso. *Rev. Odontol. Araçatuba (Impr.)*, 33–37. <https://pesquisa.bvsalud.org/portal/resource/pt/biblio-1252851>
- Amaral Valladão, C. A., Freitas Monteiro, M., & Joly, J. C. (2020). Guided bone regeneration in staged vertical and horizontal bone augmentation using platelet-rich fibrin associated with bone grafts: a retrospective clinical study. *International Journal of Implant Dentistry*, 6(1). <https://doi.org/10.1186/s40729-020-00266-y>
- Baidas, L., Alshihah, N., Rwan Alabdulaly, & Mutaieb, S. (2022). Severity and Treatment Difficulty of Impacted Maxillary Canine among Orthodontic Patients in Riyadh, Saudi Arabia. *International Journal of Environmental Research and Public Health*, 19(17), 10680–10680. <https://doi.org/10.3390/ijerph191710680>
- Balassupramaniam, M. T., Anitha, A., Manovijay, B., & Ravi, S. (2023). Various surgical methods of impacted maxillary canine exposure: A case series. *Journal of Indian Society of Periodontology*, 27(2), 212–215. [https://doi.org/10.4103/jisp.jisp\\_42\\_22](https://doi.org/10.4103/jisp.jisp_42_22)
- Barbosa, I. M. G., Albuquerque, G. G., & Amorim, J. S. (2020). L-PRF como tratamento de pacientes com osteonecrose: Revista Cathedral, 2(1). <http://cathedral.ojs.galoa.com.br/index.php/cathedral/article/view/116>
- Bedoya, M. M., & Park, J. H. (2009). A Review of the Diagnosis and Management of Impacted Maxillary Canines. *The Journal of the American Dental Association*, 140(12), 1485–1493. <https://doi.org/10.14219/jada.archive.2009.0099>
- Cappellette, M., Cappellette Jr., M., Fernandes, L. C. M., Oliveira, A. P. de, Yamamoto, L. H., Shido, F. T., & Oliveira, W. C. de. (2008). Caninos permanentes retidos por palatino: diagnóstico e terapêutica: uma sugestão técnica de tratamento. *Revista Dental Press de Ortodontia E Ortopedia Facial*, 13, 60–73. <https://doi.org/10.1590/S1415-54192008000100008>
- Cruz, R. M. (2019). Orthodontic traction of impacted canines: Concepts and clinical application. *Dental Press Journal of Orthodontics*, 24(1), 74–87. <https://doi.org/10.1590/2177-6709.24.1.074-087.bbo>
- Damsaz, M., Castagnoli, C. Z., Eshghpour, M., Alamdari, D. H., Alamdari, A. H., Noujeim, Z. E. F., & Haidar, Z. S. (2020). Evidence-Based Clinical Efficacy of Leukocyte and Platelet-Rich Fibrin in Maxillary Sinus Floor Lift, Graft and Surgical Augmentation Procedures. *Frontiers in Surgery*, 7. <https://doi.org/10.3389/fsurg.2020.537138>

Estrela, C. (2018). Metodologia Científica: Ciência, Ensino, Pesquisa. In Google Books. Artes Medicas. <https://books.google.com.br/books?hl=pt-BR&lr=&id=67VIDwAAQBAJ&oi=fnd&pg=PR1&dq=Estrela>

Grisar, K., Luyten, J., Preda, F., Martin, C., Hoppenreijts, T., Politis, C., & Jacobs, R. (2021). Interventions for impacted maxillary canines: A systematic review of the relationship between initial canine position and treatment outcome. *Orthodontics & Craniofacial Research*, 24(2), 180–193. <https://doi.org/10.1111/ocr.12423>

Grybienė, V., Juozėnaitė, D., & Kubiliūtė, K. (2019). Diagnostic methods and treatment strategies of impacted maxillary canines: A literature review. *Stomatologija*, 21(1), 3–12. <https://pubmed.ncbi.nlm.nih.gov/31619657/>

Lee, J.-W., Kim, S.-G., Kim, J.-Y., Lee, Y.-C., Choi, J.-Y., Dragos, R., & Rotaru, H. (2012). Restoration of a peri-implant defect by platelet-rich fibrin. *Oral Surgery, Oral Medicine, Oral Pathology and Oral Radiology*, 113(4), 459–463. <https://doi.org/10.1016/j.tripleo.2011.03.043>

Liu, Y., Sun, X., Yu, J., Wang, J., Zhai, P., Chen, S., Liu, M., & Zhou, Y. (2019). Platelet-Rich Fibrin as a Bone Graft Material in Oral and Maxillofacial Bone Regeneration: Classification and Summary for Better Application. *BioMed Research International*, 2019, 1–16. <https://doi.org/10.1155/2019/3295756>

Manzi, F. R., Ferreira, E. de F., Rosa, T. Z. e S., Valerio, C. S., & Peyneau, P. D. (2011). Uso da Tomografia Computadorizada para Diagnóstico de Caninos Inclusos. *Revista Odontológica Do Brasil Central*, 20(53). <https://doi.org/10.36065/robrac.v20i53.532>

Melo-Ferraz, A., Coelho, C., Miller, P., Criado, M. B., & Monteiro, M. C. (2021). Platelet activation and antimicrobial activity of L-PRF: a preliminary study. *Molecular Biology Reports*. <https://doi.org/10.1007/s11033-021-06487-7>

Moreno-Rodríguez, J. A., Guerrero-Gironés, J., Rodríguez-Lozano, F. J., & Pecci-Lloret, M. R. (2021). Immediate Post-Extraction Short Implant Placement with Immediate Loading and without Extraction of an Impacted Maxillary Canine: Two Case Reports. *Materials*, 14(11), 2757. <https://doi.org/10.3390/ma14112757>

Niklas Schwefer, Freitag-Wolf, S., Meyer, G., & Kern, M. (2022). Investigation of the esthetic perception of different canine parameters. *Clinical Oral Investigations*, 26(12), 6973–6983. <https://doi.org/10.1007/s00784-022-04651-2>

Pant, B. D., Rajbhandari, A., Pradhan, R., Bajracharya, M., Manandhar, P., Maharjan, S., Pun, D. B., & Sah, B. K. (2021). Impacted Canine in Orthodontic Patients of a Tertiary Care Hospital: A Descriptive Cross-sectional Study. *JNMA: Journal of the Nepal Medical Association*, 59(244), 1215–1218. <https://doi.org/10.31729/jnma.6545>