

Orthodontic management of bilateral maxillary canine impaction in skeletal Class I malocclusion: A case report

Manejo ortodôntico da impactação bilateral de caninos maxilares em malocclusão esquelética Classe

I: Relato de caso

Manejo ortodôntico de la impactación bilateral de caninos maxilares en maloclusión esquelética

Clase I: Informe de caso

Received: 03/16/2024 | Revised: 03/22/2024 | Accepted: 03/23/2024 | Published: 03/26/2024

Orlando Motohiro Tanaka

ORCID: <https://orcid.org/0000-0002-1052-7872>
Pontifícia Universidade Católica do Paraná, Brazil
E-mail: tanakaom@gmail.com

Gil Guilherme Gasparello

ORCID: <https://orcid.org/0000-0002-8955-6448>
Pontifícia Universidade Católica do Paraná, Brazil
E-mail: gilguilhermeg@hotmail.com

Sergio Luiz Mota-Júnior

ORCID: <https://orcid.org/0000-0003-3601-8264>
Juiz de Fora Federal University, Brazil
Email: sergiomotajr_orto@yahoo.com.br

Rafael Bordin Wolanski

ORCID: <https://orcid.org/0000-0002-3273-5584>
Pontifícia Universidade Católica do Paraná, Brazil
Email: rafaelbordin23@gmail.com

Vinícius Obal

ORCID: <https://orcid.org/0009-0002-0630-8404>
Pontifícia Universidade Católica do Paraná, Brazil
Email: viniciusobal1@gmail.com

Grissel Mayra Lázaro

ORCID: <https://orcid.org/0009-0004-0076-1341>
Pontifícia Universidade Católica do Paraná, Brazil
Email: grissellazaro@gmail.com

Jacqueline de Almeida Antunes

ORCID: <https://orcid.org/0009-0001-3216-0426>
Private practice, Brazil
Email: jacquelinealmant@gmail.com

Mohamad Jamal Bark

ORCID: <https://orcid.org/0000-0002-9862-0894>
Pontifícia Universidade Católica do Paraná, Brazil
Email: mohamadbark@hotmail.com

Abstract

Introduction: Impacted maxillary canines can assume a diverse array of three-dimensional positions, contributing to the complexity of orthodontic treatment. **Objective:** This article aims to discuss the case of a skeletal Class I patient with a mesofacial pattern, a convex facial profile and maxillary incisor protrusion, presenting with Class I malocclusion, normal overjet, and a mild overbite, along with bilateral impaction of the permanent maxillary canines. Available treatment options included orthodontic traction of the impacted canines, extraction of the primary canines, either preserving or extracting the impacted canines, or extracting all canines and closing the posterior space. Ankylosis of the right canine was a consideration. The treatment that was implemented involved closed exposition, attachment bonding, and traction of the right canine into the occlusal line using a full fixed appliance. **Results:** The left canine was extracted, and the primary canine was retained as a placeholder for future prosthetic implantation after growth cessation. After 35 months, the right canine was successfully positioned in the occlusal line, maintaining the left primary canine and the original good intercuspatation. **Conclusion:** The prosthetic rehabilitation with an implant-supported prosthesis on the left side was successful, as confirmed at the 3-year and 4-month follow-up.

Keywords: Orthodontics; Impacted canine; Malocclusion; Ankylosis.

Resumo

Introdução: Caninos maxilares impactados podem assumir uma variedade de posições tridimensionais, contribuindo para a complexidade do tratamento ortodôntico. **Objetivo:** Este artigo visa discutir o caso de um paciente com Classe I esquelética, padrão mesofacial, perfil facial convexo e protrusão dos incisivos maxilares, apresentando maloclusão Classe I, *overjet* normal e leve sobremordida, juntamente com a impaction bilateral dos caninos maxilares permanentes. As opções de tratamento disponíveis incluíam a tração ortodôntica dos caninos impactados, extração dos caninos primários, preservação ou extração dos caninos impactados, ou extração de todos os caninos e fechamento do espaço posterior. A anquilose do canino direito foi uma consideração. O tratamento implementado envolveu exposição fechada, colagem de *attachments* e tração do canino direito para a linha oclusal usando um aparelho fixo completo. **Resultados:** O canino esquerdo foi extraído e o canino primário foi mantido como um espaço reservado para futura implantação protética após a cessação do crescimento. Após 35 meses, o canino direito foi posicionado com sucesso na linha oclusal, mantendo o canino primário esquerdo e a boa intercuspidação original. **Conclusão:** A reabilitação protética com uma prótese suportada por implante do lado esquerdo foi bem-sucedida, conforme confirmado no acompanhamento de 3 anos e 4 meses.

Palavras-chave: Ortodontia; Dente canino; Maloclusão; Anquilose.

Resumen

Introducción: Los caninos maxilares impactados pueden adoptar una amplia variedad de posiciones tridimensionales, lo que contribuye a la complejidad del tratamiento ortodôntico. **Objetivo:** Este artículo tiene como objetivo discutir el caso de un paciente con Clase I esquelética, patrón mesofacial, perfil facial convexo y protrusión de incisivos maxilares, presentando maloclusión de Clase I, *overjet* normal y una leve sobremordida, junto con la impactación bilateral de los caninos maxilares permanentes. Las opciones de tratamiento disponibles incluyeron la tracción ortodôntica de los caninos impactados, extracción de los caninos primarios, preservación o extracción de los caninos impactados, o la extracción de todos los caninos y el cierre del espacio posterior. La anquilosis del canino derecho fue una consideración. El tratamiento implementado involucró la exposición cerrada, la colocación de adhesivos y la tracción del canino derecho hacia la línea oclusal utilizando un aparato fijo completo. **Resultados:** Se extrajo el canino izquierdo y se retuvo el canino primario como un espacio reservado para la futura implantación protésica después del cese del crecimiento. Después de 35 meses, el canino derecho se posicionó exitosamente en la línea oclusal, manteniendo el canino primario izquierdo y la buena intercuspidação original. **Conclusión:** La rehabilitación protésica con una prótesis soportada por implante en el lado izquierdo fue exitosa, como se confirmó en el seguimiento de 3 años y 4 meses.

Palabras clave: Ortodoncia; Diente canino impactado; Maloclusión; Anquilosis.

1. Introduction

Tooth impaction is defined as the failure of a tooth to emerge from the bone at the expected time of eruption (Rimes et al., 1997). This condition frequently affects maxillary canines, which are the second most commonly impacted teeth after the third molars (Yan et al., 2015). Maxillary canines are especially significant due to their critical role in both aesthetics and function (Alqerban et al., 2011).

Early diagnosis and intervention, particularly during the mixed dentition phase, can significantly reduce treatment duration, costs, and the need for more complex procedures later (Manne et al., 2012). The initial diagnosis is primarily clinical, with indicators of impaction including delayed eruption of the permanent canine, prolonged retention of deciduous canines past 14-15 years, absence of the labial canine bulge, presence of a palatal bulge, and abnormal migration or distal tipping of the lateral incisors (Bishara, 1992).

Treating impacted canines, especially those in high or horizontal positions, poses a challenge due to difficult surgical access and complex eruption paths (Grisar et al., 2022). These cases are more often palatal and predominantly affect females (Sacredoti & Baccetti, 2004). Impacted canines not only present functional and aesthetic concerns but can also induce root resorption in adjacent teeth (Bishara, 1992).

A crucial aspect of treatment planning is the accurate assessment of the canine's position and orientation, which is best achieved through three-dimensional CBCT imaging. This technique provides a comprehensive view of the tooth's relation to adjacent structures (Alqerban et al., 2011).

Treatment options for impacted canines include early interceptive treatment (Mathews & Kokich, 2013), and surgical exposure with or without orthodontic traction and alignment. In more complex cases, autotransplantation of the permanent canine (Grisar et al., 2019) or apicotomy in cases of ankylosis or dilacerated roots might be necessary (Araujo et al., 2013).

When the prognosis for an impacted canine is poor, extraction is often the recommended course of action. It's crucial for patients to be aware of potential treatment failures and the likelihood of extended treatment times as part of informed consent (Becker et al., 2010). Managing impacted canines typically requires a multidisciplinary approach, demanding effective communication among clinicians and with the patient, particularly in differentiating between buccal and palatal impactions and choosing the appropriate attachment for orthodontic force application (Tanaka et al., 2014).

The purpose of this clinical case report is to describe the treatment approach for a patient with Angle Class I malocclusion and bilateral maxillary canine impactions.

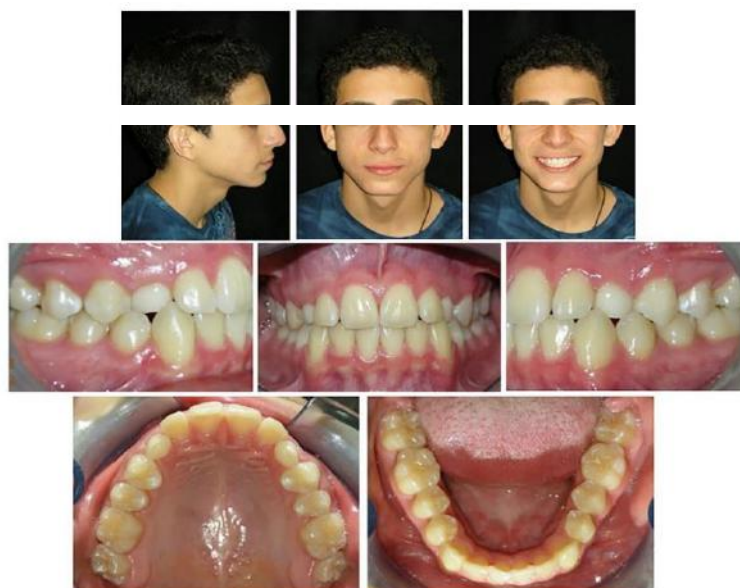2. Methodology

This clinical experience, as reported by Estrela (2018), aims to thoroughly investigate and understand reality for the development of technical-scientific knowledge, according to Coimbra and Martins (2013). It is a qualitative study, as described by Gil (2002). This case report, grounded in the literature and derived from private practice, explores a unique case through a qualitative action research approach. It emphasizes data collection and interpretation, adhering to ethical standards and securing patient consent. The patient provided informed consent, authorizing the use of their images and data for any purpose.

3. Case Report

A 13-year-old male patient sought an orthodontist on the recommendation of his general practitioner. He was in good overall health with no systemic alterations. He presented with a skeletal Class I and Class I malocclusion, with an overjet within normal limits and a mild overbite. White spots were identified in the mesial region of the maxillary second premolars. The deciduous maxillary canines were aligned with the incisors, showing abrasion at the tips. There was slight crowding in the mandibular anterior region. A mild gingival recession was also observed in the mandibular canines (Figure 1).

Figure 1 - Pretreatment facial and intraoral photographs. The maxillary arch is slightly narrow in the bicuspid area, while the mandibular arches display good morphology. Both maxillary deciduous canines are present, yet the smile line remains pleasing.

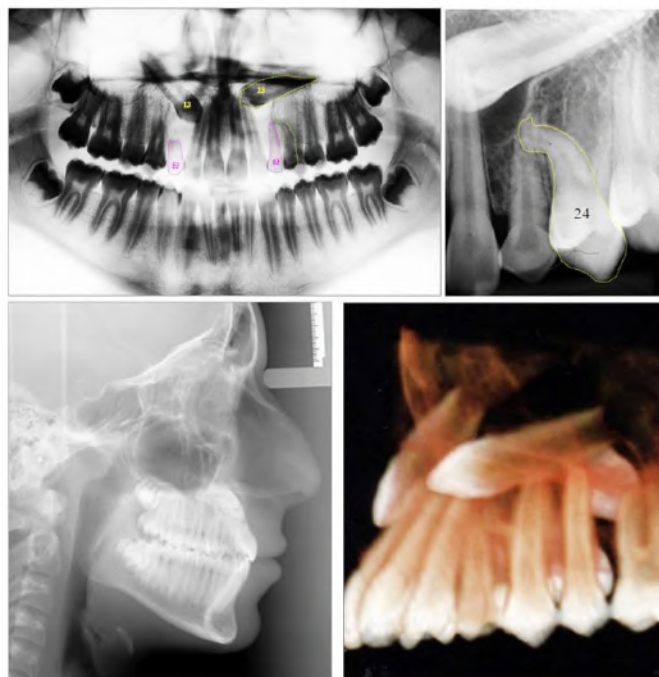


Source: Authors (2024).

The panoramic radiograph revealed mixed dentition with prolonged retention of the deciduous maxillary canines. The right canine exhibited approximately two-thirds root resorption, while the left canine's root remained intact. Presence of the bulb of the third molars. The permanent maxillary canines were impacted, with the left canine displaying a more pronounced horizontal position.

Radiolucent areas were visible in the radiographic image, suggesting potential early caries in the left lower second molars and in the first molars raising suspicions of possible early caries in the left lower second molars and in the first molars. Additionally, a root dilaceration was also identified on the palatal root of the left maxillary first premolar (Figure 2).

Figure 2 - Pretreatment panoramic, cephalometric, periapical radiographs, and CBCT images are presented. The right and left canines are horizontally positioned, with the left one situated between the roots of the bicuspid. The first bicuspid exhibits a dilacerated palatal root. The lower third of the face displays a favorable profile.



Source: Authors (2024).

The main objective of the orthodontic treatment was to align and level the teeth, as well as to restore or close the spaces resulting from the impacted maxillary canines. It also included improving the esthetics and function of the occlusion and maintenance the facial harmony. Ultimately, the treatment aimed to reach a stable occlusion, optimizing oral hygiene and long-term stability, with or without the presence of the maxillary canines in the occlusal line.

Based on the clinical and radiographic examinations, orthodontic treatment with a full fixed appliance was indicated, and the following treatment alternatives were considered:

The first alternative would be to attempt orthodontic traction of the maxillary canines, involving space recovery, surgical exposure, and attachment of accessories to the canines to pull them into the occlusal line.

The second alternative would be the extraction of the right deciduous canine with advanced resorption, and try to pull the permanent canine into place. It also included the extraction of the horizontally and transversally positioned permanent left canine, maintaining the left deciduous canine without resorption.

The third alternative would involve extracting both impacted teeth and preserving the deciduous teeth, re-shaping them with composite to mimetize the permanent canines. And rehabilitation with an implant-supported prosthesis after the cessation of growth.

The fourth alternative was the extraction of both impacted canines and deciduous teeth and closing the resultant space by mesializing all posterior teeth. Waiting until adulthood for rehabilitation with implants in the canines' positions or between the premolars, or between the second premolar and the first molar.

It was important to consider the possibility that the impacted permanent canines, like any other tooth, might not move even when subjected to orthodontic forces due to ankylosis. In such a case, the best clinical course of action would be determined and would require a modification of the initial planning if the alternative was the traction of the canines.

The root dilaceration of the left maxillary first premolar could complicate the traction of the left canine, as well as the movement of the maxillary first premolar to the mesial position in case of space closure. Moreover, the presence of root dilaceration could compromise rehabilitation with an implant-supported prosthesis in the canine's location.

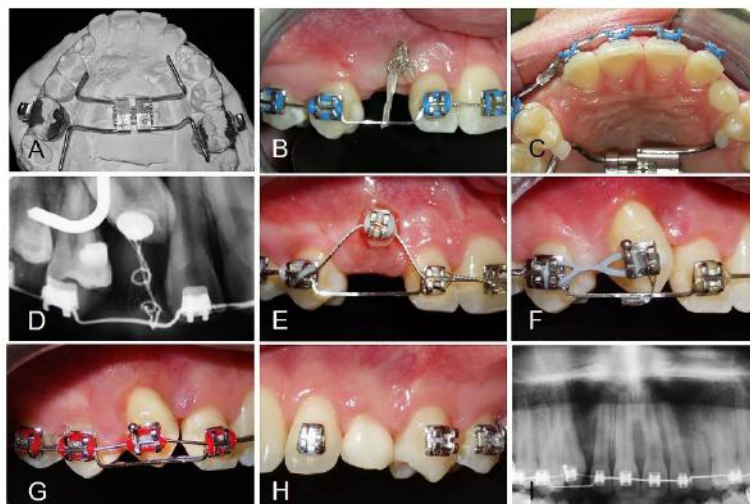
The explanation that prolonged maintenance of deciduous teeth implies an unpredictable possibility of physiological root resorption of that tooth, even in the absence of orthodontic movement.

After discussion with the parents, all alternatives were clearly explained, discussing the advantages and disadvantages of each, and the second alternative was chosen.

In the first stage of treatment, a HYRAX type palatal expander was installed for rapid maxillary expansion (RME) (Figure 3), adjusted at a rate of 2/4 of a turn per day for 13 days. The appliance was maintained for 6 months to stabilize the achieved expansion.

This was followed by the installation of a standard Edgewise fixed appliance, 0.022" slot (Morelli, Jundiaí, Brazil) on both the maxillary and lower arches (except the deciduous canines). Next, exposure of the permanent right canine and extraction of the deciduous right canine and permanent left canine were performed. A passive 0.019x0.025" stainless steel archwire was used to maintain an anchorage unit while the left canine was pulled with a 0.016-in coaxial archwire. As the canine was "brought down" in position, a chain elastic was used to continue the traction (Figure 3).

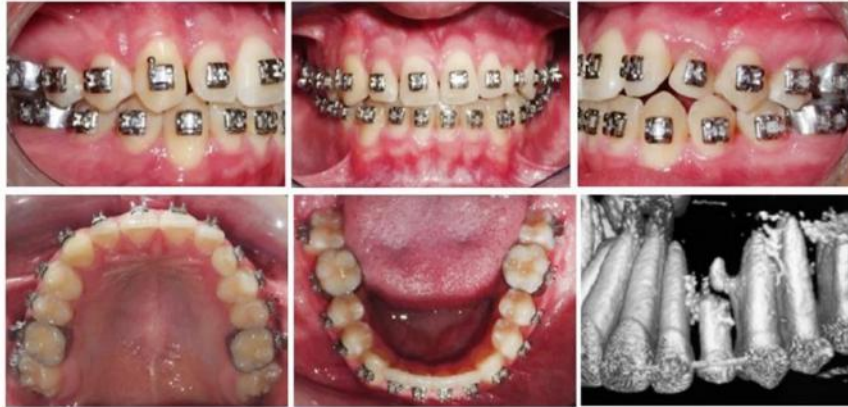Figure 3 - Treatment progress: A. HYRAX appliance construction; B. Initial tractioning; C. Occlusal view with the expander in place; D. Intraosseous view of the right canine; E, G. Rectangular archwire as an anchorage for tractioning with overlapped round wire; F. Distal movement; H. Maintenance of the left deciduous canine; I. radiograph image of this stage.



Source: Authors (2024).

Following the complete exposure of the crown of the right maxillary canine, the treatment progressed to the alignment and leveling stages of the arches. Figure 4 illustrate the relationship between the left deciduous canine and the dilacerated palatal root of the adjacent first premolar. During the final stage of orthodontic treatment, a brace was applied to the deciduous canine to move it slightly labially, thus establishing an appropriate overjet. (Figure 4).

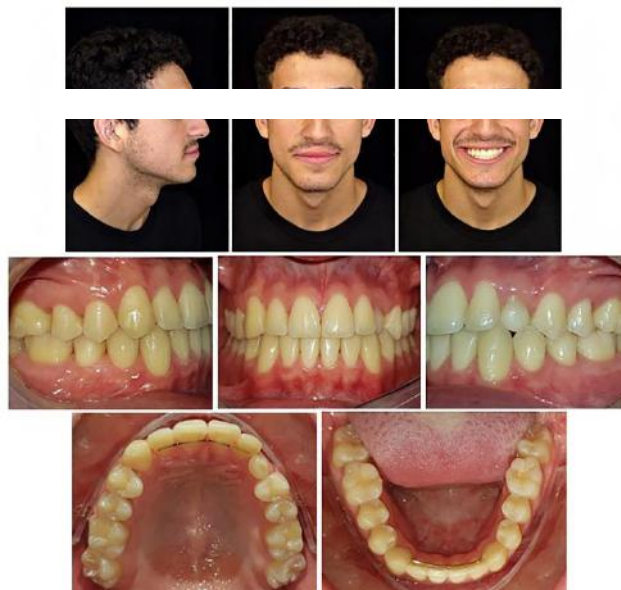
Figure 4 - Intraoral photographs and CBCT images taken during treatment progress, focusing on the dilacerated palatal root of the maxillary left first premolar. A brace was bonded to the left deciduous canine for slight movement toward the labial side.



Source: Authors (2024).

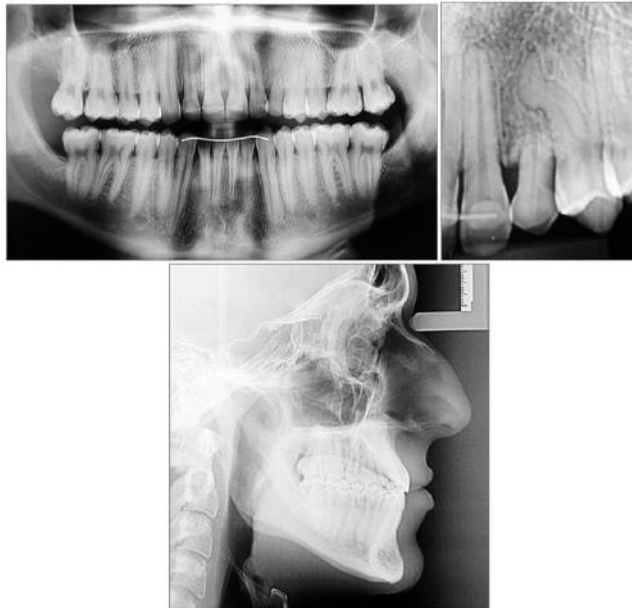
After 35 months of treatment, the esthetic and functional goals were achieved (Figure 5). Adequate root parallelism was obtained, along with the maintenance of molar and canine Class I relationship (even with the left deciduous tooth). (Figure 6). On the maxillary incisors, a fixed retention Ortho Flextech (Reliance, Itasca, USA) was bonded. In the mandible, a fixed retention was bonded onto the canines, using a 0.7mm stainless steel wire.

Figure 5 - Post-treatment facial and intraoral photographs. The pleasant smile has been preserved. The maxillary right canine is in a Class I relationship, and the deciduous canine remains in position for future implant/prosthetic replacement. Fixed retainers have been applied to both the maxillary and mandibular teeth.



Source: Authors (2024).

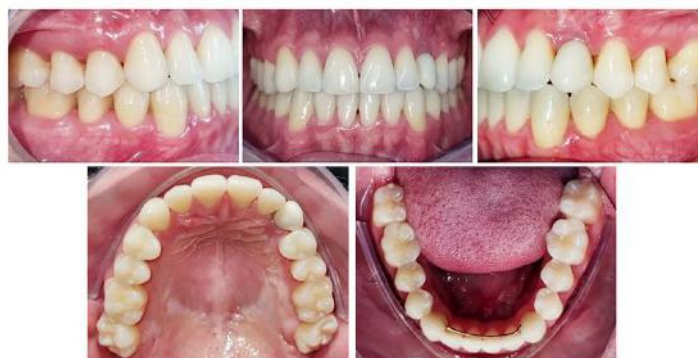Figure 6 - Post-treatment panoramic, periapical, and cephalometric radiographs are provided. The left deciduous canine has been retained to maintain bone level for future replacement. The third molars have been extracted.



Source: Authors (2024).

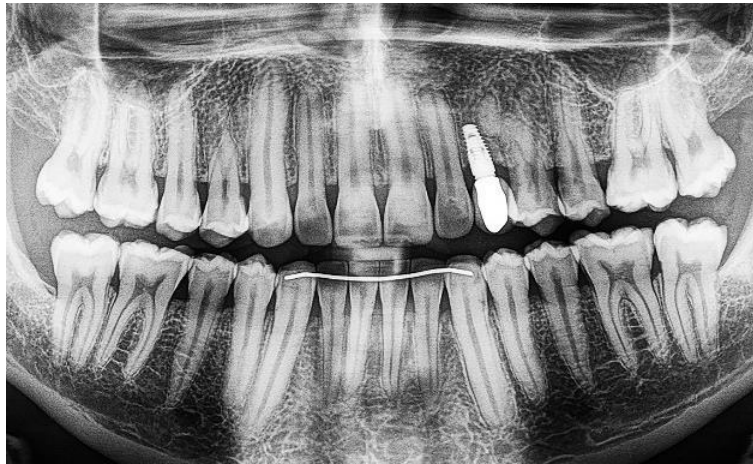
Six years and seven months after the completion of the treatment, the left deciduous canine was extracted, and an osseointegrated implant was placed. Figures 7 and 8 show a 3.4-year follow-up with the implant and the prosthesis correctly positioned and without the extracted third molars, demonstrating the long-term stability of the presented case.

Figure 7 - Intraoral photographs from a 3-year and 4-month follow-up, demonstrating the stability of the results.



Source: Authors (2024).

Figure 8 - Panoramic radiograph from a 3-year and 4-month follow-up. The implant-prosthetic replacement has been carefully positioned in relation to the roots of the left first bicuspid.



Source: Authors (2024).

4. Discussion

In this clinical case report, we addressed a malocclusion characterized by the impaction of both maxillary canines. The decision to extract the left canine was made after a thorough assessment, taking into account its location and angulation to maximize the chances of a successful treatment outcome. In managing the potential risks and implications of root resorption, it's crucial for healthcare professionals to ensure patients' informed consent. This aligns the treatment decisions with the patient's expectations and goals, especially in cases involving impacted canines. The importance of this was clearly communicated to the patient before initiating the treatment,(Schroder et al., 2018) and such a concern was clearly explained before starting the treatment.

Early diagnosis of dental inclusions is important to enable traction and prevent loss of units (Martins et al., 2024). Early interceptive approach to intervene early in the development of the impacted tooth, seeking to guide its correct positioning in the dental arch (Mathews & Kokich, 2013), but is It is worth mentioning, however the absence of the canine eminence at earlier ages alone cannot be considered a predictive factor for canine impaction (Manne et al., 2012). In some case extraction of the impacted canine is indicated (D'Amico et al., 2003), as with the left canine in the current clinical case due to its transalveolar positioning and the palatal root dilaceration of the first premolar.

The diagnosis was crucial for the proper application of the orthodontic treatment plan. In cases of impacted canines, obtaining tomography is indicated (Garib et al., 2014; Sosars et al., 2020). Although the panoramic radiography image provided a good notion of the position of the impacted canines in the present case, tomography was essential for the diagnosis, treatment planning, and execution of the treatment.

The rapid maxillary expansion is positively associated with the treatment of impacted canines (Harada-Karashima et al., 2021), and this procedure was performed in the present case to increase the perimeter of the maxillary arch before starting with the rapid maxillary expansion, followed the traction of the right canine, which may have been favorable for the success of the treatment.

For the right canine, surgical exposure of its crown was carried out, followed by orthodontic alignment, with the combined surgical/orthodontic approach in agreement with Andreasen (Andreasen, 1971) which consisted of the exposure of the crown followed by movement to the occlusal line. For the left canine, extraction was chosen due to its horizontal and unfavorable positioning for traction, in addition to the left maxillary first premolar presenting root dilaceration, which could be an obstacle to moving the canine towards the occlusal line. The treatment was performed while maintaining the left deciduous canine in

position, without including this tooth in the treatment with fixed appliances. After completion of growth, this deciduous tooth was extracted and the implant with the prosthetic crown installed in agreement with Bizzetto et al. (Bizzetto et al., 2013).

Various biomechanical approaches can be employed in the traction of impacted canines. Generally, skeletal (Park et al., 2004) or dental anchorage is used (Yadav et al., 2011). In this clinical case, a passive stainless steel arch was used as a dental anchorage unit to perform the traction of the right canine. Once the tooth was in a favorable position, treatment proceeded normally until orthodontic completion.

The main factors that contributed to the favorable outcome reported here were the correct diagnosis, appropriate orthodontic biomechanics with maxillary expansion and fixed appliances, and properly applied directional forces. The 3-year and 4-month follow-up indicates that this type of treatment was well performed, demonstrated by the good stability of the results. In similar cases of impacted canines, this may be one of the treatment alternatives.

5. Conclusions

In conclusion, traction was applied to the impacted right maxillary canine. The left maxillary canine, due to its trans-alveolar positioning, was extracted, and the corresponding deciduous tooth was retained. After the patient's growth was complete, this deciduous canine was removed and rehabilitated with an osseointegrated implant-supported prosthesis.

Each impacted canine case is unique, but investigating the biomechanical aspects of canine traction and the impact of various anchorage systems could refine treatment approaches. This would offer more predictable outcomes for patients with similar clinical cases to the one presented.

References

- Alqerban, A., Jacobs, R., Fieus, S., & Willems, G. (2011). Comparison of two cone beam computed tomographic systems versus panoramic imaging for localization of impacted maxillary canines and detection of root resorption. *Eur J Orthod*, 33(1), 93-102.
- Andreasen, G. F. (1971). A review of the approaches to treatment of impacted maxillary cuspids. *Oral Surg Oral Med Oral Pathol*, 31(4), 479-484.
- Araujo, E. A., Araujo, C. V., & Tanaka, O. M. (2013). Apicotomy: surgical management of maxillary dilacerated or ankylosed canines. *Am J Orthod Dentofacial Orthop*, 144(6), 909-915.
- Becker, A., Chaushu, G., & Chaushu, S. (2010). Analysis of failure in the treatment of impacted maxillary canines. *Am J Orthod Dentofacial Orthop*, 137(6), 743-754.
- Bishara, S. E. (1992). Impacted maxillary canines: a review. *Am J Orthod Dentofacial Orthop*, 101(2), 159-171.
- Bizzetto, M. S., Tessarollo, F. R., Jimenez, E. E., Guariza-Filho, O., Camargo, E. S., & Tanaka, O. M. (2013). Implant rehabilitation of canines in case of bilaterally missing maxillary lateral incisors. *Am J Orthod Dentofacial Orthop*, 144(1), 110-118.
- D'Amico, R. M., Bjerklind, K., Kuroi, J., & Falahat, B. (2003). Long-term results of orthodontic treatment of impacted maxillary canines. *Angle Orthod*, 73(3), 231-238.
- Garib, D. G., Calil, L. R., Leal, C. R., & Janson, G. (2014). Is there a consensus for CBCT use in Orthodontics? *Dental Press J Orthod*, 19(5), 136-149.
- Grisar, K., Denoiseux, B., Martin, C., Hoppenreijts, T., Calborean, F., Politis, C., et al. (2022). Treatment for critically impacted maxillary canines: Clinical versus scientific evidence - A systematic review. *J Stomatol Oral Maxillofac Surg*, 123(3), e12-e19.
- Grisar, K., Nys, M., The, V., Vrielinck, L., Schepers, S., Jacobs, R., et al. (2019). Long-term outcome of autogenously transplanted maxillary canines. *Clin Exp Dent Res*, 5(1), 67-75.
- Harada-Karashima, M., Ishihara, Y., Kamioka, H., & Kanomi, R. (2021). Age-related changes in the effect of rapid maxillary expansion on the position of labially impacted maxillary canines: A case-control study. *Am J Orthod Dentofacial Orthop*, 159(3), 305-311.
- Manne, R., Gandikota, C., Juvvadi, S. R., Rama, H. R., & Anche, S. (2012). Impacted canines: Etiology, diagnosis, and orthodontic management. *J Pharm Bioallied Sci*, 4(Suppl 2), S234-238.
- Martins, A. F., Soares, L. P., Lira, M. R. d., Silva, A. B., Silva, D. d. M., Guimarães, C. L. A. D., et al. (2024). Included canine in the palate, a surgical challenge: Case report. *Research, Society and Developmen*, 13, e4513345275.
- Mathews, D. P., & Kokich, V. G. (2013). Palatally impacted canines: the case for preorthodontic uncovering and autonomous eruption. *Am J Orthod Dentofacial Orthop*, 143(4), 450-458.

- Park, H. S., Kwon, O. W., & Sung, J. H. (2004). Micro-implant anchorage for forced eruption of impacted canines. *J Clin Orthod*, 38(5), 297-302.
- Rimes, R. J., Mitchell, C. N., & Willmot, D. R. (1997). Maxillary incisor root resorption in relation to the ectopic canine: a review of 26 patients. *Eur J Orthod*, 19(1), 79-84.
- Sacerdoti, R., & Baccetti, T. (2004). Dentoskeletal features associated with unilateral or bilateral palatal displacement of maxillary canines. *Angle Orthod*, 74(6), 725-732.
- Schroder, A. G. D., Guariza-Filho, O., de Araujo, C. M., Ruellas, A. C., Tanaka, O. M., & Porporatti, A. L. (2018). To what extent are impacted canines associated with root resorption of the adjacent tooth?: A systematic review with meta-analysis. *J Am Dent Assoc*, 149(9), 765-777 e768.
- Sosars, P., Jakobsone, G., Neimane, L., & Mukans, M. (2020). Comparative analysis of panoramic radiography and cone-beam computed tomography in treatment planning of palatally displaced canines. *Am J Orthod Dentofacial Orthop*, 157(5), 719-727.
- Tanaka, O. M., Avila, A. L., Pacheco, A. A., & Pithon, M. M. (2014). Four impacted canines in an adult patient: a challenge in orthodontics. *Indian J Dent Res*, 25(1), 125-127.
- Yadav, S., Chen, J., Upadhyay, M., Jiang, F., & Roberts, W. E. (2011). Comparison of the force systems of 3 appliances on palatally impacted canines. *Am J Orthod Dentofacial Orthop*, 139(2), 206-213.
- Yan, B., Sun, Z., Fields, H., & Wang, L. (2015). [Maxillary canine impaction increases root resorption risk of adjacent teeth: A problem of physical proximity]. *Orthod Fr*, 86(2), 169-179.