

## **Panfacial fracture osteosynthesis combined with submental orotracheal intubation:**

### **A case report**

**Osteossíntese de fratura panfacial combinada com intubação orotraqueal submentoniana: Um relato de caso**

**Osteosíntesis de fractura panfacial combinada con intubación orotraqueal submental: Reporte de caso**

Received: 04/26/2024 | Revised: 05/03/2024 | Accepted: 05/04/2024 | Published: 05/06/2024

**André Pereira Falcão**

ORCID: <https://orcid.org/0000-0001-6251-0629>  
Universidade de São Paulo, Brazil  
E-mail: [andre.falcao@usp.br](mailto:andre.falcao@usp.br)

**Luan Borges Venturi**

ORCID: <https://orcid.org/0000-0003-2845-2896>  
Hospital Municipal Dr. Cármino Caricchio, Brazil  
E-mail: [luanventuribucomaxilo@gmail.com](mailto:luanventuribucomaxilo@gmail.com)

**Wladimir Gushiken de Campos**

ORCID: <https://orcid.org/0000-0002-2086-3087>  
Universidade de São Paulo, Brazil  
E-mail: [vladimir.campos@usp.br](mailto:vladimir.campos@usp.br)

**Victoria Werneck de Paiva Ge**

ORCID: <https://orcid.org/0000-0002-7625-0116>  
Universidade de São Paulo, Brazil  
E-mail: [luanventuribucomaxilo@gmail.com](mailto:luanventuribucomaxilo@gmail.com)

**Matheus Branco Elias Dib**

ORCID: <https://orcid.org/0000-0002-8982-7519>  
Hospital Municipal Dr. Cármino Caricchio, Brazil  
E-mail: [contato@dibortognatic.com.br](mailto:contato@dibortognatic.com.br)

**Carina Domaneschi**

ORCID: <https://orcid.org/0000-0001-8615-3283>  
Universidade de São Paulo, Brazil  
E-mail: [domaneschi@usp.br](mailto:domaneschi@usp.br)

### **Abstract**

Panfacial fractures can be a surgical challenge due to bone instability and loss of facial landmarks. Accurate diagnosis and planning favor the correct restoration of facial architecture. Good results depend on the acquisition of occlusal relationships, which is difficult in classic orotracheal intubation. Thus, submental bypass is an interesting way of maintaining the airway during surgery and simultaneously allowing occlusal contacts. This study aims to evaluate multiple facial osteosyntheses in a patient with panfacial fracture, for whom submental orotracheal intubation was chosen by means of a case report. A 29-year-old male patient, victim of a car accident, presented trismus, dystopia, enophthalmos, occlusal changes, hyposphagma, bilateral periorbital ecchymosis, loss of the anteroposterior projection of the face and pain. The imaging examination showed multiple fracture patterns, which characterized a panfacial fracture. Orotracheal intubation with submental bypass was performed to improve osteosynthesis results and guarantee air permeability. “Bottom-up” and “outside-in” reconstruction sequences were chosen through coronal access with left preauricular extension and subtarsal and intraoral vestibular approaches. The procedure was uneventful and the signs and symptoms were cured. Proper planning in complex cases, such as panfacial fractures, allows adequate resolution and satisfactory aesthetic-functional results. Furthermore, submental orotracheal intubation is safe and can be an interesting and valuable ventilation alternative.

**Keywords:** Intubation; Internal fracture fixations; Skull fractures.

### **Resumo**

As fraturas panfaciais podem ser um desafio cirúrgico devido à instabilidade óssea e à perda de marcos faciais. O diagnóstico e planejamento precisos favorecem o correto restabelecimento da arquitetura facial. Bons resultados dependem da aquisição de relações oclusais, o que é difícil na intubação orotraqueal clássica. Assim, a derivação submentoniana é uma forma interessante de manter as vias aéreas durante a cirurgia e simultaneamente permitir os

contatos oclusais. Este estudo tem como objetivo avaliar múltiplas osteossínteses de face em paciente com fratura panfacial, para o qual optou-se pela intubação orotraqueal submentoniana por meio de um relato de caso. Paciente do sexo masculino, 29 anos, vítima de acidente automobilístico, apresentou trismo, distopia, enoftalmia, alteração oclusal, hiposfagma, equimose periorbital bilateral, perda da projeção anteroposterior da face e dor. O exame de imagem mostrou múltiplos padrões de fratura, o que caracterizou uma fratura panfacial. Foi realizada intubação orotraqueal com derivação submentoniana, para melhora dos resultados da osteossíntese e garantia de permeabilidade aérea. Foram escolhidas sequências de reconstrução “de baixo para cima” e “de fora para dentro” através de acesso coronal com extensão pré-auricular esquerda e acessos vestibulares subtarsais e intraorais. O procedimento transcorreu sem intercorrências e os sinais e sintomas foram curados. O planejamento adequado em casos complexos, como as fraturas panfaciais, permite resolução adequada e resultados estético-funcionais satisfatórios. Além disso, a intubação orotraqueal submentoniana é segura e pode ser uma alternativa ventilatória interessante e valiosa.

**Palavras-chave:** Intubação; Fixação interna de fraturas; Fraturas cranianas.

### Resumen

Las fracturas panfaciales pueden ser un desafío quirúrgico debido a la inestabilidad ósea y la pérdida de puntos de referencia faciales. Un diagnóstico y una planificación precisos favorecen la correcta restauración de la arquitectura facial. Los buenos resultados dependen de la adquisición de relaciones oclusales, lo que es difícil en la intubación orotraqueal clásica. Por tanto, la derivación submentoniana es una forma interesante de mantener la vía aérea durante la cirugía y al mismo tiempo permitir contactos oclusales. Este estudio tiene como objetivo evaluar múltiples osteosíntesis faciales en un paciente con fractura panfacial, para quien a través de un reporte de caso se optó por la intubación orotraqueal submental. Paciente masculino de 29 años, víctima de accidente automovilístico, presentó trismo, distopía, enoftalmos, cambios oclusales, hiposfagma, equimosis periorbitaria bilateral, pérdida de la proyección anteroposterior de la cara y dolor. El examen de imágenes mostró múltiples patrones de fractura, que caracterizaban una fractura panfacial. Se realizó intubación orotraqueal con derivación submental para mejorar los resultados de la osteosíntesis y garantizar la permeabilidad al aire. Se eligieron secuencias de reconstrucción “de abajo hacia arriba” y “de afuera hacia adentro” mediante acceso coronal con extensión preauricular izquierda y abordajes vestibulares subtarsal e intraoral. El procedimiento transcurrió sin incidentes y los signos y síntomas se curaron. Una adecuada planificación en casos complejos, como las fracturas panfaciales, permite una adecuada resolución y resultados estético-funcionales satisfactorios. Además, la intubación orotraqueal submentoniana es segura y puede ser una alternativa de ventilación interesante y valiosa.

**Palabras clave:** Intubación; Fijaciones de fracturas internas; Fracturas de cráneo.

## 1. Introduction

Complex fractures involving the three-thirds of the face are classified as panfacial fractures and require planning to recover facial three-dimensionality and guarantee airway patency (Rodrigues et al., 2017). There are reconstructive surgical philosophies, such as the “bottom-up and outside-inside” and “top-bottom and inside-outside” sequences. However, in all of them, the need for individual patient evaluation is fundamental. The main therapeutic objectives are to restore facial dimensions, symmetry, anteroposterior projection and function (Pisano & Tiwana, 2019; Ramakrishnan et al., 2021). Rigid internal fixation with miniplates and screws is of great importance in the rehabilitation of this type of patient.

The management of panfacial fractures depends on clinical and imaging analysis, considering tissue placement and comminution areas (Massenburg & Lang, 2021). Complications such as enophthalmos, dystopia and nasolacrimal duct injury must be anticipated and considered in surgical planning (Pisano & Tiwana, 2019). The restoration of facial width is one of the fundamental surgical concerns. The literature has shown the initial “outside-in” approach as a functional alternative, starting with the arch and zygomatic body. Concomitantly, by the “inside to outside” sequence, insufficient face width and asymmetries due to insufficient reduction can be obtained. (Yun & Na, 2018) The restoration of the occlusion is essential and helps in the spatial repositioning of the fractured sections and restoring the pillars of the face. (Ali & Lettieri, 2017) Thus, some authors indicate the “bottom to top” approach in panfacial fractures (de Melo et al., 2013; Santiago et al., 2020).

The degree of comminution must also be taken into account. Extremely comminuted fractures can make reduction and fixation difficult. Another strategy would be to use an Ilizarov external fixator (Hihara et al., 2019). Regardless of the technique, fixation from the most stable area to the least stable area seems to be the ideal for achieving satisfactory results

(Koraitim, 2020; Ribeiro et al., 2021). Withal, the complex bone instability of panfacial fractures and the need for maxillomandibular fixation (MMF) makes conventional or nasotracheal intubation difficult, so one option is the submental shunt with a wired tube, for transurgical mechanical ventilation and release of the mouth and middle third for the blocking procedure, reduction and osteosynthesis (Daflon De Faria et al., 2018; González-Magaña et al., 2018). The main objective of this study is to evaluate multiple facial osteosynthesis in a patient with panfacial fracture, in whom a submental shunt combined with orotracheal intubation was chosen.

## **2. Methodology**

This article is a qualitative research, structured as a case report, and aims to evaluate surgical treatment for the correction of multiple facial fractures, which characterize a panfacial fracture, analyzing pre-surgical signs and symptoms and improvement in functionality, facial projections and symptoms. To achieve surgical needs, it was necessary to use submental shunting in orotracheal intubation. The description of the patient's pre- and postoperative clinical aspects, as well as the description of the submental derivation and facial osteosynthesis stages were made. At the same time, documentary photos were taken pre-, trans- and post-operatively. This article has clinical images referring to 6 months postoperatively. Computed tomography scans of the face were performed preoperatively and postoperatively, demonstrating reconstructed areas. Titanium plates and mesh from the 1.5, 2.0 and 2.4 system were used, as well as intermaxillary locking screws. Literature about panfacial fractures and submental orotracheal intubation was analysed and compared with our results. In relation to the structure of a case report, it is a well-known type of project in the literature, evaluated by authors such as Nissen & Wynn (2014) regarding its benefits for the scientific community.

This research follows the guidelines of Resolution CNS 466/2012 and the CONEP 2018 letter, with the benefits of a thorough analysis of surgical treatment in a patient with a panfacial fracture, with no direct or indirect harm to the patient resulting from this study. The ethical principles proposed by the Declaration of Helsinki were respected. This study was endorsed by the Research Ethics Committee of Hospital Municipal Dr. Cármino Caricchio (5.159.109). Continuity of surgical and clinical trauma treatment was ensured regardless of the patient agreement to participate in this research. Therefore, the patient signed the Informed Consent Form, authorizing publication of his data and images for scientific and publication purposes.

## **3. Case Report**

A 29-year-old male patient was referred for hospital care after suffering a traffic accident (motorcycle vs. car crash) with multiple facial fractures. He presented trismus, dystopia, left enophthalmos, occlusal alteration, hyposphagma, bilateral periorbital ecchymosis and significant increase in facial width, exhibiting an “open book” facial aspect (Figure 1). There was no rhinoliqorrhoea. His medical story and general physical examination were normal.

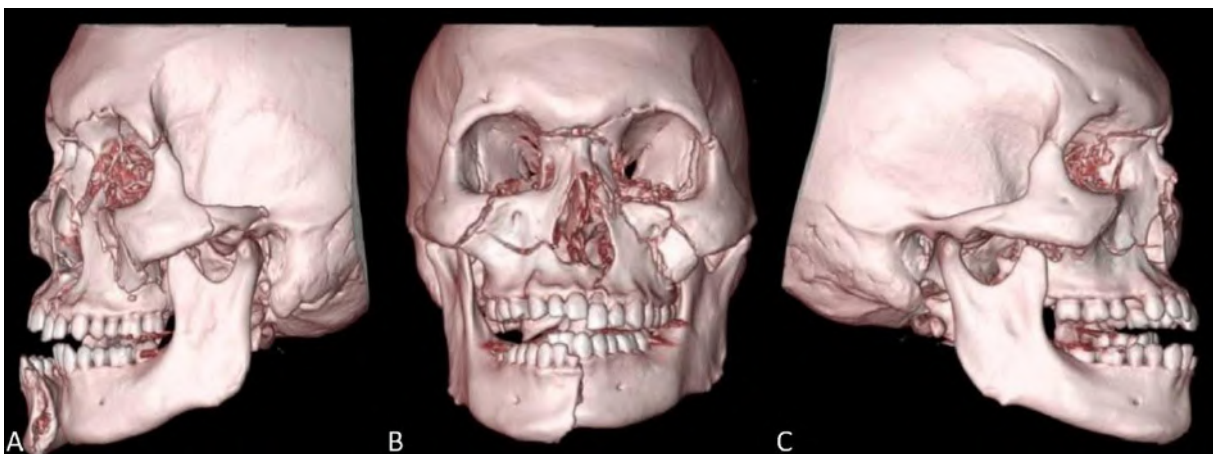
**Figure 1** – Patient on admission, with “open book” facial appearance and multiple bruises. A: front view. B: elevated front.



Source: Authors (2023).

In the computed tomography (CT) scan, images compatible with fractures were diagnosed in the left frontozygomatic suture; bilateral zygomaticomaxillary sutures; bilateral orbital-zygomatic complex, especially left orbital floor; sphenoid pterygoid processes; anterior, medial and posterior walls of the bilateral maxillary sinus; naso-orbito-ethmoidal (NOE) region; maxilla (Lannelongue pattern) and in mandibular symphysis (Figure 2). The surgical procedure for correcting the multiple facial fractures was performed after discharge from the Neurosurgery team and hemodynamic stabilization.

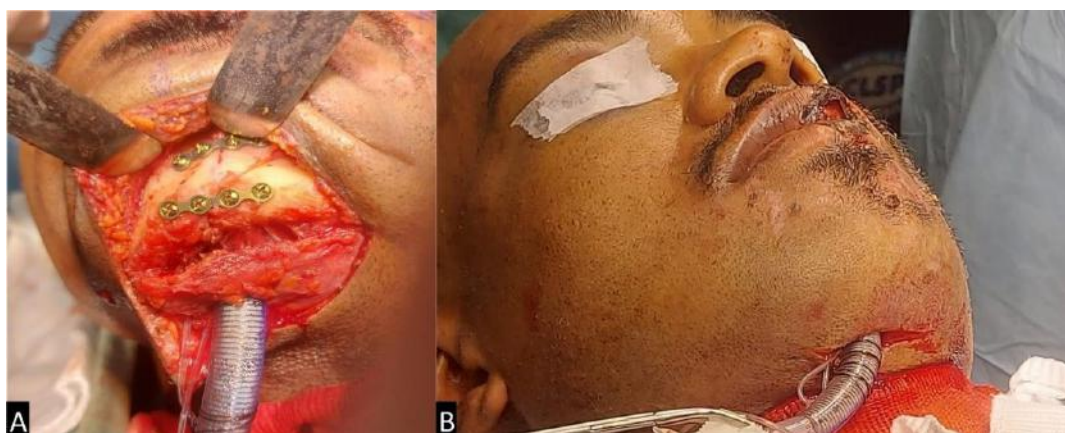**Figure 2** – 3D reconstruction demonstrates multiple facial fractures affecting the three facial thirds and important displacements. A: left side view. B: front view. C: right side view.



Source: Authors (2023).

The approach chosen to treat the patient panfacial fracture was the “bottom-up” and “outside-inside” sequences, and intubation with submental bypass. After submitting the patient to general anesthesia via orotracheal intubation, submental surgical access with passage through the sublingual space was performed. Then, the wired endotracheal tube was pulled out extraorally athwart this surgical wound with kelly tweezers, allowing orotracheal intubation with submental extension (Figure 3).

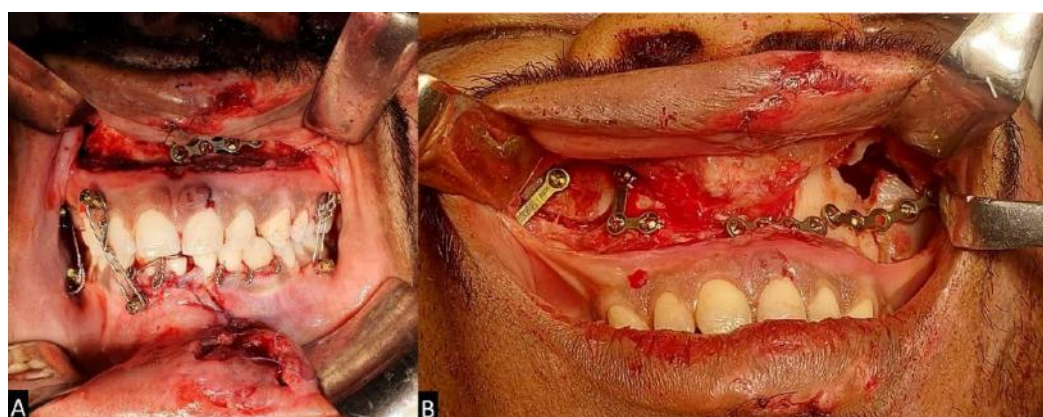**Figure 3** – Submental access. A: submental view demonstrates passage of the wired tube and mandibular osteosynthesis. B: tissues placed over the tube and submental access.



Source: Authors (2023).

The mandible fracture was reduced and fixed first, and was followed by the installation of intermaxillary fixation (IMF). Afterwards, an intra-oral maxillary access was performed, allowing the Lanelongue fracture correction (Figure 4A).

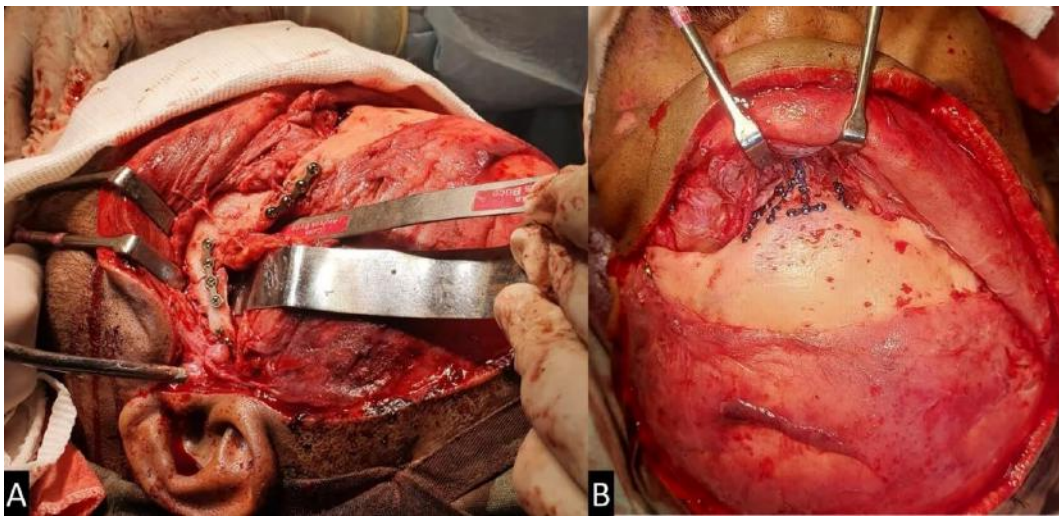
**Figure 4** – Transurgical intraoral view. A: intermaxillary fixation, maxillary intraoral vestibular access and Lanelongue fracture osteosynthesis. B: osteosynthesis of zygomatic-maxillary pillars



Source: Authors (2023).

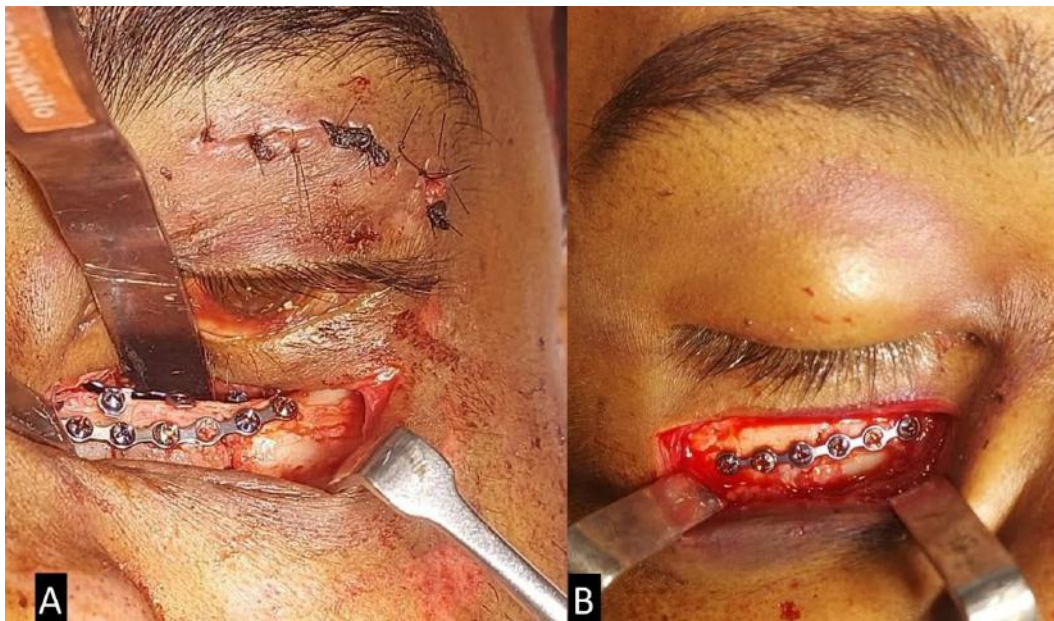Moreover, coronal access was performed with pre-auricular extension on the left side (Figure 5) and then the subtarsal accesses bilaterally (Figure 6).

**Figure 5** – Coronal access. A: right zygomatic arch and body fixation. B: fronto-maxillary and naso-frontal sutures osteosynthesis.



Source: Authors (2023).

**Figure 6** – Subtarsal approaches. A: infraorbital arch osteosynthesis and titanium mesh in the left orbital floor. B: right infraorbital arch fixation.

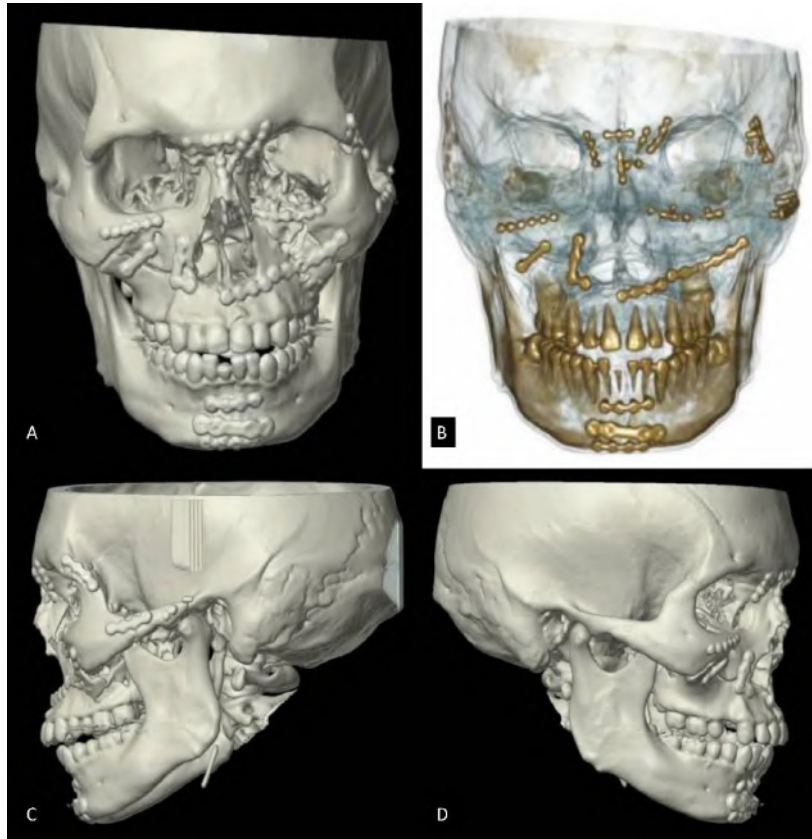


Source: Authors (2023).

The left side's zygomatic arch and frontozygomatic suture were reduced and fixed, respectively, followed by the naso-orbital ethmoidal fracture and the bilateral infraorbital margins. An orbital floor titanium mesh was fixed on the left side. Finally, the zygomaticomaxillary buttresses were fixed bilaterally (Figure 4B), and the IMF was removed. A 2.4 plate was used in the compression zone of the mandible fracture. The other mandible fixation plates and screws, as well as those used in the maxilla, left frontozygomatic pillar and zygomatic arch were of the 2.0 system. The infraorbital margins and the naso-orbital-ethmoid fracture were fixed with the 1.5 system. Internal sutures were performed with 3-0 and 4-0 polyglactin 910. The coronal access was sutured with 3-0 nylon, the submandibular with 4-0 nylon and the subtarsals with 6-0 nylon. The surgical procedure lasted for six hours. Postoperatively, the patient had no infections in the surgical wounds. New CT scans were taken,

revealing an acceptable placement of the osteosynthesis plates (Figure 7).

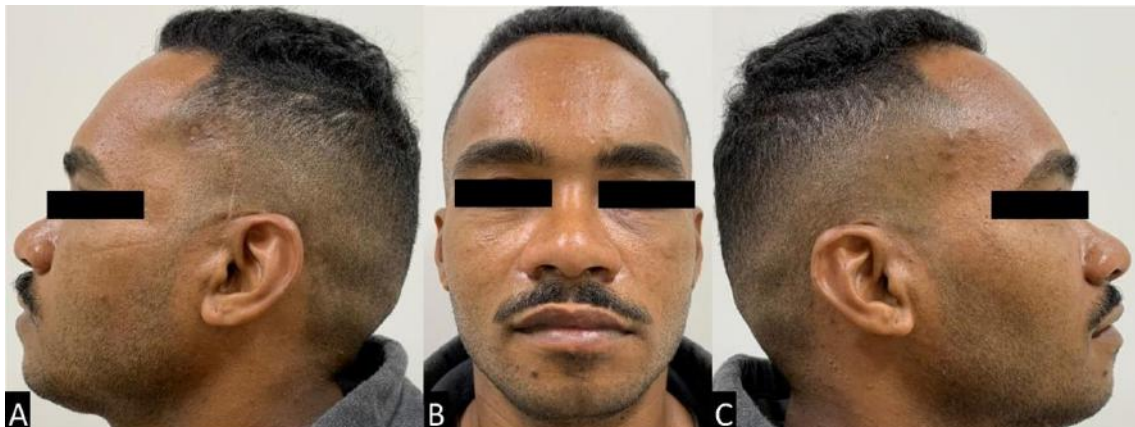**Figure 7** – 3D reconstruction demonstrates bone reduction and placement of osteosynthesis plates and screws. A: front view. B: contrasted front view. C: left side view. D: right side view.



Source: Authors (2023).

The extraoral sutures were removed after 7 days, and those of the coronal accesses in 14 days. Since then, he has been under follow-up, presenting satisfactory recovery after five months. His signs and symptoms fully healed. Especially, facial width and antero-posterior projection were adjusted, correcting the “open book” facial aspect (Figure 8).

**Figure 8** – Patient in the 6-month postoperative period with facial architecture recovery. A: left side view. B: front view. C: right side view.



Source: Authors (2023).

### 3. Discussion

Panfacial fractures can be a challenge given their significant instability, multiple involvement of facial bones and comminution (Koraitim, 2020). Correct planning must involve clinical and tomographic analysis (Pisano & Tiwana, 2019), in addition to ensuring hemodynamic stability (Santiago et al., 2020). Different approaches are proposed in the literature, but the therapeutic definition depends on the case individualization (Koraitim, 2020; Ramakrishnan et al., 2021). There did not seem to be significant differences in the outcome of facial asymmetry treatment either by the “bottom-to-top and inside-out” or by the “top-to-bottom and outside-inside” method (Degala et al., 2015), but a recent systematic review demonstrated a better outcome with the “bottom-to-top and inside-out” technique (Ramakrishnan et al., 2021). Besides that, some authors defend the “outside-inside” technique to obtain better malar projection (Kim et al., 2016). Thus, our patient benefited from the “bottom-top” and “outside-inside” reconstructive approach, which allowed us better control of the transurgical facial instability and greater clinical empirical accuracy in obtaining the probable facial architecture and recovery of the anteroposterior projection. In addition, starting with the mandible was advantageous as it firstly re-established occlusion (de Melo et al., 2013). Our surgery time of 6 hours was considered adequate, given the four axial facial segments impairment, case that the literature estimate approximately 7 hours of procedure (Jang et al., 2020).

Multiple surgical approaches are often necessary and offer versatility in this type of reconstruction. Coronal access is one of the most used: it permits a wide range of surgical action, visibility and a scar hidden by the scalp, allowing access to the frontal, zygomatic and NOE region (Pisano & Tiwana, 2019; Rajmohan, 2015). Its choice facilitated the positioning of the fixation system in the nasofrontal and frontozygomatic sutures. However, it was not sufficient for the approach and complete reconstruction of the middle third of the face. Bilateral subnasal access was required for the necessary fixation of the zygomatic-maxillary suture and satisfactory correction of diplopia. Furthermore, the intraoral vestibular access allowed the addition of a plate for maxillary fixation and stabilization of zygomatic and pterygoid pillars through the maxillary junction with the zygomatic body bilaterally. Combining these accesses is beneficial and allows satisfactory results with low complication rates (Pisano & Tiwana, 2019; Tang et al., 2009).

The presence of NOE and mandibular fractures and maxillary disjunction required transurgical MMF for correction and reference of the occlusal and anteroposterior aspect of the middle and lower thirds of the face. MMF would be compromised by conventional orotracheal intubation. Nevertheless, the present ethmoidal comminution contraindicated nasotracheal intubation. Thus, the ventilation strategy adopted was the submental bypass, which allowed the patient to correctly MMF without compromising pulmonary and anesthetic stability. The technique is considered safe, effective, quick and less invasive compared to tracheostomies, and prevents complications such as hemorrhages, tracheal stenosis, air embolism, tracheoesophageal fistula and hypertrophic scars. (Daniels et al., 2020; González-Magaña et al., 2018; Mishra et al., 2020; Rodrigues et al., 2017)

We obtained a significant improvement in the three-dimensionality of the face, which is considered the gold standard of treatment for panfacial fractures (Koraitim, 2020). Clinical improvement of edema and pain was also observed in the first postoperative week and was much better with 6 months of follow-up. Malocclusion, enophthalmos, ocular motility disorder, frontal paralysis and zygomatic-temporal atrophy are possible post-surgical complications (Tang et al., 2009). However, none of them were observed in our patient. The patient reported satisfaction with the post-surgical result obtained.

### 4. Conclusion

The surgical osteosynthesis needs were met and submental orotracheal intubation provided ventilatory safety and allowed adequate maxillomandibular manipulation during surgery. Panfacial fractures may be a challenge for bone reduction



and return of facial contour. For that, different surgical strategies can be adopted. Therefore, the use of “bottom-up” and “outside-inside” sequences was satisfactory for our case management.

Future research that evaluates institutional osteosynthesis protocols in a serial and updated manner for cases of extensive facial fractures would be interesting, as well as studies with a significant sample that evaluate, from an anesthetic and surgical point of view, the benefits of submental orotracheal intubation perceived in this project.

## References

- Ali, K., & Lettieri, S. C. (2017). Facial Trauma: Management of Panfacial Fracture. *Seminars in Plastic Surgery*, 31(2), 108. <https://doi.org/10.1055/S-0037-1601579>
- Daflon De Faria, W., Campos, A., Rodrigues, E., Uzeda, M., & Resende, R. (2018). Intubação submentoniana: revisão de literatura e descrição da técnica cirúrgica. *Revista Fluminense de Odontologia*, 49. <https://doi.org/10.22409/ijosd.v1i49.392>
- Daniels, J. S., Albakry, I., Braimah, R. O., Samara, M. I., Albalasi, R. A., Begum, F., & Mana Ali-Mohamed Al-kalib. (2020). Experience with Airway Management and Sequencing of Repair of Panfacial Fractures: A Single Tertiary Healthcare Appraisal in Najran, Kingdom of Saudi Arabia - A Retrospective Study. *Annals of Maxillofacial Surgery*, 10(2), 402–408. [https://doi.org/10.4103/AMS.AMS\\_202\\_19](https://doi.org/10.4103/AMS.AMS_202_19)
- de Melo, W. M., Sonoda, C. K., Shinohara, E. H., & Garcia, I. R. (2013). Using the “bottom-up and outside-in” sequence for panfacial fracture management: does it provide a clinical significance? *The Journal of Craniofacial Surgery*, 24(5), e479–e481. <https://doi.org/10.1097/SCS.0B013E318290333C>
- Degala, S., Sundar, S. S., & Mamata, K. S. (2015). A Comparative Prospective Study of Two Different Treatment Sequences i.e. Bottom Up-Inside Out and Topdown-Outside in, in the Treatment of Panfacial Fractures. *Journal of Maxillofacial and Oral Surgery*, 14(4), 986–994. <https://doi.org/10.1007/S12663-015-0769-2>
- González-Magaña, F., Malagón-Hidalgo, H. O., García-Cano, E., Vilchis-López, R., Fentanes-Vera, A., & Ayala-Ugalde, F.-A. (2018). Airway management through submental derivation: a safe and easily reproduced alternative for patients with complex facial trauma. *Journal of the Korean Association of Oral and Maxillofacial Surgeons*, 44(1), 12. <https://doi.org/10.5125/jkaoms.2018.44.1.12>
- Hihara, M., Yagura, T., Takegawa, M., Kakudo, N., Morimoto, N., & Kusumoto, K. (2019). A novel fixation method for panfacial fracture using an Ilizarov-type external fixator. *Trauma Case Reports*, 22. <https://doi.org/10.1016/J.TCR.2019.100214>
- Jang, S. B., Choi, S. Y., Kwon, T. G., & Kim, J. W. (2020). Concomitant injuries and complications according to categories of pan-facial fracture: a retrospective study. *Journal of Cranio-Maxillofacial Surgery*, 48(4), 427–434. <https://doi.org/10.1016/J.JCMS.2020.02.018>
- Kim, J., Choi, J.-H., Chung, Y. K., & Kim, S. W. (2016). Panfacial Bone Fracture and Medial to Lateral Approach. *Archives of Craniofacial Surgery*, 17(4), 181–185. <https://doi.org/10.7181/ACFS.2016.17.4.181>
- Koraitim, M. (2020). Panfacial Fractures Management. *The Journal of Craniofacial Surgery*, 31(4), e329–e331. <https://doi.org/10.1097/SCS.0000000000006208>
- Massenburg, B. B., & Lang, M. S. (2021). Management of Panfacial Trauma: Sequencing and Pitfalls. *Seminars in Plastic Surgery*, 35(4), 292–298. <https://doi.org/10.1055/S-0041-1735813>
- Mishra, R., Yadav, D., Tripathi, S., Kandel, L., Baral, P. P., Shubham, S., Karn, A., & Dutta, K. (2020). Submental Intubations in Panfacial Fractures. *Clinical, Cosmetic and Investigational Dentistry*, 12, 41–48. <https://doi.org/10.2147/CCIDE.S228326>
- Nissen, T., & Wynn, R. (2014). The clinical case report: a review of its merits and limitations. *BMC Research Notes*, 7(1), 264. <https://doi.org/10.1186/1756-0500-7-264>
- Pisano, J., & Tiwana, P. S. (2019). Management of Panfacial, Naso-Orbital-Ethmoid and Frontal Sinus Fractures. *Atlas of the Oral and Maxillofacial Surgery Clinics*, 27(2), 83–92. <https://doi.org/10.1016/J.CXOM.2019.04.001>
- Rajmohan, S. (2015). Coronal/Hemicoronal Approach – A Gateway to Craniomaxillofacial Region. *Journal of clinical and diagnostic research*. <https://doi.org/10.7860/JCDR/2015/14797.6296>
- Ramakrishnan, K., Palanivel, I., Narayanan, V., Chandran, S., & Narayanan, J. (2021). Sequencing of Fixation in Panfacial Fracture: A Systematic Review. *Journal of Maxillofacial and Oral Surgery*, 20(2), 180–188. <https://doi.org/10.1007/S12663-020-01387-Y>
- Ribeiro, R., Miranda, E., Brito, T., Almeida, R., Silva, G., Costa, E., & Sales, R. (2021). Surgical approach to panfacial fracture with focus on the sequence of bone pillar reconstruction: a case report. *Brazilian Journal of Development*, 7(5), 52773–52773. <https://doi.org/10.34117/bjdv7n5-604>
- Rodrigues, W. C., de Melo, W. M., de Almeida, R. S., Pardo-Kaba, S. C., Sonoda, C. K., & Shinohara, E. H. (2017). Submental Intubation in Cases of Panfacial Fractures: A Retrospective Study. *Anesthesia Progress*, 64(3), 153. <https://doi.org/10.2344/ANPR-64-04-07>
- Santiago, L. R., Rodrigues, C. M. de C., Santos, D. M., Batista, J. D., Furtado, L. M., & Rocha, F. S. (2020). Reconstrução de fratura panfacial cominuta. *Medicina (Ribeirao Preto Online)*, 53(2), 183–188. <https://doi.org/10.11606/issn.2176-7262.v53i2p183-188>
- Tang, W., Feng, F., Long, J., Lin, Y., Wang, H., Liu, L., & Tian, W. (2009). Sequential surgical treatment for panfacial fractures and significance of biological osteosynthesis. *Dental Traumatology*, 25(2), 171–175. <https://doi.org/10.1111/j.1600-9657.2008.00739.x>
- Yun, S., & Na, Y. (2018). Panfacial bone fracture: cephalic to caudal. *Archives of Craniofacial Surgery*, 19(1), 1. <https://doi.org/10.7181/ACFS.2018.19.1.1>