

Diagnosis of 7q11.23 deletion in a patient from Manaus, Amazonas with Williams-Beuren syndrome: Case report

Diagnóstico da deleção 7q11.23 em um paciente de Manaus, Amazonas com síndrome de Williams-Beuren: relato de caso

Diagnóstico de delección 7q11.23 en un paciente de Manaus, Amazonas con síndrome de Williams-Beuren: reporte de caso

Received: 05/17/2024 | Revised: 05/28/2024 | Accepted: 05/29/2024 | Published: 05/31/2024

Natalia Dayane Moura Carvalho

ORCID: <https://orcid.org/0000-0002-8513-0749>

Universidade Federal do Amazonas, Brasil

E-mail: nathydayane@gmail.com

Vania Mesquita Gadelha Prazeres

ORCID: <https://orcid.org/0000-0001-9531-1706>

Universidade Federal do Amazonas, Brasil

E-mail: vaniaprazeres@ufam.edu.br

Cleiton Fantin Rezende

ORCID: <http://orcid.org/0000-0002-4801-698X>

Universidade do Estado do Amazonas, Brasil

E-mail: cfantin@uea.edu.br

Abstract

Williams-Beuren Syndrome is a rare disease caused by a chromosomal microdeletion in region 7q11.23. It is characterized as multisystemic, including intellectual and learning disabilities, distinct facial features, short stature, hypersocial behavior, and many malformations. Its diagnosis is traditionally clinical, but cytogenomic analyses such as fluorescence *in situ* hybridization can also be used for better etiological characterization of the syndrome. Our objective is to report the case of a boy in Manaus/Amazonas with Williams-Beuren Syndrome that presents a microdeletion in region 7q11.23. The patient is male, 12 years, of non-consanguineal parents, and no family history of hereditary diseases. The patient was sent for genetic testing after assessment of possible genetic syndrome, as the physical exams presented a gnome-like face, short nasal bridge, full lips, frequent smile, short stature, difficulty learning and atrioventricular dysplasia of valves with mild insufficiency and a cyst in the left kidney. The results of the karyotype exam were normal and the fluorescence *in situ* hybridization revealed the microdeletion of region 7q11.23. Upon the follow-up, the subject was diagnosed with Williams-Beuren Syndrome. This microdeletion results in the loss of various genes that affect genic dosage/genic haploinsufficiency, resulting in a cytogenetic imbalance, consequently contributing to the patient's phenotype. Therefore, the cytogenomic analysis was instrumental for the etiological diagnosis, in which microdeletion 7q11.23 was identified, allowing for proper diagnosis and prognosis, genetic counseling, and medical decisions, granting a better quality of life for the patient.

Keywords: Rare disease; Chromosomal deletion; Haploinsufficiency; Fluorescence in situ hybridization.

Resumo

Síndrome de Williams-Beuren é uma doença rara causada por uma microdeleção na região 7q11.23. É caracterizada como multissistêmica, incluindo deficiência mental, dificuldade de aprendizado, fêcis dismórficas, baixa estatura, comportamento hipersociável e, diversas malformações. Seu diagnóstico é tradicionalmente clínico, mas análises citogenômicas podem ser utilizados, como a hibridização *in situ* por fluorescência, permitindo uma melhor caracterização etiológica da síndrome. Objetivou-se relatar um caso de um menino com a Síndrome de Williams-Beuren apresentando a microdeleção na região 7q11.23 em Manaus/Amazonas. Paciente sexo masculino, 12 anos, filho de casal não consanguíneo e sem histórico de doença heredofamiliar. O paciente foi encaminhado para ambulatório de genética devido à suspeita de síndrome genética e ao exame físico foi identificado face de gnomo com nariz arrebitado, lábios cheios, sorriso frequente, baixa estatura, dificuldade de aprendizado, displasia de válvulas atrioventriculares com insuficiência leve e cisto renal esquerdo. O resultado do exame de cariótipo foi normal e o hibridização *in situ* por fluorescência revelou uma microdeleção da região 7q11.23. Após retorno a consulta, foi diagnosticado com a Síndrome de Williams-Beuren. Essa microdeleção ocasiona em perda de vários genes que afetam a dosagem gênica/haploinsuficiência gênica, resultando em um desequilíbrio citogenômico, e consequentemente

contribuindo para o fenótipo do paciente. Portanto, a análise citogenômica foi primordial no diagnóstico etiológico, no qual identificou a microdeleção 7q11.23, permitindo o desfecho do diagnóstico bem como no prognóstico, aconselhamento genético e na tomada de decisões médicas, garantindo a melhor qualidade de vida para o paciente.

Palavras-chave: Doença rara; Deleção cromossômica; Haploinsuficiência; Hibridização in situ por fluorescência.

Resumen

El síndrome de Williams-Beuren es una enfermedad rara causada por una microdelección en la región 7q11.23. Se caracteriza por ser multisistémica, incluyendo discapacidad mental, dificultades de aprendizaje, rasgos dismórficos, baja estatura, comportamiento hipersociable y diversas malformaciones. Su diagnóstico es tradicionalmente clínico, pero se pueden utilizar análisis citogenómicos, como la hibridación fluorescente in situ, que permiten una mejor caracterización etiológica del síndrome. El objetivo fue reportar el caso de un niño con Síndrome de Williams-Beuren que presenta microdelección en la región 7q11.23 en Manaus/Amazonas. Paciente masculino de 12 años, hijo de pareja no consanguínea y sin antecedentes de enfermedad hereditaria. El paciente fue remitido a la consulta de genética por sospecha de síndrome genético y al examen físico se observó rostro de gnomo con nariz respingona, labios carnosos, sonrisa frecuente, baja estatura, dificultades de aprendizaje, displasia de la válvula auriculoventricular con insuficiencia leve y quiste renal izquierdo. El resultado del examen de cariotipo fue normal y la hibridación fluorescente in situ reveló una microdelección de la región 7q11.23. Tras regresar a consulta le diagnosticaron el Síndrome de Williams-Beuren. Esta microdelección provoca la pérdida de varios genes que afectan la dosis genética/haploinsuficiencia genética, lo que resulta en un desequilibrio citogenómico y, en consecuencia, contribuye al fenotipo del paciente. Por lo tanto, el análisis citogenómico fue fundamental en el diagnóstico etiológico, el cual identificó la microdelección 7q11.23, permitiendo tanto el resultado diagnóstico como el pronóstico, el consejo genético y la toma de decisiones médicas, asegurando la mejor calidad de vida del paciente.

Palabras clave: Enfermedad rara; Delección cromosómica; Haploinsuficiencia; Hibridación in situ fluorescente.

1. Introduction

Williams-Beuren Syndrome (WBS) is a rare genetic disorder that is autosomal dominant and occurs due to a chromosomal microdeletion in region 7q11.23, which varies in size from 1.5 to 1.8 Mb and contains approximately 28 genes (Pober, 2010; Kozel et al., 2021; Carlotto et al., 2023). This syndrome has many cardinal features, with the most common clinical characteristics associated with the syndrome being intellectual and learning disabilities, distinct facial features, short stature, hypersocial behavior, and many malformations such as cardiac, endocrine, skeletal, gastrointestinal, and ophthalmological (Twite et al., 2019; Serrano-Juárez et al., 2022; Zhou et al., 2022).

The diagnosis for WBS is normally clinical, as many characteristics are typical of the syndrome. However, cytogenomic analyses such as fluorescence in situ hybridization (FISH) can be used for better etiological characterization of the syndrome after clinical diagnosis. This exam is the gold standard in cytogenomic analysis for the diagnosis of microdeletion syndromes (Carlotto et al., 2023). Thus, the objective of this study we report the case of a boy from Manaus/Amazonas with the presence of a deletion in region 7q11.23, resulting in Williams-Beuren Syndrome. This case highlights the importance of cytogenomic analyses for the diagnosis of this syndrome, as well as the appropriate clinical follow-up, allowing for a more adequate management plan for the patient and genetic counseling.

2. Methodology

The report is a quantitative approach of the case report type according to Casarin and Porto (2021), reporting a case of a boy with Williams-Beuren Syndrome presenting a microdeletion in the 7q11.23 region in Manaus/Amazonas. The cytogenetic analyzes were carried out at the Laboratory of Cytogenetics of the University of the State of Amazonas – UEA. The metaphase mitotic chromosomes obtained from second peripheral blood lymphocyte culture Moorhead et al. (1960) and, subsequently, the second Seabright GTC banding technique (1971) was performed for the patient. Furthermore, the in situ hybridization technique was performed by fluorescence using the WBSCR region detection probe (7q11.23, Williams-Beuren), according to the manufacturer's protocol.

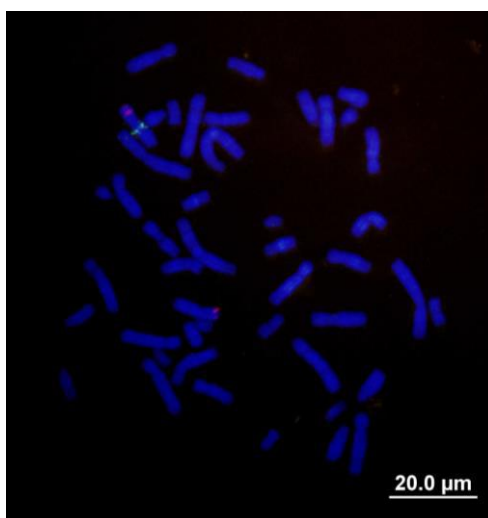
The project has been approved by the Research Ethics Committee (CEP), being protected by the ethical questions of secrecy and identification of subjects. The CAAE approval number is 95704617.0.0000.5016, number 2.988.971. The Informed Consent Form (TCLE) was signed and authorized by the patient's guardian.

3. Results

The patient is male, 12 years of age, and was sent to the genetic ambulatory to be evaluated by a geneticist doctor due to the likelihood of him having a genetic syndrome. The patient is the son of a non-consanguineal couple with no family history of hereditary diseases. A physical exam showed an elfin face with a short nasal bridge, full lips, frequent smile, short stature, learning difficulties, dysplasia of atrioventricular valves with mild insufficiency, and a cyst in the left kidney. The Term of Free and Informed Consent (TCLE) was given to the parents/ legal guardians of the patient, being appropriately filled out and signed.

Cytogenetic and cytogenomic analyses were performed on the patient. The karyotype analysis using G-banding (resolution of 400 bands, and 100 cells analyzed) revealed a 46, XY karyotype. The fluorescence in situ hybridization (FISH) was done with Saethre-Chotzen probe in region TWIST (7p21.1, spectrum red)/Williams-Beuren region WBSCR (7q11.23, spectrum green)/Probe Combination, and revealed a deletion in the WBSCR region (Figure 1).

Figure 1 - Karyotyping by FISH of the patient from Manaus, Amazonas with Williams-Beuren syndrome. Patient with 46,XY, presence of deletion in the region WBSCR (7q11.23, red signal) and absence of deletion in the region TWIST (green signal). The chromosomes were counterstained with DAPI. Scale bar equal to 20 μ m.



Source: Authors,

In Figure 1, it is important to note the presence of just one red signal on one of chromosomes 7, corresponding to a deletion in the 7q11.23 region, confirming Williams-Beuren syndrome. The patient returned to the geneticist doctor and was diagnosed with WBS. Currently, the patient is being cared for by a multidisciplinary team, with emphasis on psychological, speech, and occupational therapies, ensuring a better quality of life.

4. Discussion

Deletion mechanisms are associated with highly repetitive regions in low copy repeats (LCRs), and these regions are present in 5% of the human genome. Such regions act as a substrate for inter or intrachromosomal non-allelic homologous

recombination during meiosis, which can cause a deletion of one or more genes, as seen in region 7q11.23 (Lupski, 1998; Bayes et al., 2003).

Around 28 genes are involved in region 7q11.23. The deletion of this region is associated with WBS. A Williams-Beuren syndrome diagnosis is attained by analyzing the clinical characteristics along with cytogenomic analysis, such as FISH using commercial probes targeting region WBSCR (Crespi and Procyshyn, 2017; Byoun et al., 2021; Carlotto et al., 2023). Other cytogenomic analyses have also been used to identify region 7q11.23 associated with WBS that can offer more information on the deleted region, deletion size, and the genes affected.

In this study, the patient presented a deletion in region WBSCR in a single chromosome of pair 7, corresponding to a critical region for Williams-Beuren syndrome, confirming the deletion of chromosomal region 7q11.23 with FISH. This deletion is characterized as a hemizyosity because there is the loss of a gene copy, and the remaining copy is not able to express its genes in sufficient levels, resulting in genetic haploinsufficiency of the deleted region (Sullivan, 2019; Morrill and Amon, 2019). The effects of hemizyosity of each gene involved in 7q11.23 are not yet completely established, only the elastin gene (ELN) is well characterized as to its correlation to the genotype-phenotype of WBS. The elastin gene encodes crucial building blocks for the elastin protein, which is an important component of the elastic fibers of connective tissue (Kruszka et al., 2018; Kozel et al., 2021). Thus, haploinsufficiency of the elastin gene is associated with many characteristics found in patients with WBS, such as cardiovascular problems, skin elasticity issues, raspy voice, joint hypermobility, clinodactyly, inguinal hernia, premature aging, diverticulitis, and distinct craniofacial characteristics. Haploinsufficiency of a single gene located in the deleted critical region has been considered the main cause of the WBS phenotype (Johnson et al., 2019). Therefore, it is evident that the elastin gene is related to the clinical characteristics of the patient in this study.

de Souza et al. (2007) analyzed 18 patients with a clinical diagnosis of WBS and confirmed the deletion of critical region 7q11.23 using FISH, highlighting that FISH was important for determining the medical diagnosis. Cohen et al. (2012) reported a monozygotic twin with subtle facial dysmorphism, stunted growth, and renal abnormalities presenting a deletion in critical region 7q11.23 identified using FISH. Kalantari et al. (2023) described the case of a patient with typical characteristics of WBS, whose cytogenomic diagnosis revealed a germinative mosaic for deletion 7q11.23.

5. Conclusion

In conclusion, the present case report highlights the importance of cytogenomic analyses for differential diagnosis, which reveals the deletion of region 7q11.23, resulting in Williams-Beuren syndrome. Additionally, the early diagnosis of this syndrome aids in improved therapeutic conduct, allowing for adequate prognosis, genetic counseling, and medical decision-making, conferring a better quality of life for the patient. Future studies with molecular studies are necessary to better understand molecular mechanisms involved in this disease, such as identify the size and which LCRs are involved in this deletion are necessary.

Acknowledgments

We would like to thank Dr. Eliana Feldberg and the company Cytocell. This research was financially supported by the Fundação de Amparo à Pesquisa do Estado do Amazonas (FAPEAM), Brazil; and the Coordenação de Aperfeiçoamento de Pessoal de Nível Superior (CAPES), Brazil.

References

- Bayes, M., Magano, L. F., Rivera, N., Flores, R. & Perez Jurado, L. A. (2003). Mutational mechanisms of Williams–Beuren syndrome deletions. *The American Journal of Human Genetics*, 73(1):131–51.
- Byoun, J. T., Cho, J. Y., Yun, K. H., Rhee, S. J., Yu, S. T. & Oh, S. J. (2021). Mid-Aortic Syndrome in Williams-Beuren Syndrome with an Atypical Small-Sized Deletion of Chromosome 7q11.23 Misdiagnosed as Takayasu Arteritis. *International Heart Journal*, 62 (1): 207-210.
- Carlotto, B. S., Deconte, D., Diniz, B. L., da Silva, P. R., Zen, P. R. G. & da Silva, A. A. (2023). Fluorescence in situ hybridization (FISH) as an irreplaceable diagnostic tool for Williams-Beuren syndrome in developing countries: a literature review. *Revista Paulista de Pediatria*, 10 (42): e2022125.
- Casarin, S. T. & Porto, A. R. (2021). Relato de Experiência e Estudo de Caso: algumas considerações. *Journal of Nursing and Health*, 11(2): e2111221998.
- Cohen, L., Samanich, J., Panb, Q., Mehta, L. & Mariona, R. (2012). 17q12 Deletion in a patient with Williams syndrome: Case report and review of the literature. *Journal of Pediatric Genetics*, 2: 135–141.
- Crespi, B. J. & Procyshyn, T. L. (2017). Williams syndrome deletions and duplications: Genetic windows to understanding anxiety, sociality, autism, and schizophrenia. *Neuroscience and Biobehavioral Reviews*, 79: 14–26.
- de Souza, D. H., Moretti-Ferreira, D. & Rugolo, L. M. S. S. (2007). Fluorescent in situ hybridization (FISH) as a diagnostic tool for Williams-Beuren syndrome. *Genetics and Molecular Biology*, 30 (1): 17- 20.
- Johnson, A. F., Nguyen, H.T., & Veitia, R. A. (2019). Causes and effects of haploinsufficiency. *Biological reviews of the Cambridge Philosophical Society*, 94(5): 1774-1785.
- Kalantari, S., Biagio, M. D., Valente, E. M., Rossi, E. & Sirchia, F. (2023). Mosaic Williams syndrome: A case report. *American Journal of Medical Genetics Part A*, 191(1):249-252.
- Kozel, B. A., Baral, B., Kim, C. A., Maryis, C. B., Osborne, L. R., Porter, M. & Pober, B. (2021). Williams syndrome. *Nature Reviews*, 7: 1-22.
- Kruszka, P., Porras, A. R., Souza, D. H., Moresco, A., Huckstadt, V., Gil, A. D. et al. (2018). Williams–Beuren syndrome in diverse populations. *American Journal of Medical Genetics Part A*, 176(5):1128-1136.
- Lupski, J. R. (1998). Genomic disorders: Structural features of the genome can lead to DNA rearrangements and human disease traits. *Trends Genetics*. 14: 417–422.
- Moorhead, P. S., Nowell, P. C., Mellman, W. J., Battips, D. M., & Hungerford, D.A. (1960). Chromosome preparations of leukocytes cultured from human peripheral blood. *Experimental Cell Research*, 20: 613–616.
- Morrill, A. A. & Amon, A. (2019). Why haploinsufficiency persists. *Proceedings of the National Academy of Sciences*, 116(24): 11866-11871.
- Pober, B. R. (2010). Williams-Beuren syndrome. *The New England Journal of Medicine*, 362-239.
- Serrano - Juárez, C. A., Corona, B. P., Rodríguez-Camacho, M., Sandoval-Lira, L., Villalva-Sánchez, A. F., Yáñez-Téllez, M. G. & López, M. F. R. (2023). Neuropsychological Genotype–Phenotype in Patients with Williams Syndrome with Atypical Deletions: A Systematic Review *Neuropsychology Review*, 33(4): 891-911.
- Seabright, M. (1971). A rapid banding technique for human chromosomes. *Lancet*, 2(7731): 971-972.
- Sullivan, K. E. (2019). Chromosome 22q11.2 deletion syndrome and DiGeorge syndrome. *Immunological Reviews*, 287: 186–201.
- Twite, M. D., Stenquist, S. & Ing, R. J. (2019). Williams syndrome. *Pediatric Anesthesia*, 29: 483 - 490.
- Zhou, J., Zheng, Y., Liang, G., Xu, X., Liu, J., Chen, S., Gel, T., Wen, P., Zhang, Y., Liu, X., Zhuang, J., Wu, Y. & Chen, J. (2022). Atypical deletion of Williams–Beuren syndrome reveals the mechanism of neurodevelopmental disorders. *BMC Medical Genomics*, 15:79