

Differentiation between Hemolytic Uremic Syndrome and Thrombotic Thrombocytopenic Purpura: A comparison of key laboratory findings between 2010 and 2021

Diferenciação entre Síndrome Hemolítico-Urêmica e Púrpura Trombocitopênica Trombótica: Uma comparação chave dos achados laboratoriais entre 2010 e 2021

Diferenciación entre el Síndrome Urémico Hemolítico y la Púrpura Trombocitopénica Trombótica: Comparación de los principales hallazgos de laboratorio entre 2010 y 2021

Received: 12/16/2024 | Revised: 12/21/2024 | Accepted: 12/21/2024 | Published: 12/23/2024

Matheus Ventura Pereira¹

ORCID: <https://orcid.org/0000-0001-7209-477X>

School of Health, Brazilian Institute of Medicine and Rehabilitation, Brazil

E-mail: Mathyp96@gmail.com

Emanoelle Gomes Pereira¹

ORCID: <https://orcid.org/0009-0008-5303-5932>

School of Health, Brazilian Institute of Medicine and Rehabilitation, Brazil

E-mail: emanoelle22@hotmail.com

Kevin Fernandes Carriolo de Melo¹

ORCID: <https://orcid.org/0009-0009-0174-8225>

School of Health, Brazilian Institute of Medicine and Rehabilitation, Brazil

E-mail: kevinfcdmelo@hotmail.com

Gabriella Oliveira Alves Moreira de Carvalho²

ORCID: <https://orcid.org/0000-0001-6198-7054>

Federal University of Rio de Janeiro, Brazil

E-mail: gabriellacarvalho_15@yahoo.com.br

Michel Alexandre Villani Gantus³

ORCID: <https://orcid.org/0000-0003-3799-3176>

State University of Rio de Janeiro, Brazil

E-mail: Michel.gantus@gmail.com

Fabio Pereira Mesquita-Santos³

ORCID: <https://orcid.org/0009-0001-8916-417X>

State University of Rio de Janeiro, Brazil

E-mail: fabiomesquitarij@gmail.com

Fabio da Silva de Azevedo Fortes³

ORCID: <https://orcid.org/0000-0003-2385-6023>

State University of Rio de Janeiro, Brazil

E-mail: fabio.fortes.uerj@gmail.com

Anderson Jack Franzen⁴

ORCID: <https://orcid.org/0000-0002-3171-5143>

State University of Rio de Janeiro, Brazil

E-mail: ajfranzen@gmail.com

Abstract

Objective: This article aims to analyze and compare the clinical and laboratory findings related to Thrombotic Microangiopathies (TMAs), specifically Hemolytic Uremic Syndrome (HUS) and Thrombotic Thrombocytopenic Purpura (TTP), to support diagnostic and therapeutic decisions. The study also explores critical biochemical and hematological markers to differentiate these diseases. **Methodology:** A systematic literature review was conducted using articles from PubMed, Scielo, and Google Scholar, focusing on studies published from 2010 to mid-2021, covering a ten-year period. The review included research on clinical presentations, laboratory findings, and the molecular mechanisms underlying HUS and TTP. **Results:** The analysis revealed significant overlaps in clinical manifestations, such as anemia, thrombocytopenia, and renal dysfunction, but distinct differences in their pathophysiologies. HUS is associated with complement system dysfunction and Shiga toxin-mediated damage, while

¹ School of Health, Brazilian Institute of Medicine and Rehabilitation - IBMR, Rio de Janeiro - RJ, Brazil.

² Federal University of Rio de Janeiro - UFRJ, Rio de Janeiro, RJ, Brazil.

³ State University of Rio de Janeiro – UERJ, Rio de Janeiro, RJ, Brazil.

⁴ State University of Rio de Janeiro – UERJ, Rio de Janeiro, RJ, Brazil. Corresponding author.

TTP is linked to ADAMTS13 enzyme deficiency. Laboratory markers such as lactate dehydrogenase, bilirubin, and platelet count were identified as crucial for differentiating the two conditions. Unique Contribution to Theory, Policy, and Practice: Underscoring the critical clinical and laboratory distinctions between HUS and TTP, this study provides a comprehensive framework for achieving precise diagnoses and developing individualized treatment strategies. Enhancing diagnostic accuracy is paramount to mitigating treatment delays, minimizing complications, and improving patient outcomes. Moreover, this review highlights the imperative need for standardizing diagnostic protocols for TMAs and advocates for further research to address existing knowledge gaps in this field.

Keywords: Hemolytic Uremic Syndrome; Thrombotic Thrombocytopenic Purpura; Microangiopathies; Biomarkers.

Resumo

Objetivo: Este artigo tem como objetivo analisar e comparar os achados clínicos e laboratoriais relacionados às Microangiopatias Trombóticas (ATMs), especificamente a Síndrome Hemolítico-Urêmica (SHU) e a Púrpura Trombocitopênica Trombótica (PTT), para subsidiar decisões diagnósticas e terapêuticas. O estudo também explora marcadores bioquímicos e hematológicos críticos para diferenciar essas doenças. Metodologia: Foi realizada uma revisão sistemática da literatura utilizando artigos do PubMed, Scielo e Google Scholar, com foco em estudos publicados de 2010 a meados de 2021, abrangendo um período de dez anos. A revisão incluiu pesquisas sobre apresentações clínicas, achados laboratoriais e os mecanismos moleculares subjacentes à SHU e PTT. Resultados: A análise revelou sobreposições significativas nas manifestações clínicas, como anemia, trombocitopenia e disfunção renal, mas diferenças distintas em suas fisiopatologias. A SHU está associada à disfunção do sistema complemento e danos mediados pela toxina Shiga, enquanto a PTT está ligada à deficiência enzimática ADAMTS13. Marcadores laboratoriais como lactato desidrogenase, bilirrubina e contagem de plaquetas foram identificadas como cruciais para diferenciar as duas condições. Contribuição única para teoria, política e prática: Ressaltando as distinções clínicas e laboratoriais críticas entre SHU e PTT, este estudo fornece uma estrutura abrangente para obter diagnósticos precisos e desenvolver estratégias de tratamento individualizadas. Aumentar a precisão do diagnóstico é fundamental para mitigar atrasos no tratamento, minimizar complicações e melhorar os resultados dos pacientes. Além disso, esta revisão destaca a necessidade imperativa de padronizar protocolos de diagnóstico para TMAs e defende mais pesquisas para abordar as lacunas de conhecimento existentes neste campo.

Palavras-chave: Síndrome Hemolítico-Urêmica; Trombocitopênica Trombótica Púrpura; Microangiopatias; Biomarcadores.

Resumen

Objetivo: Este artículo tiene como objetivo analizar y comparar los hallazgos clínicos y de laboratorio relacionados con las Microangiopatías Trombóticas (TMA), específicamente el Síndrome Urémico Hemolítico (SUH) y la Púrpura Trombocitopénica Trombótica (PTT), para apoyar las decisiones diagnósticas y terapéuticas. El estudio también explora marcadores bioquímicos y hematológicos críticos para diferenciar estas enfermedades. Metodología: Se realizó una revisión sistemática de la literatura utilizando artículos de PubMed, Scielo y Google Scholar, centrándose en estudios publicados desde 2010 hasta mediados de 2021, cubriendo un período de diez años. La revisión incluyó investigaciones sobre las presentaciones clínicas, los hallazgos de laboratorio y los mecanismos moleculares subyacentes al SUH y la TTP. Resultados: El análisis reveló solapamientos significativos en las manifestaciones clínicas, como anemia, trombocitopenia y disfunción renal, pero claras diferencias en sus fisiopatologías. El síndrome urémico hemolítico se asocia con la disfunción del sistema del complemento y el daño mediado por la toxina Shiga, mientras que el TTP está relacionado con la deficiencia de enzimas ADAMTS13. Los marcadores de laboratorio como la lactato deshidrogenasa, la bilirrubina y el recuento de plaquetas se identificaron como cruciales para diferenciar las dos afecciones. Contribución única a la teoría, la política y la práctica: Subrayando las distinciones clínicas y de laboratorio críticas entre el SUH y la TTP, este estudio proporciona un marco integral para lograr diagnósticos precisos y desarrollar estrategias de tratamiento individualizadas. Mejorar la precisión diagnóstica es primordial para mitigar los retrasos en el tratamiento, minimizar las complicaciones y mejorar los resultados de los pacientes. Además, esta revisión pone de relieve la necesidad imperiosa de estandarizar los protocolos de diagnóstico para las TMA y aboga por más investigaciones para abordar las lagunas de conocimiento existentes en este campo.

Palabras clave: Síndrome Urémico Hemolítico; Trombocitopénica Trombótica Púrpura; Microangiopatias; Biomarcadores.

1. Introduction

Thrombotic Thrombocytopenic Purpura (TTP) and Hemolytic Uremic Syndrome (HUS) are the two classic phenotypic manifestations of Thrombotic Microangiopathies (TMAs) (Polito & Kirsztajn, 2010; Bayer et al., 2019). TMAs are pathological conditions characterized by microangiopathic hemolytic anemia (caused by shear stress in the microcirculation), widespread microvascular occlusion due to platelet-rich thrombus deposition (with common renal involvement), and

thrombocytopenia (platelet consumption) (Kavanagh et al., 2014; Leisring, Brodsky & Parikh, 2024). Due to their similar clinical manifestations, these diseases were previously considered a single condition (Pessegueiro & Pires, 2005).

There are two types of HUS: (1) Typical Syndrome (HUS+D), originating from a bacterial infection associated with diarrhea, and Atypical Syndrome (HUS-D), which develops due to an imbalance in the complement alternative pathway (Kavanagh et al., 2014; Java, 2024). HUS+D is more prevalent in children than in adults (Polito & Kirsztajn, 2010). HUS is a severe disease responsible for 2 cases per 100,000 of acute renal failure in the global pediatric population (Vaisbich, et al., 2013; Vaisbich, 2014).

Mutations (gene modifications) and polymorphisms (morphological changes in genes) in complement regulatory proteins can trigger atypical HUS. Approximately 60% of atypical HUS cases have loss-of-function mutations in genes encoding complement regulatory proteins, which protect host cells from complement activation. These include mutations in complement factor H (CFH), factor I (CFI), membrane cofactor protein (MCP or CD46), or gain-of-function mutations in genes encoding CFH or complement component 3 (C3) (Kavanagh et al., 2014).

In typical HUS, one etiology is the ingestion of food contaminated with Shiga toxin-producing *Escherichia coli* (Stx). The infection often begins with diarrhea and can progress to typical Hemolytic Uremic Syndrome (HUS+D) if the bacteria cross the intestinal epithelium into the bloodstream, infecting renal endothelial cells. The toxin consists of five identical B subunits responsible for binding holotoxin (deacetylated holomycin) to globotriaosylceramide (GB3), a glycopeptide on the cell surface, and a subunit A responsible for its biological action, cleaving ribosomal RNA and inhibiting protein synthesis in host cells (Caires, 2012).

In these cells, after Shiga toxin binds to GB3 receptors, damage to small vessels occurs due to inhibited protein synthesis. These lesions activate platelets and form kidney thrombi, causing vascular occlusion and increased renal microvascular pressure, leading to shear-induced red blood cell rupture (Polito & Kirsztajn, 2010).

TTP differs from HUS as a microangiopathy involving diffuse microcirculatory occlusion, potentially leading to ischemia in any tissue. The disease's onset reflects the absence or deficiency of a protein synthesized by the liver and released into the bloodstream: ADAMTS13, which cleaves von Willebrand factor (vWF). This factor mediates platelet adhesion and vascular damage. ADAMTS13 deficiency or absence arises from mutation, liver damage, or autoimmune disease. Consequently, vWF multimers excessively accumulate in plasma, causing circulating platelets to adhere to these multimers, forming microvascular thrombi. The resulting vessel occlusion explains hemolysis and platelet consumption, leading to non-immune hemolytic anemia and thrombocytopenia (Tonaco et al., 2010; Hansen, Nilsson & Frederiksen, 2021).

Three characteristic laboratory findings in HUS are known: acute kidney failure due to toxin-induced glomerular tissue damage, thrombocytopenia resulting from platelet activation and thrombus formation, and hemolytic anemia caused by mechanical red blood cell destruction (Polito & Kirsztajn, 2010). Currently, TTP's laboratory findings are well recognized: microangiopathic hemolytic anemia and thrombocytopenia (Tonaco et al., 2010). Symptoms may vary depending on the organs affected by ischemia (Polito & Kirsztajn, 2010; Tonaco et al., 2010). Due to the similarity between the syndromes described, understanding HUS and TTP laboratory data is critical to assist in determining the pathology and guiding clinical actions (Polito & Kirsztajn, 2010).

Considering the significance of this topic, this study compares the clinical and laboratory findings of these microangiopathies with distinct etiologies, with the goal of assisting healthcare professionals in making precise diagnoses through comprehensive data analysis.

In this way, this article aims to analyze and compare the clinical and laboratory findings related to Thrombotic Microangiopathies (TMAs), specifically Hemolytic Uremic Syndrome (HUS) and Thrombotic Thrombocytopenic Purpura (TTP), to support diagnostic and therapeutic decisions.

2. Methodology

2.1 Research Sources

This study is configured as a systematic review of literature (Gomes & Caminha, 2014) with a quantitative approach in counting the number of articles and a qualitative approach in analyzing them and a descriptive character (Pereira et al., 2018).

Data were identified through a systematic search of electronic databases (NCBI, PubMed, Scielo, Google Scholar), journals such as the Brazilian Journal of Nephrology, with the final search conducted on April 22, 2024.

2.2 Eligibility Criteria

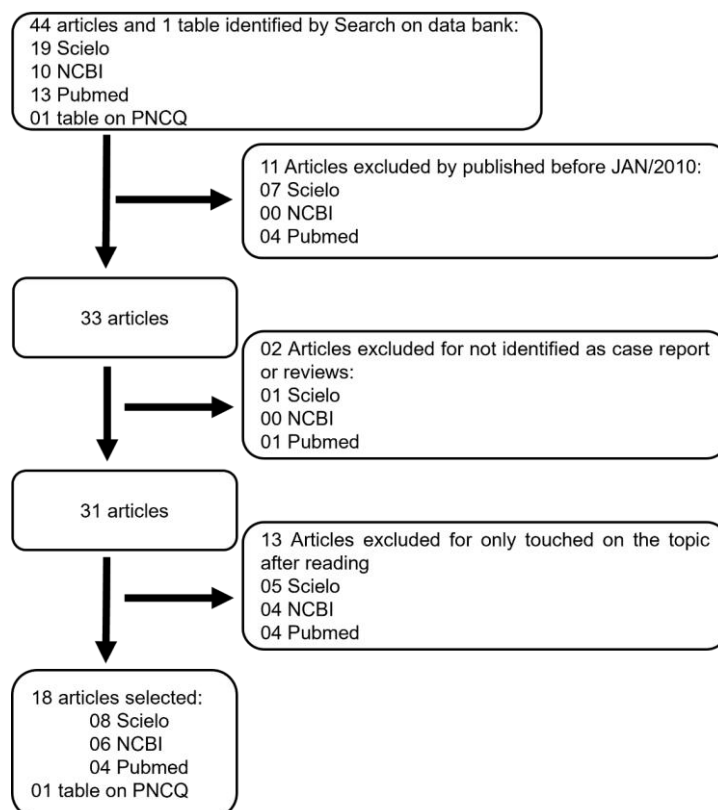
Studies were deemed eligible if they were: (1) Literature reviews on typical or atypical Hemolytic Uremic Syndrome; (2) Literature reviews on Thrombotic Thrombocytopenic Purpura; (3) Case reports of the aforementioned pathologies; (4) Published after January 2010.

There were no restrictions based on language or nationality of the articles.

2.3 Articles Selection

The authors independently reviewed the titles and abstracts of the studies identified during the searches. Full-text versions were obtained and reviewed as necessary to determine if they met the predefined inclusion criteria. A discussion regarding one article (Pessegueiro & Pires, 2005) was conducted, as the study predates the eligibility cut-off date (2010). However, it was included due to its historical relevance to the pathologies discussed. The criteria for exclusion and the number of articles reviewed are shown in Figure 1.

Figure 1 - Summary of Study Selection.



Source: Authors.

3. Results

A total of 44 articles were reviewed. Titles and abstracts were meticulously analyzed, leading to the exclusion of 26 studies. Of these excluded articles: 11 were published before January 2010, 2 were not case reports or literature reviews, 13 deviated from the research focus. These 13 studies included patients with other conditions or pathologies, such as cancer and autoimmune anemias, shifting focus away from the targeted microangiopathies (Table 1).

The systematic search identified 18 studies, with 10 being case reports: 5 on Hemolytic Uremic Syndrome and 5 on Thrombotic Thrombocytopenic Purpura. No age or gender restrictions were imposed on patients.

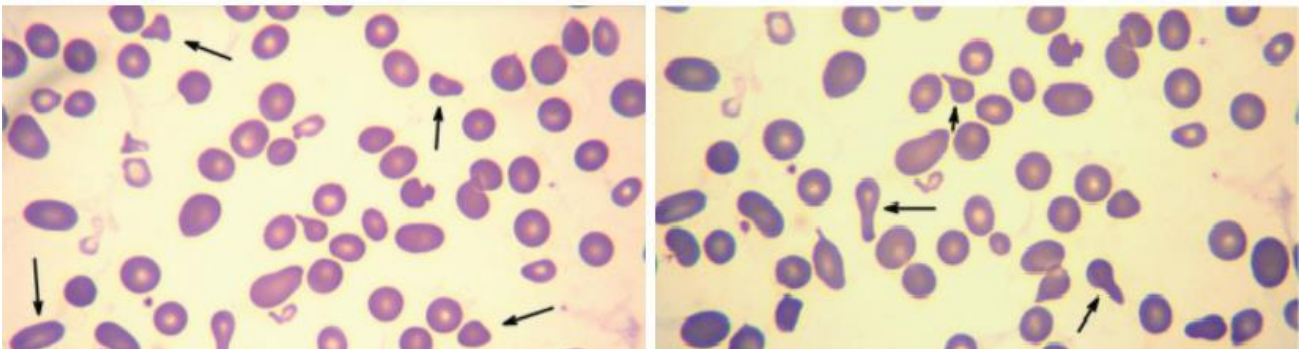
3.1 Hematimetric Indices

All studies analyzed reported hemoglobin (Hgb) values ≤ 10 g/dL (Reis et al, 2019; Farias et al., 2016; Vaisbich et al, 2013; Nieto-Rios et al., 2020; Drumond et al., 2018; Yates et al., 2014; Van Balen et al., 2014; Pérez-Cruz et al., 2017; Schapkaitz & Schickerling, 2018; Wang et al., 2018), ranging from 3.4 to 8.2 g/dL in TTP and from 3.9 to 10.4 g/dL in HUS, with severe cases (Hgb < 5 g/dL) (Farias et al., 2016; Vaisbich et al., 2013; Drumond et al., 2018; Schapkaitz & Schickerling, 2018; Van Balen et al., 2014). Nine studies reported the presence of schistocytes (Reis et al, 2019; Farias et al., 2016; Vaisbich et al, 2013; Nieto-Rios et al., 2020; Drumond et al., 2018; Yates et al., 2014; Pérez-Cruz et al., 2017; Schapkaitz & Schickerling, 2018; Wang et al., 2018). One study highlighted the presence of dacrocytes (Pérez-Cruz et al., 2017), and another reported acanthocytes (Reis et al, 2019).

In the cases analyzed, platelet counts at hospital admission did not exceed $80,000/\text{mm}^3$ (Reis et al, 2019; Farias et al., 2016; Vaisbich et al, 2013; Nieto-Rios et al., 2020; Drumond et al., 2018; Van Balen et al., 2014; Pérez-Cruz et al., 2017; Schapkaitz & Schickerling, 2018; Wang et al., 2018). In some instances, platelet counts were below $18,000/\text{mm}^3$ at admission (Reis et al, 2019; Nieto-Rios et al., 2020; Van Balen et al., 2014; Schapkaitz & Schickerling, 2018).

The studies also highlighted the indirect Coombs test, which confirmed that the anemia observed in these cases was non-immune (Reis et al, 2019; Farias et al., 2016; Vaisbich et al, 2013; Nieto-Rios et al., 2020; Drumond et al., 2018; Yates et al., 2014; Van Balen et al., 2014; Pérez-Cruz et al., 2017; Schapkaitz & Schickerling, 2018; Wang et al., 2018).

Figure 2 - HEMATIMETRIC INDICES. Presence of schistocytes (arrows), fragmented erythrocytes with irregular morphology (a). Dacrocytes (arrows), tear-shaped or drop-shaped red blood cells (b).



Source: Drumond et al (2018).

Table 1 - summary of study characteristics.

Article	Symptoms	Sex and Age	SHU	Hemoglobin	Platelets	Urea	Creatinine	DHL	BT and fractions	Indirect Bilirubin	Haptoglobin
REIS, Sofia et al., 2019	Patient with bloody-mucoid diarrhea, abdominal pain, pallor, and jaundice.	Woman; 8 years	Case 1	10,3 g/dL	14000	102 mg/dL	1,30 mg/dL	4055 ui/L	-	-	< 0,07
VAISBICH, Maria Helena, et al., 2013	Patient previously diagnosed with anemia and thrombocytopenia, later evaluated by another service and diagnosed with Evans syndrome. After receiving a red blood cell transfusion and undergoing 4 sessions of pulse therapy, hemolytic anemia, hypogammaglobulinemia, hypoalbuminemia, nephrotic proteinuria, renal function alterations, and dysmorphic hematuria were detected.	Man; 14 months	Case 2	4,1 g/dL	63000	111 mg/dL	1,12 mg/dL	1647 ui/L	-	-	< 10
FARIAS, João Samuel, et al., 2015	Patient presented with paleness, dyspnea, nausea, and oliguria.	Woman; 35 years	Case 3	3,9 g/dL	83000	167 mg/dL	13,7 mg/dL	875 ui/L	7,07 mg/dL	5,25 mg/dL	-
NIETO-RIOS, John, et al., 2020	Patient with diabetic nephropathy undergoing hemodialysis. Received a kidney transplant from a deceased donor. After 4 months, reports asthenia, adynamia, hyporexia, sensory disturbance, oliguria, and edema. Reports scant liquid diarrhea without bleeding and abdominal pain in the previous week.	Man; 63 years	Case 4	9,1 g/dL	18000	-	3,04 mg/dL	2674 ui/L	0,96 mg/dL	-	< 8
PÉREZ-CRUZ, Fabiel, et al., 2017	Patient with abdominal pain, bloody diarrhea, and nausea.	Woman; 67 years	Case 5	10,4 g/dL	59000	107 mg/dL	5,19 mg/dL	1125 ui/L	1,80 mg/dL	-	< 6,63
			PTT								
DRUMOND, João Paulo, et al., 2017	Patient complains of malaise and weakness for months, with worsening over the last 5 days, experiencing generalized bone pain, headaches, visual disturbances, and one episode of seizure.	Woman; 41 years	Case 1	4,9 g/dL	53000	20 mg/dL	0,70 mg/dL	3325 ui/L	1,60 mg/dL	1,07 mg/dL	-
YATES, Sean, et al., 2014	Patient previously diagnosed with autoimmune TTP; over 14 years had 8 relapses characterized by a decrease in ADAMTS13 protease and its inhibitor. After the 7th relapse, became dependent on blood transfusions.	Woman; 48 years	Case 2	8,2 g/dL	106000	-	0,76 mg/dL	447 ui/L	-	-	-
BALEN, Tessa, et al., 2013	Patient with malaise, sore throat, myalgia, and weight loss. Prescribed antibiotics, and after 10 days experienced excessive fatigue and high body temperature	Woman; 16 years	Case 3	4,1 g/dL	6000	-	-	1008 ui/L	-	-	< 0,08
SCHAPKAITZ, Elise, et al., 2018	Patient with body aches and fatigue; after hospitalization, was lethargic and vomiting. Upon evaluation, was afebrile, with severe pallor, mild jaundice, mild hematuria, and cervical and axillary lymphadenopathy.	Man; 5 years	Case 4	3,4 g/dL	10000	46,5 mg/dL	0,42 mg/dL	2724 ui/L	1,87 mg/dL	-	> 0,1
WANG, Xiaoya, et al., 2018	Patient with chest discomfort and dyspnea for 7 hours.	Man; 87 years	Case 5	7,7 g/dL	38000	95,9 mg/dL	2,62 mg/dL	13976 ui/L	<0,1 mg/dL	1,12 mg/dL	-
	reference value			12-18 g/dL	150000 - 400000	13-43mg/dL	0,6-1,3 mg/dL	120-246 ui/L	>1,2 mg/dL	>0,8 mg/dL	25-190 mg/dL

Source: Data compiled and analyzed by the authors.

3.2 Biochemical Markers

In our analysis, certain tests were frequently requested, such as urea (Reis et al, 2019; Farias et al., 2016; Vaisbich et al, 2013; Drumond et al., 2018; Pérez-Cruz et al., 2017; Schapkaitz & Schickerling, 2018; Wang et al., 2018), which ranged from 20 mg/dL to 167 mg/dL; creatinine (Reis et al, 2019; Farias et al., 2016; Vaisbich et al, 2013; Nieto-Rios et al., 2020; Drumond et al., 2018; Yates et al., 2014; Pérez-Cruz et al., 2017; Schapkaitz & Schickerling, 2018; Wang et al., 2018), ranging from 0.7 mg/dL to 13.7 mg/dL; and lactate dehydrogenase (LDH) (Reis et al, 2019; Farias et al., 2016; Vaisbich et al, 2013; Nieto-Rios et al., 2020; Drumond et al., 2018; Yates et al., 2014; Van Balen et al., 2014; Pérez-Cruz et al., 2017; Schapkaitz & Schickerling, 2018; Wang et al., 2018), ranging from 447 to 2,724 IU/L.

Urea and creatinine levels were predominantly elevated, demonstrating that HUS primarily affects the kidneys. In TTP cases, these markers may also increase but not as significantly as in Hemolytic Uremic Syndrome (Reis et al, 2019; Farias et al., 2016; Vaisbich et al, 2013; Nieto-Rios et al., 2020; Pérez-Cruz et al., 2017).

In HUS cases, all renal markers (urea and creatinine) were altered, with only two creatinine values within the reference range (Reis et al, 2019; Vaisbich et al, 2013) at 1.3 mg/dL and 1.12 mg/dL. One critical value was noted (13.7 mg/dL) (Farias et al., 2016), classified as critical (>7.4 mg/dL) (PNCQ, 20f19).

The monitoring of urea and creatinine aims to evaluate renal function, as both microangiopathies can affect various organs, with a higher incidence in the kidneys (HUS) or the nervous system (TTP) (Polito & Kirsztajn, 2010; Tonaco et al., 2010).

LDH values, an excellent marker for tissue damage, varied greatly (447 IU/L to 2,724 IU/L), with none falling below the reference range (120–246 IU/L).

Regarding indirect bilirubin levels (Farias et al., 2016; Drumond et al., 2018; Wang et al., 2018), which ranged from 1.07 to 5.25 mg/dL, distinct values for HUS and TTP were noted. Total bilirubin (Farias et al., 2016; Nieto-Rios et al., 2020; Drumond et al., 2018; Schapkaitz & Schickerling, 2018; Wang et al., 2018) ranged from <0.01 to 7.07 mg/dL. Other tests, such as haptoglobin (Reis et al, 2019; Vaisbich et al, 2013; Nieto-Rios et al., 2020; Van Balen et al., 2014; Pérez-Cruz et al., 2017; Schapkaitz & Schickerling, 2018), ranged from >0.1 to <6.63 mg/dL. Activity levels of the ADAMTS13 enzyme (Vaisbich et al, 2013; Nieto-Rios et al., 2020; Drumond et al., 2018; Yates et al., 2014; Van Balen et al., 2014; Wang et al., 2018) and antibodies against ADAMTS13 (Yates et al., 2014; Van Balen et al., 2014;) were also analyzed in selected studies, with the latter two directly associated with TTP cases (Tonaco et al., 2010).

4. Discussion

There is no standardized diagnostic approach for the studied microangiopathies, as demonstrated by variations in the types of tests requested and the range of values reported in laboratory analyses from the cases described in the literature. However, in some instances, more detailed follow-ups regarding laboratory data were found. In other articles, only a few tests were requested to establish the diagnosis. Additionally, another point worth highlighting is the lack of data on this topic, which posed one of the greatest challenges during the development of this study. For this reason, it was not possible to establish a standard regarding the age and gender of the cases studied.

Analyzing hematimetric indices, it is evident that both microangiopathies significantly impact hemoglobin levels, with only two of the ten studied cases remaining close to reference values (Reis et al, 2019; Pérez-Cruz et al., 2017), while the other observed cases showed a substantial decrease in this parameter. Regarding platelets, six out of ten cases demonstrated values above the critical state, which is justified by the fact that both diseases trigger platelet activation due to microvascular damage,

leading to thrombocytopenia and small vessel occlusion. This, in turn, results in hemolytic anemia caused by shear stress of red blood cells in these obstructed vessels (Polito & Kirsztajn, 2010).

In HUS cases, all renal markers (urea and creatinine) were altered, with only two creatinine values falling within the reference range (Reis et al, 2019; Vaisbich et al, 2013) at 1.3 mg/dL and 1.12 mg/dL. One value was deemed critical (13.7 mg/dL) (Farias et al., 2016;), being classified as critical (>7.4 mg/dL) (PNCQ, 2019). In TTP, only one of the reported patients presented altered values for both urea and creatinine (95.99 mg/dL and 2.62 mg/dL, respectively) (Wang et al., 2018), while another patient showed a slightly elevated urea value (46.25 mg/dL) (Schapkaitz & Schickerling, 2018). Since TTP involves diffuse microcirculatory occlusion, renal tissue damage may or may not occur, justifying why only one case exhibited significant or slight alterations in renal markers, as there is no guarantee that the kidneys will be the affected organs.

Comparing lactate dehydrogenase (LDH) levels reveals that both diseases exhibit high serum values of this enzyme, as its tissue concentration is approximately 500 times greater than its plasma concentration. In both pathologies, the kidneys and other organs are severely affected, causing LDH levels to rise drastically due to the enzyme's leakage from the cell interior into the bloodstream. LDH is a good indicator for assessing the extent of tissue damage caused by both microangiopathies. While not specific, it is an excellent marker for tissue injury. Among the studied cases, only two patients exhibited values below the critical threshold (<1,000 U/L) (PNCQ, 2019), though still above reference values (120–246 U/L). In the other cases, values ranged from 1,008 U/L (Van Balen et al., 2014) to 13,976 U/L (Wang et al., 2018).

Indirect bilirubin (also known as unconjugated or free bilirubin) has an apolar and liposoluble structure, making it unfilterable by renal glomeruli and, therefore, not excretable in urine (Martelli, 2010). During HUS+D, renal damage caused by Shiga toxin is a determining factor for the intense presence of abnormal red blood cells due to tissue injury and the consequent increase in blood flow pressure attempting to pass through platelet thrombi (Polito & Kirsztajn, 2010). Similarly, in HUS-D, glomerular microvascular lesions result from complement system dysregulation (Kavanagh et al., 2014).

Increased blood flow pressure causes massive red blood cell shear and the release of large quantities of hemoglobin. Following macrophage-mediated phagocytosis and the action of the heme oxygenase enzyme, hemoglobin is converted into biliverdin, carbon monoxide, and iron. Biliverdin reductase transforms biliverdin into free bilirubin, which is gradually released into the plasma by macrophages (Martelli, 2010). In contrast, TTP does not initially present a specific lesion, nor does it exhibit the same type of shear stress as HUS. Instead, blood flow is slow and fluid, as demonstrated in the values of the TTP patient compared to the HUS patient (Polito & Kirsztajn, 2010; Pessegueiro & Pires, 2005).

Haptoglobin is an acute-phase protein that almost irreversibly binds to hemoglobin following hemolysis. Situations with high free hemoglobin plasma concentrations generally occur when the haptoglobin system is overwhelmed, i.e., the hemolysis intensity surpasses the protein's half-life and production rate (Menegazzo, 2014). Only four of the reported cases provided data on haptoglobin levels. Comparing this marker with hemoglobin levels reveals that the lower the haptoglobin, the more severe the anemia. Data from Van Balen et al. (2014) and Schapkaitz and Schickerling (2018) reported haptoglobin values of <0.8 mg/dL for 4.1 g/dL hemoglobin and 0.1 mg/dL for 3.4 g/dL hemoglobin, respectively. Many authors advocate that low haptoglobin levels should be included as diagnostic criteria for hemolysis, alongside elevated bilirubin and LDH levels and the presence of schistocytes in peripheral blood smears (Menegazzo, 2014).

5. Conclusion

The two pathologies discussed in this study are challenging to diagnose and require immediate decision-making by a multidisciplinary team. Since both are thrombotic microangiopathies with similar clinical and laboratory signs, it is crucial for

healthcare professionals to be guided as accurately as possible to make the best decisions when these pathologies are suspected.

According to the data presented, the two thrombotic microangiopathies addressed in this article exhibit similar laboratory characteristics, such as non-immune hemolytic anemia and thrombocytopenia, which are explained by microvascular occlusion and shear stress. This similarity can initially make clinical indications confusing. However, with a more technical approach, it is possible to observe that in Hemolytic Uremic Syndrome (HUS), alterations in renal markers are consistent, whereas in Thrombotic Thrombocytopenic Purpura (TTP), such alterations are random due to diffuse occlusion, which may or may not affect glomerular tissue. Markers such as LDH (lactate dehydrogenase) and haptoglobin can help assess the severity of the damage caused by these diseases. LDH serves as a good parameter for identifying tissue damage, while haptoglobin is useful for evaluating hemolysis.

Thus, it can be concluded that although the studied diseases have distinct mechanisms of pathogenesis, they converge in many aspects when manifested, making their differential diagnosis challenging. Therefore, an integrated and competent multidisciplinary team is essential for achieving accurate diagnoses.

References

- Bayer, G., von Tokarski, F., Thoreau, B., Bauvois, A., Barbet, C., Cloarec, S., ... & Halimi, J. M. (2019). Etiology and outcomes of thrombotic microangiopathies. *Clinical Journal of the American Society of Nephrology*, 14(4), 557-566.
- Caires, T. A. (2012). Fisiopatologia e diagnóstico da síndrome hemolítica urêmica. *Academia de Ciência e Tecnologia*; 1(6), 10-11.
- Drumond, J. P. N., Abou-Arabi, R. M., Figueiredo, R. P., Mourão, V. N., Aiziro, J. B., Caly, D. N., & Cortez, A. J. P. (2018). Thrombotic thrombocytopenic purpura: a case report. *Jornal Brasileiro de Patologia e Medicina Laboratorial*, 54(4), 255-259.
- Farias, J. S. D. H., Cunha, J. P. P. D., Lagana, C. C. C., Gallucci, M. C., Chula, D. C., Soares, M. F., & Nascimento, M. M. (2016). Um caso de recuperação da função renal na síndrome hemolítico-urêmica tratada com eculizumab. *Jornal Brasileiro de Nefrologia*, 38(1), 137-141.
- Gomes, I. S., & Caminha, I. D. O. (2014). Guide to systematic review of studies: an option for the methodology of Human Movement Sciences. *Movimento-Porto Alegre*, 20(1), 395-411.
- Hansen, D. L., Nilsson, A. C., & Frederiksen, H. (2021). Thrombotic thrombocytopenic purpura. *Ugeskrift for Laeger*, 183(42), V03210230-V03210230.
- Java, A. (2024). Atypical hemolytic uremic syndrome: diagnosis, management, and discontinuation of therapy. *Hematology*, 2024(1), 200-205.
- Kavanagh, D., Raman, S., & Sheerin, N. S. (2014). Management of hemolytic uremic syndrome. *F1000Prime Reports*, 6.
- Leisring, J., Brodsky, S. V., & Parikh, S. V. (2024). Clinical evaluation and management of thrombotic microangiopathy. *Arthritis & Rheumatology*, 76(2), 153-165.
- Martelli, A. (2010). Síntese e metabolismo da bilirrubina e fisiopatologia da hiperbilirrubinemia associados à Síndrome de Gilbert: revisão de literatura. *Rev Med Minas Gerais*, 22(2), 216-220.
- Menegazzo, A. B. B. R. (2014). Determinação do valor da heptoglobina sérica para diagnóstico de hemólise na síndrome HELLP.
- Nieto-Ríos, J. F., Zuluaga-Quintero, M., Valencia-Maturana, J. C., Bello-Marquez, D. C., Aristizabal-Alzate, A., Zuluaga-Valencia, G. A., ... & Arias, L. F. (2020). Síndrome hemolítico-urêmica causada por *Escherichia coli* produtora de toxina Shiga em um relato de caso de receptor de transplante renal. *Brazilian Journal of Nephrology*, 43, 591-596.
- Pereira, A. S., Shitsuka, D. M., Parreira, F. J., & Shitsuka, R. (2018). *Metodologia da pesquisa científica*. [free e-book]. Santa Maria: Núcleo de Tecnologia Educacional da Universidade Federal de Santa Maria.
- Pérez-Cruz, F. G., Villa-Díaz, P., Pintado-Delgado, M. C., Fernández_Rodríguez, M. L., Blasco-Martínez, A., & Pérez-Fernández, M. (2017). Hemolytic uremic syndrome in adults: A case report. *World Journal of Critical Care Medicine*, 6(2), 135.
- Pessegueiro, P., & Pires, C. (2005). Síndrome hemolítico urémico/púrpura trombocitopênica trombótica. *Medicina Interna*, 12(2), 102-116.
- Polito, M. G., & Kirsztajn, G. M. (2010). Microangiopatias trombóticas: púrpura trombocitopênica trombótica e síndrome hemolítico-urêmica. *Brazilian Journal of Nephrology*, 32, 303-315.
- Programa Nacional de Controle de Qualidade - CNPQ. (2019) Valores críticos de exames laboratoriais que necessitam de imediata tomada de decisão, em atendimento a RDC 302:2005 da ANVISA. http://pncq.org.br/uploads/2019/Valores%20cr%a1ticos%20no%20laborat%a2rio%20cl%a1nico_nov2019.pdf.

Reis, S., Ramos, D., Cordinhã, C., & Gomes, C. (2019). Desafios Diagnósticos e Terapêuticos na Síndrome Hemolítica Urémica Atípica: A Propósito de Um Caso Clínico. *Acta Médica Portuguesa*, 32(10), 673-675.

Schapkaitz, E., & Schickerling, T. M. (2018). The diagnostic challenge of acquired thrombotic thrombocytopenic Purpura in children: case report and review of the literature. *Laboratory Medicine*, 49(3), 268-271.

Tonaco, L. C., Rios, D. R., Vieira, L. M., Carvalho, M. D. G., & Dusse, L. (2010). Púrpura trombocitopênica trombótica: o papel do fator von Willebrand e da ADAMTS13. *Revista Brasileira de Hematologia e Hemoterapia*, 32, 155-161.

Vaisbich, M. H. (2014). Síndrome hemolítico-Urêmica na infância. *Brazilian Journal of Nephrology*, 36, 208-220.

Vaisbich, M. H., Henriques, L. D. S., Watanabe, A., Pereira, L. M., Metran, C. C., Malheiros, D. A., ... & Schvartsman, B. G. S. (2013). Uso do eculizumab na síndrome hemolítica urêmica atípica: relato de caso e revisão da literatura. *Brazilian Journal of Nephrology*, 35, 237-241.

Van Balen, T., Schreuder, M. F., de Jong, H., & van de Kar, N. C. (2014). Refractory thrombotic thrombocytopenic purpura in a 16-year-old girl: successful treatment with bortezomib. *European Journal of Haematology*, 92(1), 80-82.

Wang, X., Zhang, S., Li, L., Hua, J., Zhu, L., Li, L., & Zhang, G. (2018). Ticagrelor-induced thrombotic thrombocytopenic purpura: a case report and review of the literature. *Medicine*, 97(26), e11206.

Yates, S., Matevosyan, K., Rutherford, C., Shen, Y. M., & Sarode, R. (2014). Bortezomib for chronic relapsing thrombotic thrombocytopenic purpura: a case report. *Transfusion*, 54(8), 2064-2067.