

**Investigação da relação entre o diâmetro do óstio sinusal e as alterações no seio maxilar:  
um estudo de tomografia computadorizada de feixe cônico**

**Investigation of the relationship between the sinusal ostium diameter and changes in the  
maxillary sinus: a cone beam computerized tomography study**

**Investigación de la relación entre el diámetro del ostium sinusal y los cambios en el seno  
maxilar: un estudio de tomografía computarizada con haz cónico**

Recebido: 29/05/2020 | Revisado: 03/06/2020 | Aceito: 05/06/2020 | Publicado: 16/06/2020

**George Borja de Freitas**

ORCID: <https://orcid.org/0000-0002-5652-6154>

Centro Universitário de Patos, Brasil

E-mail: [george\\_borja@hotmail.com](mailto:george_borja@hotmail.com)

**Marcus Vinicius Siqueira**

ORCID: <https://orcid.org/0000-0003-1011-686X>

São Leopoldo Mandic, Brasil

E-mail: [marcusvsiqueira@gmail.com](mailto:marcusvsiqueira@gmail.com)

**Arthur José Barbosa de França**

ORCID: <https://orcid.org/0000-0002-4648-0842>

Universidade de Pernambuco, Brasil

E-mail: [arthur.jb.franca@gmail.com](mailto:arthur.jb.franca@gmail.com)

**Paula Bernardon**

ORCID: <https://orcid.org/0000-0003-4661-9733>

São Leopoldo Mandic, Brasil

E-mail: [paula.bernardon@yahoo.com.br](mailto:paula.bernardon@yahoo.com.br)

**Debora Duarte Moreira**

ORCID: <https://orcid.org/0000-0002-2024-9976>

São Leopoldo Mandic, Brasil

E-mail: [dededm@hotmail.com](mailto:dededm@hotmail.com)

**Paulo George Esteves Areal Neto**

ORCID: <https://orcid.org/0000-0001-9464-2749>

Faculdade IPPEO, Brasil

E-mail: [peaodontologia@gmail.com](mailto:peaodontologia@gmail.com)

**Sérgio Lucio Pereira de Castro Lopes**

ORCID: <https://orcid.org/0000-0002-0882-5862>

Universidade Estadual Paulista, Brasil

E-mail: [sergioluciolopes@gmail.com](mailto:sergioluciolopes@gmail.com)

**Francine Kühl Panzarella**

ORCID: <https://orcid.org/0000-0002-5650-7711>

São Leopoldo Mandic, Brasil

E-mail: [francine.panzarella@gmail.com](mailto:francine.panzarella@gmail.com)

**Marco André Lomba Alves**

ORCID: <https://orcid.org/0000-0001-7024-915X>

Faculdade IPPEO, Brasil

E-mail: [marcolomba@globo.com](mailto:marcolomba@globo.com)

**Julierme Ferreira Rocha**

ORCID: <https://orcid.org/0000-0001-9025-5661>

Centro Universitário de Patos, Brasil

E-mail: [juliermerocha@hotmail.com](mailto:juliermerocha@hotmail.com)

**Aldir Nascimento Machado**

ORCID: <https://orcid.org/0000-0002-3609-7604>

Universidade Federal Fluminense, Brasil

E-mail: [aldirmachado@gmail.com](mailto:aldirmachado@gmail.com)

**Luiz Roberto Coutinho Manhães Júnior**

ORCID: <https://orcid.org/0000-0003-1642-5241>

Universidade Estadual Paulista, Brasil

E-mail: [lrnradio@yahoo.com.br](mailto:lrnradio@yahoo.com.br)

## Resumo

**Objetivo:** O objetivo deste estudo foi relacionar o diâmetro do óstio sinusal com quatro alterações conhecidas dos seios maxilares por meio da tomografia computadorizada de feixe cônico (TCFC), considerando lado e sexo. **Metodologia:** 415 exames de TCFC foram avaliados e um total de 328 exames de TCFC de pacientes com mais de 21 anos de idade foram selecionados para o estudo. Por meio de reconstruções coronais corrigidas no posicionamento, foi realizada uma varredura anteroposterior da região do seio maxilar para identificar, localizar e medir o diâmetro do óstio sinusal nos lados direito e esquerdo. Foram consideradas alterações nos seios maxilares: espessamento da membrana sinusal, pseudocisto antral, velamento parcial do seio maxilar e velamento total dos seios maxilares. **Resultados:**

Houve influência do sexo na presença de alterações sinusais, pois, na amostra, a chance (odds ratio) dos homens de apresentarem qualquer alteração sinusal foi 2,44 vezes ( $p = 0,0002$ ) maior do que nas mulheres. Em geral, independentemente do sexo, não houve diferenças estatisticamente significantes entre os diâmetros dos óstios esquerdo ( $3,27 \pm 1,2$  mm) e direito ( $3,12 \pm 1,12$  mm). Também não houve relação entre idade e diâmetro dos óstios e entre idade e tipos de alterações nos seios. **Conclusão:** De acordo com os resultados obtidos, pode-se concluir que não há relação entre o diâmetro do óstio sinusal do seio maxilar e as alterações mais frequentes do seio.

**Palavras-chave:** Seio maxilar; Anormalidades maxilofaciais; Tomografia.

### Abstract

**Objective:** The objective of this study was to relate the sinus ostium diameter with four known changes in the maxillary sinuses by means of cone beam Computed Tomography (CBCT), considering side and gender. **Methodology:** 415 CBCT scans were evaluated and a total of 328 CBCT scans from patients over 21 years of age were selected for the study. By means of corrected coronal reconstructions in positioning, an anteroposterior scan of the maxillary sinus region was performed to identify, locate, and measure the diameter of the sinus ostium on the right and left sides. Changes in the maxillary sinuses were considered: thickening of the sinus membrane, antral pseudocyst, partial veiling of the maxillary sinus and total veiling of the maxillary sinuses. **Results:** There was an influence of sex in the presence of sinus alterations, because in the sample, the odds (odds ratio) of men to have any sinus alteration was 2.44 times ( $p = 0.0002$ ) greater than in women. In general, regardless of gender, there were no statistically significant differences between the diameters of the left ( $3.27 \pm 1.2$  mm) and right ( $3.12 \pm 1.12$  mm) ostia. There was also no relationship between age and diameter of ostia, and between age and types of changes sinuses. **Conclusion:** According to the results obtained, it can be concluded that there is no relationship between the diameter of the sinus ostium of the maxillary sinus and the most frequent sinus changes.

**Keywords:** Maxillary Sinus; Maxillofacial abnormalities; Tomography.

### Resumen

**Objetivo:** El objetivo de este estudio fue relacionar el diámetro del ostium sinusal con cuatro cambios conocidos en los senos maxilares mediante tomografía computarizada de haz cónico (CBCT), considerando el lado y el género. **Metodología:** Se evaluaron 415 exploraciones CBCT y se seleccionaron para el estudio un total de 328 exploraciones CBCT de pacientes mayores de 21 años. Mediante reconstrucciones coronales corregidas en el posicionamiento,

se realizó una exploración anteroposterior de la región del seno maxilar para identificar, localizar y medir el diámetro del orificio del seno en los lados derecho e izquierdo. Se consideraron cambios en los senos maxilares: engrosamiento de la membrana sinusal, pseudoquiste antral, velo parcial del seno maxilar y velo total de los senos maxilares.

**Resultados:** Hubo una influencia del sexo en presencia de alteraciones sinusales, porque en la muestra, las probabilidades (odds ratio) de los hombres de tener alguna alteración sinusal fue 2.44 veces ( $p = 0.0002$ ) mayor que en las mujeres. En general, independientemente del género, no hubo diferencias estadísticamente significativas entre los diámetros de ostia izquierdo ( $3.27 \pm 1.2$  mm) y derecho ( $3.12 \pm 1.12$  mm). Tampoco hubo relación entre la edad y el diámetro de ostia, y entre la edad y los tipos de cambios en los senos paranasales.

**Conclusión:** de acuerdo con los resultados obtenidos, se puede concluir que no existe una relación entre el diámetro del orificio sinusal del seno maxilar y los cambios sinusales más frecuentes.

**Palabras clave:** Seno maxilar; Anomalías maxilofaciales; Tomografía.

## 1. Introdução

The maxillary sinus is the largest paranasal sinus of the skull. It is located bilaterally in the maxillary bone and inferiorly to the orbit. Its shape is pyramidal, with the base along the alveolar process of the maxilla and the apex pointing laterally towards the zygomatic bone, with the roof of the maxillary sinus being the eye orbit floor (Ogle, 2012). The nasal cavity and the maxillary sinus communicate through a small bone canal, called the sinus ostium (Phillips, 2009). This is approximately 4 mm in diameter, located in the upper portion of the medial wall of the sinus cavity (Kretzschmar, 2003), but it can be as wide as 10 mm (Phillips, 2009).

Maxillary ostia with smaller diameters are closely related to decreased drainage of the maxillary sinus (Timmenga, et al., 1997). They are lined by mucosa and during inflammatory processes and disease they may be narrow or completely obliterated (Kretzschmar, 2003).

With the implantology advancement, new surgical techniques have emerged to enable the installation of osseointegrated implants and subsequent prosthetic rehabilitation (Van Zyl, 2009) and currently cone beam computed tomography (CBCT) are the ideal exam for assessing height, thickness and inclination of the remaining alveolar bone, as well as checking the anatomy and pathologies of the maxillary sinuses. Sinus changes can be seen in three-

dimensional examinations. Among them, the thickening of the sinus membrane, partial or total veiling of the maxillary sinuses and antral pseudocyst stand out (Almaghrabi, 2011). Pathological findings in maxillary sinuses can be observed in a prevalence of 56% in CBCT (Ritter, et al., 2011).

Therefore, the objective of this study was to evaluate, by means of cone beam computed tomography, the relationship between the diameter of the sinus ostium and the changes that affect the maxillary sinus, since it is believed to have a direct relationship between both.

## **2. Material and Methods**

A retrospective (observacional) cross-sectional study was carried out using a convenience sample during the period from 09/04/2017 to 09/30/2017, where data were collected from patients who underwent CBCT with indication for rehabilitation in the maxilla. 415 CBCT exams were evaluated, with 328 selected according to the inclusion and exclusion criteria, making a total of 656 maxillary sinuses, with quali-quantitative nature of the results. All authors participated actively supporting the study.

All exams were evaluated in patients with total/partial dentition and upper edentates of both genders, aged 21 years and over, who underwent a tomographic examination to evaluate the maxilla, in which the total volume acquired were present in the anatomical structures of the ostium, with the maxillary sinuses completely. Patients outside the determined age range were excluded, with CBCT scans that did not have in their field of view (FOV) the respective structures to be measured (ostium and maxillary sinuses completely); with a history of trauma, pathological injuries and a history of surgery in the region of the ostium or maxillary sinuses and that the ostium was obliterated or accessory. As a standardized form of sample classification, genders (male and female) and sides (right and left) were considered.

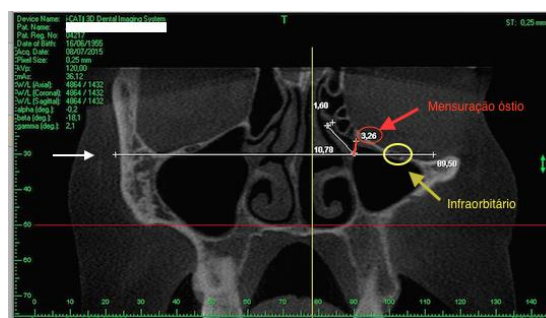For the analysis of the location and measurement of the maxillary ostia, the images were processed and worked in the XoranCat® software (Xoran Technologies, USA). In the multiplanar reconstruction screen, called MPR, the axial, coronal and sagittal anatomical planes were aligned. The arrows guiding the correction of the anatomical planes were used so that the positioning of the patient's head is placed in the work protocol considered correct. In this way, for the axial images, the alignment of the slides of the pterygoid processes of the

sphenoid bone aligned with the plane referring to the coronal cut was used, leaving the anterior nasal spine aligned with the sagittal plane. For sagittal images, the maxillary plane was used as a reference in such a way that the plane between the anterior nasal spine and the posterior nasal spine is parallel to the horizontal or axial plane. Finally, in the coronal sections, the hard palate and the floor of the nasal cavity were aligned with the horizontal or axial plane. For assessments and measurements were analyzed in the coronal plane images.

With coronal sections corrected in positioning, the anteroposterior scan of the maxillary sinus region was performed to identify and locate the drainage ostium. For the location of the ostium and the diameter measurements to be carried out in a standardized manner, coronal sections with 1.00 mm thickness were used, where a line was drawn horizontally in relation to the axial plane, from the center of the foramen infraorbital to the lower wall of the ostium and subsequently a horizontal line to the upper wall, the latter being the measurement of diameter measurement.

The measurement tool of the XoranCat software was used to measure the diameter of the ostium, so that all values are obtained in millimeters. In all cases, measurements were made bilaterally as shown (Figure 1).

**Figure 1** - Software XoranCat® work screen. Coronal section showing the adequacy of the image and measurement of the ostium.



Source: Authors.

Observe the most important structures in the image: maxillary ostium (red line); maxillary sinus (black cavity) and infraorbital nerve (yellow circle). All measurements were made by the same researcher and after obtaining the values of the ostium diameters, these data were tabulated.

For the classification of sinus changes, the following situations were considered:

Thickening of the Sinus Membrane (TSM) - when the distance between the floor of the maxillary sinus and the most extreme portion of the mucosa was equal to or greater than 5.0mm; Pseudo antral cyst (PAC) - A phenomenon of mucus retention was classified when observing a hyperdense, homogeneous image, in the form of a dome that rises from the floor of the maxillary sinus, without corticalization with the characteristic of a soft tissue capsule; Partial veiling (PV) - when a hyperdense, homogeneous, irregular, defined, delimited image was observed from the floor and partially filling the maxillary sinus; Total Veiling (TV) - when there was a hyperdense, homogeneous image, totally obliterating the maxillary sinus and filling the cavity in all tomographic sections.

### 3. Results and Discussion

328 patients were observed, the majority (Chi-square,  $p < 0.0001$ ) were female (65.9%,  $n = 216$ ). However, there were no statistically significant differences (t test,  $p = 0.5071$ ) between the ages of men ( $51.0 \pm 12.6$  years) and women ( $50.1 \pm 11.5$  years). Table 1 shows the relationship between sex and the presence of sinus changes.

**Table 1** - Relative proportion between sex and the presence of sinus changes.

Sinus Changes	Female (n=216)	Male (n=112)	Total (n=328)	p
Without Change	136 (63%)	46 (41,1%)	182 (55,5%)	
Unilateral	65 (30,1%)	57 (50,9%)	122 (37,2%)	0,0005
Bilateral	15 (6,9%)	9 (8%)	24 (7,3%)	

Source: Authors

Table 1 reveals that there were proportionally more men with unilateral sinus changes than women. In fact, the odds (odds ratio) for men to have a sinus disorder was 2.44 times ( $p = 0.0002$ ) greater than that of women in the studied sample. Thus, there was an influence of sex in the presence of sinus alterations.

As most cases were unilateral, Table 2 shows the frequency of sinus changes on the patients' left or right sides.

**Table 2** - Relative proportion between sex and the presence of sinus changes due to the affected side.

Side	Type of sinus alteration	Female (n=216)	Male (n=112)	Total (n=328)
Left	No change	164 (75,9%)	71 (63,4%)	235 (71,6%)
	Thickening of sinus membrane	36 (16,7%)	28 (25%)	64 (19,5%)
	Antral pseudocyst	4 (1,9%)	6 (5,4%)	10 (3,0%)
	Partial screening	12 (5,6%)	7 (6,3%)	19 (5,8%)
Right	No change	163 (75,5%)	70 (62,5%)	233 (71%)
	Thickening of sinus membrane	33 (15,3%)	26 (23,2%)	59 (18%)
	Antral pseudocyst	10 (4,6%)	10 (8,9%)	20 (6,1%)
	Partial Screening	8 (3,7%)	5 (4,5%)	13 (4%)
	Full concealment	2 (0,9%)	1 (0,9%)	3 (0,9%)

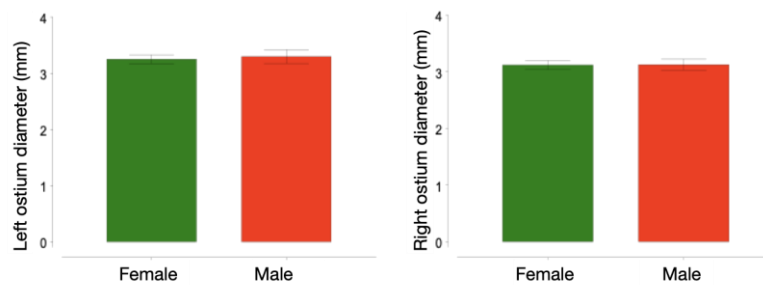
Source: Authors

This table reveals that there were no statistically significant differences (Chi-square) in the frequency of changes between the left and right sides, both for men ( $p = 1.0$ ) and for women ( $p = 1.0$ ). However, both for the right side ( $p = 0.0200$ ) and for the left side ( $p = 0.0239$ ) there were a higher proportion of sinus changes in men than in women, again indicating the influence of sex.

The measurements of the diameters of the right and left ostia in both sexes are shown in Graph 1.



**Graph 1** - Mean ( $\pm$  standard error) of the diameters of the left and right ostia according to sex.

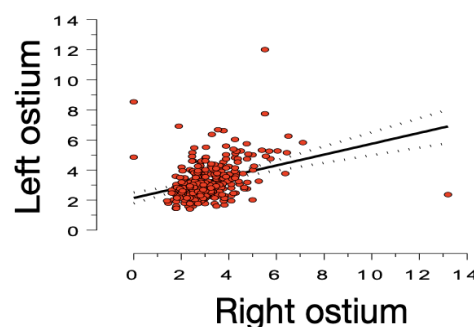


Source: Authors.

It was observed that there were no statistically significant differences (t test) between the sexes for the diameters of the ostia, both for the left side ( $p = 0,7383$ ) and to the right ( $p = 0.9562$ ). Thus, there was no influence of sex on the diameter of the ostia.

In general, regardless of sex, there were also no statistically significant differences (t test,  $p = 0.0510$ ) between the diameters of the left ( $3.27 \pm 1.2$  mm) and right ( $3.12 \pm 1.12$  mm) ostia. However, the correlation (Pearson's correlation test -  $rP$ ) between the diameters of the right and left ostia was weak ( $rP = 0.34$ ,  $p = <0.0001$ ), indicating that there is no clear relationship of symmetry between the two sides, as shown in Graph 2.

**Graph 2** - Correlation between the diameters of the right and left ostia



Source: Authors.

The correlation between the age of the patients and the measurement of the ostia was also weak or non-existent both for the right ( $rP = 0.03$ ,  $p = 0.6279$ ) and for the left ( $rP = 0.15$ ,  $p = 0,0069$ ) side. Thus, there is no relationship between age and diameter of ostia. Table 3 shows the age of the patients due to the sinus changes and affected sides.

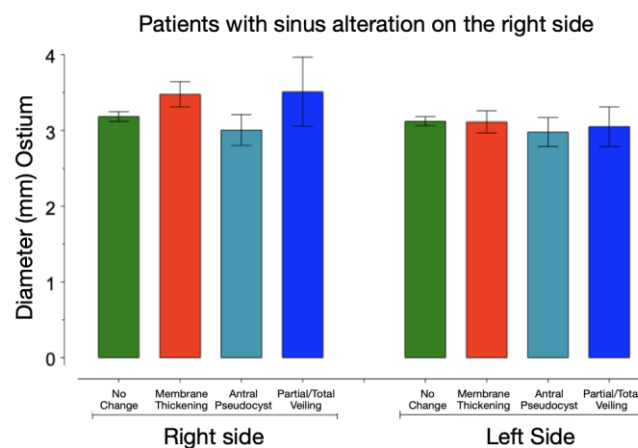
**Table 3** - Mean ( $\pm$  standard error) of age according to the type of sinus alteration and the side affected.

	Sinus Change			
	No Changes	Antral pseudocyst	Thickening of sinus membrane	Partial Screening
Left side	51,0 ( $\pm$ 0,8)	41,9 ( $\pm$ 3,7)	50,2 ( $\pm$ 1,5)	48,2 ( $\pm$ 2,5)
Right side	50,6 ( $\pm$ 0,8)	47,1 ( $\pm$ 2,5)	50,3 ( $\pm$ 1,6)	50,4 ( $\pm$ 3,4)

Source: Authors

There was no relationship (ANOVA,  $p = 0.2890$ ) between age and types of sinus abnormalities, regardless of the side affected. Graph 3 shows the influence of the type of sinus alteration on the diameters of the ostia on both sides, of those patients who exhibited sinus alteration on the right side.

**Graph 3** - Mean ( $\pm$  standard error) of the diameters of the left (unaffected side) and right (affected side) diameters in those patients who presented sinus alteration on the right side.

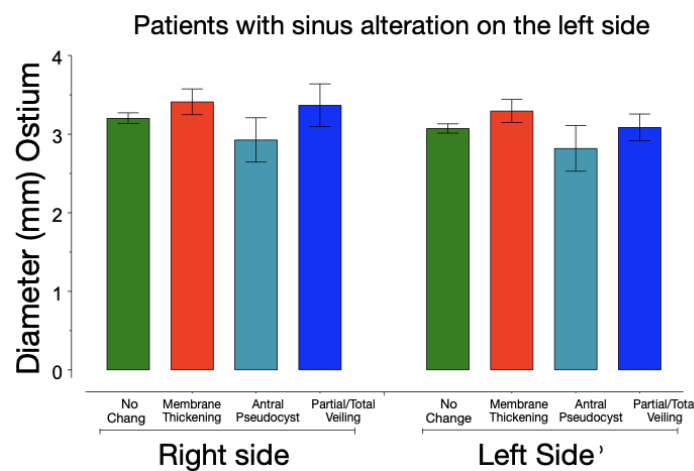


Source: Authors.

There were no statistically significant differences (ANOVA,  $p = 0.2430$ ) between the diameters of the left and right ostia, considering the same type of change, nor between sinus changes considering each side individually.

Graph 4 shows the diameters of the ostia on both sides in relation to the type of sinus alteration in patients who exhibited sinus alteration on the left side.

**Graph 4** - Mean ( $\pm$  standard error) of the diameters of the left (affected side) and right (unaffected side) diameters in those patients who presented sinus alteration on the left side.



Source: Authors.

Likewise, there were no statistically significant differences (ANOVA,  $p = 0.2383$ ) between the left and right sides for each type of change or between sinus changes. Thus, the diameter of the ostia did not influence sinus changes.

In the present study, the diameter of the sinus ostia on both sides of the jaws was measured and correlated with 4 sinus changes: thickening of the sinus membrane, antral pseudocyst, partial veiling and total veiling of the maxillary sinus. Of the total maxillary sinuses that entered the study ( $n = 328$ ), 63% of female patients did not present changes in the maxillary sinus, while 41% of male patients did not present changes. Therefore, in the present study, the odds (odds ratio) of the male gender to have any sinus alteration was 2.44 times ( $p = 0.0002$ ) greater than that of the female gender in the studied sample.

Comparing the thickening of the sinus membrane in relation to the sides of the jaws (right and left), there was a prevalence of 19.5% for thickening of the left sinus membrane (both sexes) and 18% for thickening of the sinus membrane of the right maxillary sinus. Numbers lower than other studies, which obtained thickening variations between 35.1% and 66% (Smith, 2010; Brüllmann, 2012; Rege, 2012; Block, 2014; Raghav, 2014; Nunes, et al., 2016). However, Rege et al. (2012) used CBTC only for patients who would be submitted to the installation of osseointegrated implants, and Lana et al. (2012) considered thickening of the sinus membrane with measurements equal to or greater than 3mm. In our study, sinus

membrane thickening was measured with measurements starting at 5 mm, according to the classification by Carmeli et al. (2011).

In 3.0% of the left maxillary sinuses and 6.1% of the right maxillary sinuses presented pseudocysts. Other studies cite the prevalence of mucous cysts ranging from 3.5% to 16.4% (Nunes, et al., 2016; Cha, 2007; Gracco, et al., 2012; Phothikhun, 2012). Rege et al. (2012) and Lana et al. (2012) found this pathology in around 10.1%, and 21.4% of cases, respectively.

For partial veiling of the maxillary sinuses, the prevalence was 5.8% (left maxillary sinuses) and 4.0% (right maxillary sinuses), data close to that found by Rege et al. (2012), which was 7.8%. In only 3 patients, representing 0.9% of the sample, the phenomenon of total veiling of the maxillary sinus was observed. This can be explained by the fact that these patients have more specific signs and symptoms of rhinosinusitis and seek assistance from otorhinolaryngologists, thus not being in the sample profile that was used in this research. The partial or total veiling showed a prevalence of 1.8% to 68.2%, according to some authors (Ritter, et al., 2011; Raghav, 2014; Nunes, et al., 2016; Lana, et al., 2012; Gracco, et al., 2012). In 1 study, involving 1026 maxillary sinuses, 68.2% presented veiling of less than a third of the breast (Gracco, et al., 2012).

According to Aust et al. (1974), in a clinical study of 37 normal people, it was observed that the average functional size of the sinus ostium corresponded to a diameter of 2.4 mm, data very close to this study. Anon et al. (1996) also corroborates the data of this study, informing that the functional opening of the sinus ostium is 2.4 mm in diameter on average.

In the present study, there were no statistically significant differences (ANOVA,  $p = 0.2430$ ) between the diameter of the left and right Ostia, considering the same type of alteration, nor between sinus alterations considering each side individually. Likewise, there were no statistically significant differences (ANOVA,  $p = 0.2383$ ) between the right and left sides for each type of change, nor between sinus changes.

With the evolution of imaging tests, more specifically CT scans, obtaining these tests as supporting instruments in the surgical planning of osseointegrated implants in the jaw as well as bone grafting procedures, knowledge of the most frequent changes in the maxillary sinuses has become essential for adequate planning to reduce risk factors. The relationship

between the diameter of the drainage ostium and the appearance of these changes could be related. Thus, according to this research, the diameter of the ostia did not influence sinus changes.

#### 4. Conclusion

According to the results obtained in the present study, the diameters of the sinus ostia do not seem to influence the appearance of changes in the maxillary sinuses, regardless of which side and gender.

Further studies varying the profile and sample size are necessary to validate the results found in this research.

#### References

Almaghrabi BA et al (2011). Treatment of severe sinus infection after sinus lift procedure: a case report. *Implant Dent*, 20(6), 430- 3.

Anon M&Rontal J (1996). *Prophylactic antibiotics in paranasal sinus surgery in infectious diseases and antimicrobial therapy of the ears, nose and throat*. Philadelphia/USA: Saunders.

Aust R&Drettner B (1974). The functional size of the human maxillary ostium in vivo. *Acta Otolaryngol*, 78, 432-435.

Block MS&Dastoury K (2014). Prevalence of sinus membrane thickening and association with unhealthy teeth: a retrospective review of 831 consecutive patients with 1,662 cone-beam scans. *J Oral Maxillofac Surg*, 72 (24), 54-60.

Brüllmann DD et al (2012). Correlation of cone beam computed tomography (CBCT) findings in the maxillary sinus with dental diagnoses: a retrospective cross-sectional study. *Clin Oral Investig*, 16, 1023-9.

Carmeli G et al (2011). Antral computerized tomography pre-operative evaluation: relationship between mucosal thickening and maxillary sinus function. *Clin Oral Implants Res*, 22 (1), 78-82.

Cha JY; Mah J&Sinclair P (2007). Incidental findings in the maxillofacial area with 3-dimensional cone-beam imaging. *Am J Orthod Dentofacial Orthop*, 132, 7-14.

Gracco A et al (2012). Prevalence of incidental maxillary sinus findings in Italian orthodontic patients: a retrospective cone-beam computed tomography study. *Korean J Orthod*, 42, 329-34.

Kretzschmar DP&Kretzschmar JL (2003). Rhinosinusitis: review from a dental perspective. *Oral Surg Oral Med Oral Pathol Oral Radiol Endod*, 96 (2), 128-35.

Lana JP et al (2012). Anatomic variations and lesions of the maxillary sinus detected in cone beam computed tomography for dental implants. *Clin Oral Implants Res*, 23 (12), 1398-403.

Nunes CA et al (2016). Evaluation of Periapical Lesions and Their Association with Maxillary Sinus Abnormalities on Cone-beam Computed Tomographic Images. *J Endod.*, 42, 42-6.

Ogle OE; Weinstock RJ&Friedman E (2012). Surgical anatomy of the nasal cavity and paranasal sinuses. *Oral and Maxillofacial Surgery Clinics of North America*, 24 (2), 155–166.

Pereira AS et al (2018). *Methodology of scientific research*. [e-Book]. Santa Maria City. UAB/NTE/UFSM Editors. Accessed on: June, 3rd, 2020. Available at: [https://repositorio.ufsm.br/bitstream/handle/1/15824/Lic\\_Computacao\\_Metodologia-Pesquisa-Cientifica.pdf?sequence=1](https://repositorio.ufsm.br/bitstream/handle/1/15824/Lic_Computacao_Metodologia-Pesquisa-Cientifica.pdf?sequence=1).

Phillips JE et al (2009). Threedimensional analysis of rodent paranasal sinus cavities from X-ray computed tomography (CT) scans. *Can J Vet Res.*, 73 (3), 205-11.

Phothikhun S et al (2012). Cone-beam computed tomographic evidence of the association between periodontal bone loss and mucosal thickening of the maxillary sinus. *J Periodontol.*, 83, 557-64.

Raghav M et al (2014). Prevalence of incidental maxillary sinus pathologies in dental patients on cone-beam computed tomographic images. *Contemp Clin Dent.*, 5, 361-5.

Rege IC et al (2012). Occurrence of maxillary sinus abnormalities detected by cone beam CT in asymptomatic patients. *BMC Oral Health.*, 10 (12) 30.

Ritter L et al (2011). Prevalence of pathologic findings in the maxillary sinus in cone-beam computerized tomography. *Oral Surg Oral Med Oral Pathol Oral Radiol Endod.*, 111, 634-40.

Smith KD et al (2010). The prevalence of concha bullosa and nasal septal deviation and their relationship to maxillary sinusitis by volumetric tomography. *Int J Dent.*, pii: 404982.

Timmenga NM et al (1997). Maxillary sinus function after sinus lifts for the insertion of dental implants. *J Oral Maxillofac Surg.*, 55 (9), 936-9.

Van Zyl AW&Van Heerden WFP (2009). A retrospective analysis of maxillary sinus septa on reformatted computerised tomography scans. *Clin. Oral Impl. Res.* 1398–1401.

#### **Porcentagem de contribuição de cada autor no manuscrito**

George Borja de Freitas 1 – 15%

Marcus Vinicius Siqueira 2 – 15%

Arthur José Barbosa de França 3 – 15%

Paula Bernardon 4 – 6,1%

Debora Duarte Moreira 5 – 6,1%

Paulo George Esteves Areal Neto 6 – 6,1%

Sérgio Lucio Pereira de Castro Lopes 7 – 6,1%

Francine Kühl Panzarella 8 – 6,1%

Marco André Lomba Alves 9 – 6,1%

Julierme Ferreira Rocha 10 – 6,1%

Aldir Nascimento Machado 11 – 6,1%

Luiz Roberto Coutinho Manhães Júnior 12 – 6,1%