

**Accidental ingestion of an orthodontic retainer: which steps should be taken?**

**Ingestão acidental de contenção ortodôntica: o que fazer?**

**Ingestión accidental de retenedor de ortodoncia: ¿que hacer?**

Received: 08/26/2020 | Reviewed: 09/03/2020 | Accept: 09/12/2020 | Published: 09/14/2020

**Letícia Fernanda Serafim Cabral**

ORCID: <https://orcid.org/0000-0001-7590-0917>

Universidade de Pernambuco, Brasil

E-mail: [leticiafscabral@hotmail.com](mailto:leticiafscabral@hotmail.com)

**Raíssa Soares dos Anjos**

ORCID: <https://orcid.org/0000-0002-4766-4272>

Universidade de Pernambuco, Brasil

E-mail: [raissa\\_soares@hotmail.com](mailto:raissa_soares@hotmail.com)

**Ricardo Godoy**

ORCID: <https://orcid.org/0000-0003-0121-6949>

Faculdade de Odontologia do Recife, Brasil

E-mail: [ricardobanks@gmail.com](mailto:ricardobanks@gmail.com)

**José Laureano Filho**

ORCID: <https://orcid.org/0000-0002-9645-2057>

Universidade de Pernambuco, Brasil

E-mail: [laureano@fop.upe.br](mailto:laureano@fop.upe.br)

**Fabiana Godoy**

ORCID: <https://orcid.org/0000-0002-1946-9605>

Universidade de Pernambuco, Brasil

E-mail: [fabiana.godoy@upe.br](mailto:fabiana.godoy@upe.br)

**Abstract**

Dental materials are relatively rare to be swallowed, especially when it comes to orthodontic objects. However, this type of emergency can arise in the dental clinic environment. Although the ideal is to avoid its occurrence, it is necessary that the professional knows how to handle the situation, in cases that happen. Therefore, the aim of this article was to perform a literature review and describe a clinical case of ingestion of an orthodontic retainer. In this way, exemplify complications arising from accidental swallowing and propose possibilities of

conduct. In order to obtain these answers, a literature review was carried out associated with a case study on the subject in question. As a result, it was found that the swallowing or aspiration of appliances or components associated with fixed or removable orthodontic appliances are the categories most cited in the literature. Regardless of the incidence, episodes such as ingestion or aspiration of a foreign body are recognized as possible complications in orthodontics. When accidents occur outside the dental office, patients are generally undergoing orthodontic treatment, which represents less than 10% of all cases of accidental swallowing. It is concluded that the investigation after the ingestion of any component of an orthodontic appliance is essential to ensure patient safety and to make any necessary medical referral for emergency care in order to avoid possible complications.

**Keywords:** Accident; Orthodontics; Swallowing; Foreign body; Orthodontic device.

### **Resumo**

Os materiais odontológicos são relativamente raros de serem engolidos, ainda mais quando se trata de objetos ortodônticos. Entretanto, esse tipo de emergência pode surgir no ambiente da clínica odontológica. Embora o ideal seja evitar sua ocorrência, é necessário que o profissional saiba conduzir a situação, em casos que venha a acontecer. Portanto, o objetivo deste artigo foi realizar uma revisão da literatura e descrever um caso clínico de ingestão de contenção ortodôntica. Desta forma, exemplificar complicações oriundas da deglutição acidental e propor possibilidades de conduta. A fim de obter essas respostas, realizou-se de uma revisão da literatura associada a um estudo de caso sobre o tema em questão. Como resultados, obteve-se que a deglutição ou aspiração de aparelhos ou de componentes associados ao aparelho ortodôntico fixo ou removível são as categorias mais citadas na literatura. Independentemente da incidência, episódios como ingestão ou aspiração de corpo estranho são reconhecidos como possíveis complicações em Ortodontia. Quando os acidentes ocorrem fora do consultório odontológico, os pacientes geralmente estão em tratamento ortodôntico, o que representa menos de 10% do total de casos de deglutição acidental. Conclui-se que a investigação após a ingestão de qualquer componente de um aparelho ortodôntico é fundamental para levar a segurança do paciente e realizar qualquer encaminhamento médico necessário para atendimento de emergência a fim de evitar possíveis complicações.

**Palavras-chave:** Acidente; Ortodontia; Deglutição; Corpo estranho; Aparelho ortodôntico.

## Resumen

Los materiales dentales son relativamente raros de tragar, especialmente cuando se trata de objetos de ortodoncia. Sin embargo, este tipo de emergencias pueden surgir en el ámbito de la clínica dental. Si bien lo ideal es evitar que se produzca, es necesario que el profesional sepa manejar la situación, en los casos que suceda. Por tanto, el objetivo de este artículo fue realizar una revisión de la literatura y describir un caso clínico de ingestión de retenedores de ortodoncia. De esta forma, ejemplifica las complicaciones derivadas de la deglución accidental y propone posibilidades de conducta. Para obtener estas respuestas se realizó una revisión de la literatura asociada a un estudio de caso sobre el tema en cuestión. Como resultado, se encontró que la deglución o aspiración de aparatos o componentes asociados con aparatos de ortodoncia fijos o removibles son las categorías más citadas en la literatura. Independientemente de la incidencia, episodios como la ingestión o la aspiración de un cuerpo extraño se reconocen como posibles complicaciones en ortodoncia. Cuando los accidentes ocurren fuera del consultorio dental, los pacientes suelen estar sometidos a un tratamiento de ortodoncia, lo que representa menos del 10% de todos los casos de ingestión accidental. Se concluye que la investigación posterior a la ingestión de cualquier componente de un aparato de ortodoncia es fundamental para garantizar la seguridad del paciente y realizar la derivación médica necesaria para atención de emergencia a fin de evitar posibles complicaciones.

**Palabras clave:** Accidente; Ortodoncia; Deglución; Cuerpos extraños; Aparatos ortodóncicos.

## 1. Introduction

Swallow and/or aspirate components of different kinds are rarely reported in the literature. Some cases present minimal danger and others have the potential to be lethal, depending on the size, shape and flexibility of the object (Umesan et al., 2012). Most foreign bodies travel spontaneously through the oropharynx and reach the gastrointestinal tract, and about 10–20% of cases require only preservation (Parolia et al., 2009), but if they remain lodged for more than two weeks, surgery intervention is required (Obinata et al., 2011).

Only 1% or less of cases may require surgery as a treatment. Usually patients who swallow utensils persist asymptomatic at the time of the act, but there is a possibility that symptoms may develop later (Parolia et al., 2009). Moreover, the literature it emphasizes that dental devices may be swallowed not only after an implantation procedure, as also even during it. If ingestion remains undetected, it may result in chronic complications (Tiller et al.,

2014).

The size, shape, and presence of sharp edges of the ingested object will influence risk factors, administration and outcome. Large or sharp objects are at risk of becoming impacted. If the item has sharp edges and/or is in a critical area, it must be removed. However approximately 60% enter the gastrointestinal tract without lodging in the oesophagus (Puryer et al., 2016). Possible complications due to unnoticed foreign body ingestion include damage to the gastric mucosa, intestinal obstruction, perforation with/without subsequent abscess formation which may be retropharyngeal or intra-abdominal. Other more serious consequences are sepsis, peritonitis, impacted and/or esophageal stenosis, ulcerative esophagitis, gastroesophageal, and enterocolic fistula, recurrent pneumonitis, hemorrhage, and failure on the pathway of the object elimination (Parolia et al., 2009; Obinata et al., 2011; Puryer et al., 2016).

According to age, different objects are prevalently ingested by accident. Foreign bodies most commonly swallowed by children are coins, and adults often swallow fish bones. Dental prostheses are most commonly swallowed by elderly patients, especially patients with dementia. Dental materials are rarely swallowed and cause problems for most of the population (Tihan et al., 2011). When it comes to items of dental origin that cause such accidents, we can find mobility teeth, restorative materials, instruments, implant components, rubber dam clamps, gauze and impression materials (Tiwana et al., 2004; Hill & Rubel, 2008). Regarding orthodontics braces, the swallowing of components associated with fixed braces and/or part of fixed or removable braces are most cited in the literature (Poletto et al., 2013).

Ingestion of dental objects can happen during the query or not. However, it is more common during the procedure being associated with the ingestion of restorations or prostheses. When accidents are out of the office, patients are usually undergoing orthodontic treatment and this represents less than 10% of all accidental swallowing cases (Hisanaga et al., 2010).

This study aims to conduct a brief review of the literature, in order to elucidate the etiology of cases of accidental swallowing of orthodontic objects and the dentist's conduct in relation to these cases, as well as to compare with the conduct performed in this case.

## **2. Methodology**

This is a literature review article associated with a case study. Approval by the Comitê

de Ética em Pesquisa was not necessary, given that it is a literature review and case report. However, the patient authorized the use of images, clinical, radiographic and socioeconomic data for educational and research purposes by signing Termo de Consentimento Livre Esclarecido (TCLE).

In addition to the description of the clinical case, a review of the literature was carried out based on the PRISMA criteria on the subject in question. In this review, the descriptors: Accident, Orthodontics, Swallowing, Foreign Body and Orthodontic Device were used, with the Boolean operator AND being applied at the intersection of searches. The bibliographic survey was carried out in the PubMed database, in which a total of 39 articles were found. Therefore, for this work 23 articles were selected, in which, 17 are clinical case report articles and 6 are literature review articles.

### **3. Case Report**

Patient L. B. C. P., male, leukoderma, 25 years old, without any allergies, blood dyscrasias, cardiovascular, gastrointestinal, hepatic, endocrine and renal diseases. Ten years after concluding the orthodontic treatment he was admitted to the emergency of a referral hospital in the metropolitan region of Recife - Pernambuco - Brazil, due to swallowing his fixed orthodontic retainer from the anterior region of the lower arch. The patient had no signs or symptoms of foreign body ingestion.

On the same day, a chest x-ray was performed which showed normal pulmonary transparency, centered mediastinum, free costophrenic sinuses and normal cardiac area, indicating that their airways were not affected and had no impairment (Figure 1). At the same time, an abdominal radiography showed the presence of a linear image of metallic density in gastric projection, which was identified as a foreign body (Figure 2). Since the patient's airway was not compromised, the object was monitored.

The endoscopy exam was also requested and performed, however, this exam presented an inconclusive report due to the moderate amount of food residues in the gastric body (Figure 3). After three hours, a second radiograph was taken and the object was still in the epigastric region. Therefore, it was decided to repeat the endoscopy exam six hours later. In this second exam, it was noticed the absence of the foreign body throughout the examined pathway (esophagus, stomach and duodenum).

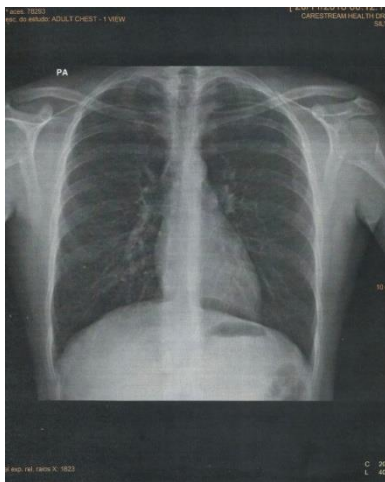
As the object had not been eliminated so far, it was decided to hospitalize the patient and the case could be monitored through other radiographic exams and appropriated clinical

exam. The patient was followed during hospitalization and it was performed abdominal radiographs, which allowed to find the foreign body location. The next day, the projected linear image of metallic density compatible with orthodontic retainer, was in the colonic segments of the right iliac fossa (Figure 4). After three days hospitalized the patient left the hospital and was followed by abdominal radiograph taken every day.

In his last two abdominal radiographs, six days after ingestion, the projecting metal density was on the left flank (Figure 5) and right iliac fossa, respectively, indicating the presence of a foreign body.

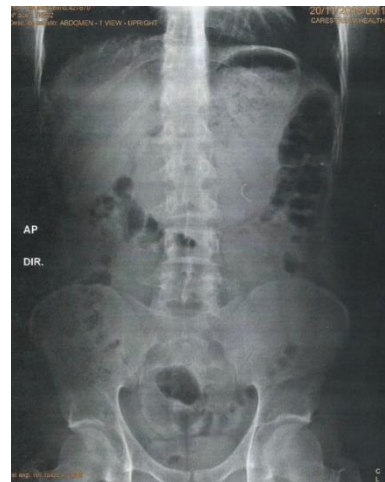
Four days after the last x-ray the patient referred that the retainer was eliminated in the feces without complications, as show on the CT scan (Figure 6).

**Figure 1.** Chest x-ray showing normal pulmonary transparency and normal cardiac area, showing that his airways were unaffected and did not present impairment.



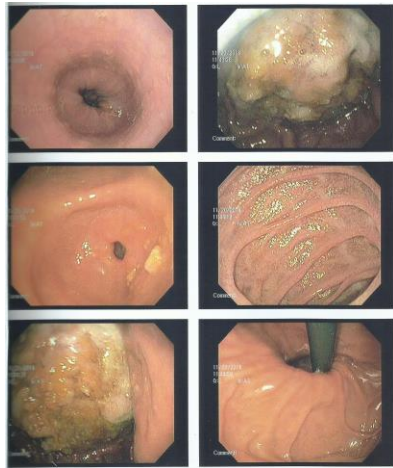
Source: Authors

**Figure 2.** Simple abdominal radiography that suggests the presence of a foreign body - linear image with metallic density located in the gastric projection.



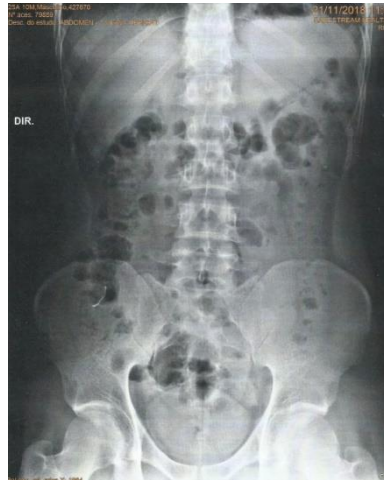Source: Authors

**Figure 3.** Endoscopy exam without any foreign body presence detected in the examined path. The study in the gastric body was not allowed due to the presence of food residues.



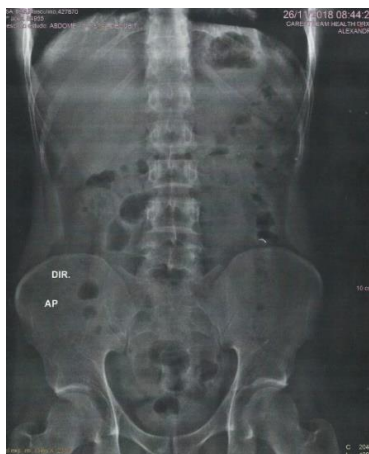Source: Authors

**Figure 4.** Simple abdominal radiography that suggests a linear projection with metallic density similar to orthodontic retainer. It was located in the colonic segments of the right iliac fossa.



Source: Authors

**Figure 5.** Simple abdominal radiography that suggests a projection with density like a metal indicating the presence of a foreign body in the left flank.



Source: Authors

**Figure 6.** Computed tomography showing absence of foreign body suggesting that it was expelled.



Source: Authors

#### 4. Discussion

In the general population, ingestion of foreign bodies is not uncommon (Hou et al., 2016), especially in children (Pantuzo et al., 2017), alcoholics, toothless people, the elderly, stroke, dementia, Parkinson's disease, cerebral palsy, autism and mental retardation. This is justified by cognition and limited communication in these groups. In patients using prostheses, there may be a reduction in palate tactile sensitivity, which leads to a decrease in the ability to perceive small objects in the oral cavity (Nicolodi et al., 2016), it is related to up to 80% of cases of accidental foreign body ingestion while eating (Nicolodi et al., 2016; Goh et al., 2006).

A common accidental ingestion of a dental object is the swallowing of orthodontic appliances. The ingestion of these types of appliances may also present serious consequences to the patient, especially if the patient has a pre-existing systemic condition, such as cardiac problems. Therefore, every preventive effort must be taken to avoid these incident (Pantuzo et al., 2017). The accidents could happen during numerous dental procedures due to some factors and associated with certain incidents, suggesting the importance of patient's safety and instituting prudence at all times. However, most literature only reported one or several cases with limited information on the description of the accidents. There were hardly any review on making knowledge record and discussion of accidental cases (Hou et al., 2016).

Aspiration or accidental ingestion of orthodontic materials may cause problems in the patient's airway or gastrointestinal tract (Umesan et al., 2012). It is noteworthy that even so, there is a risk of intestinal perforation which can have serious consequences, including death. However, most swallowed objects pass through the oropharynx and follow the gastrointestinal tract without complications, as in this case (Ghori et al., 1999).

The patient realized that the orthodontic retainer was missing in his oral cavity, so he believed that he had swallowed it during his meal. A one-year study by Tokyo Dental College found that there was no case of swallowing dental material during dental care of patients who had swallowed any of these items (Hisanaga et al., 2010).

Since the foreign body has reached the stomach, as it was in the patient's epigastric region on abdominal radiography, the literature shows that there is a 90% chance that this object will follow the gastrointestinal tract as a result of uncomplicated peristaltic movement, usually after a period of seven to ten days. As a precaution, it is recommended to eat foods that favor the patient's good bowel function and stimulate peristaltic movement and facilitate the evaluation of objects by serial radiography until they are expelled naturally. For this



reason, while the patient was hospitalized, he used isosmotic laxative medication associated with tropical and fibrous fruits for good bowel function, in order to avoid possible intestinal obstruction. In cases where patients develop perforation symptoms such as abdominal pain, vomiting, tenderness, or protection, and if objects remain housed for more than two weeks, intervention surgery is required (Obinata et al., 2011).

Swallowing objects, especially those with sharp edges, may be impacted and settle on the fourth cervical vertebra, which is an area most commonly reached by foreign bodies (Lau et al., 2009). Therefore, on first admission, the case should be considered in patients of all ages who have swallowed any item and treatment should be properly planned after a brief medical history and physical examination (Tiwana et al., 2004).

The patient's negative radiological findings do not rule out the possibility of a foreign body in the esophagus, especially if there are symptoms, which justifies an endoscopy. In this case, the patient exhibited no signs or symptoms typical of ingestion of a foreign body and yet the endoscopy was chosen as a precaution. In cases like this, where the foreign body has reached the stomach, there is a 80% to 90% chance that the object's passage through the intestine will occur spontaneously without any complications (Webb et al., 1984).

Upper digestive endoscopy is a relatively safe procedure and is indicated when the ingested object is not radiopaque because it is unlikely to appear on radiographs. Another indication is when the object is elongated, thus indicated in this case because it is a foreign body with length of five to seven centimeters, attached to it the object has eccentric shape and are prone to housing and drilling. Urgent endoscopy is mandatory in cases where there is airway obstruction or evidence of other complications (Parolia et al., 2009).

In this case, it was possible to perceive that the joint work of the health professional team is a factor that adds and stands out for having communication among its members, regarding the evolution of patients, regardless of whether the visits are individual or shared. This team integration actually promotes the health and well-being of the people who attend the service (Rossetto et al., 2020).

## **5. Conclusion**

Unnoticed ingestion of foreign bodies, especially orthodontic originated that could be sharpened and in some cases be potentially dangerous and lead to perforations in the gastrointestinal tract. Thus, it is important to track the object using radiographs and endoscopy, which in many cases also allows the removal of this foreign body. In order to

reduce the risk of swallowing orthodontic materials, an option would be the use of removable retainer once it could be removed before meals.

Currently, this is the most widely used approach in orthodontics, as an inadequate angle of premolars is observed with the use of a traditional retainer. Therefore, in addition to being more effective in maintaining orthodontic treatment, it also reduces the risk of accidents as described throughout the text. However, regardless of the type of retainer applied, the patient must be periodically monitored by his orthodontist in order to avoid a risky situation. It should also be emphasized the importance of a good relationship between dentists and other health professionals in order to ensure the appropriate treatment of patients when necessary.

## References

Ghori, A., Dorricott, N., & Sanders, D. (1999). A lethal ectopic denture: an unusual case of sigmoid perforation due to unnoticed swallowed dental plate. *J R Coll Surg Edinb*, 44(3), 203–204. Retrieved from <https://pubmed.ncbi.nlm.nih.gov/10372496/>

Goh, B. K. P., Tan, Y. M., Lin, S. E., Chow, P. K. H., Cheah, F. K., Ooi, L. L. P. J., & Wong, W. K. (2006). CT in the preoperative diagnosis of fish bone perforation of the gastrointestinal tract. *American Journal of Roentgenology*, 187(3), 710–714. doi:10.2214/AJR.05.0178

Hill, E. E., & Rubel, B. (2008). A practical review of prevention and management of ingested/aspirated dental items. *General Dentistry*, 56(7), 691–694. Retrieved from <http://www.ncbi.nlm.nih.gov/pubmed/19014028>

Hisanaga, R., Hagita, K., Nojima, K., Katakura, A., Morinaga, K., Ichinohe, T., Konomi, R., Takahashi, T., Takano, N., & Inoue, T. (2010). Survey of accidental ingestion and aspiration at Tokyo Dental College Chiba Hospital. *The Bulletin of Tokyo Dental College*, 51(2), 95–101. doi:10.2209/tdcpublish.51.95

Hou, R., Zhou, H., Hu, K., Ding, Y., Yang, X., Xu, G., Xue, P., Shan, C., Jia, S., & Ma, Y. (2016). Thorough documentation of the accidental aspiration and ingestion of foreign objects during dental procedure is necessary: Review and analysis of 617 cases. *Head and Face Medicine*, 12(1), 2–8. doi:10.1186/s13005-016-0120-2

- Lau, G., Kulkarni, V., Roberts, G. K., & Brock-Utne, J. (2009). “Where are my teeth?” A case of unnoticed ingestion of a dislodged fixed partial denture. *Anesthesia and Analgesia*, 109(3), 836–838. doi:10.1213/ane.0b013e3181ae06c9
- Nicolodi, G. C., Trippia, C. R., Caboclo, M. F. F. S., de Castro, F. G., Miller, W. P., de Lima, R. R., Tazima, L., & Geraldo, J. (2016). Intestinal perforation by an ingested foreign body. *Radiologia Brasileira*, 49(5), 295–299. doi:10.1590/0100-3984.2015.0127
- Obinata, K., Satoh, T., Towfik, A. M., & Nakamura, M. (2011). An investigation of accidental ingestion during dental procedures. *Journal of Oral Science*, 53(4), 495–500. doi:10.2334/josnugd.53.495
- Pantuzo, M. C. G., Nunes, E., Pires, L. R., da Pinto, L. S. M. C., & Oliveira, D. D. (2017). Ingestion of a RPE activation key: Why do these accidents still happen? *European Archives of Paediatric Dentistry*, 18(2), 119–121. doi:10.1007/s40368-017-0277-9
- Parolia, A., Kamath, M., Kundubala, M., Manuel, T. S., & Mohan, M. (2009). Management of foreign body aspiration or ingestion in dentistry. In *Kathmandu University Medical Journal*, 7(26), 165–171. doi:10.3126/kumj.v7i2.2715
- Poletto, C. A. R., Motohiro, O., Gevaerd, R., Goulart Poletto, A., & Souza Camargo, E. (2013) Prevention and conduct in cases of accidental swallowing and ingestion of components of orthodontic appliances. *Rev Clín Ortod Dental Press*, 12(2), 64-70. Retrieved from <https://pesquisa.bvsalud.org/portal/resource/pt/biblio-855936>
- Puryer, J., McNamara, C., Sandy, J., & Ireland, T. (2016). An Ingested Orthodontic Wire Fragment: A Case Report. *Dentistry Journal*, 4(3), 24. doi:10.3390/dj4030024
- Rossetto, M., Luzardo, A. R., Schmatz, L., Barbato, P. R., Lima, J. F., & Almeida, M. E. de. (2020). Equipe multiprofissional e práticas integrativas e complementares no serviço de saúde do trabalhador. *Research, Society and Development*, 9(9), e418997461. doi:10.33448/rsd-v9i9.7461
- Tihan, D., Trabulus, D., Altunkaya, A., Karaca, S., Cihan, A., & Aliş, H. (2011). Esophageal

perforation due to inadvertent swallowing of a dental prosthesis. *Turkish Journal of Gastroenterology*, 22(5), 529–533. doi:10.4318/tjg.2011.0290

Tiller, M., Schepp, W., Gundling, F., & Tuerck, J. (2014). Chronic pancreatitis caused by a swallowed orthodontic device. In *Endoscopy*, 46(01), E667–E668. doi:10.1055/s-0034-1390866

Tiwana, K. K., Morton, T., & Tiwana, P. S. (2004). Aspiration and ingestion in dental practice: A 10-year institutional review. *Journal of the American Dental Association*, 135(9), 1287–1291. doi:10.14219/jada.archive.2004.0404

Umesan, U. K., Ahmad, W., & Balakrishnan, P. (2012). Laryngeal impaction of an archwire segment after accidental ingestion during orthodontic adjustment. *American Journal of Orthodontics and Dentofacial Orthopedics*, 142(2), 264–268. doi:10.1016/j.ajodo.2011.05.025

Webb, W. A., McDaniel, L., & Jones, L. (1984). Foreign Bodies of the Upper Gastrointestinal Tract: Current Management. *Southern Medical Journal*, 77(9), 1083–1086. doi:10.1097/00007611-198409000-00006

**Percentage of contribution of each author in the manuscript** **Letícia**

Fernanda Serafim Cabral – 22%

Raíssa Soares dos Anjos – 22%

Ricardo Godoy – 18%

José Laureano Filho – 18%

Fabiana Godoy – 20%