

Maxillary sinus implant removal: modified Caldwell-Luc technique
Remoção de implante do seio maxilar: Técnica de Caldwell-Luc modificada
Extracción del implante de seno maxilar: técnica de Caldwell-Luc modificada

Received: 08/28/2020 | Reviewed: 09/05/2020 | Accept: 09/10/2020 | Published: 09/12/2020

Juceléia Maciel

ORCID: <https://orcid.org/0000-0002-6508-0342>

Universidade Estadual Paulista, Brasil

E-mail: juceleia.maciel@gmail.com

Albanir Gabriel Borrasca

ORCID: <https://orcid.org/0000-0002-9672-5625>

Universidade Estadual Paulista, Brasil

E-mail: albanirgabriel@hotmail.com

Leonardo Alan Delanora

ORCID: <https://orcid.org/0000-0002-3002-4420>

Universidade Estadual Paulista, Brasil

E-mail: leonardoaland@gmail.com

Maria Eloise de Sá Simon

ORCID: <https://orcid.org/0000-0002-0908-5149>

Universidade Estadual Paulista, Brasil

E-mail: eloise.simon@unesp.br

Nathália Januário de Araujo

ORCID: <https://orcid.org/0000-0003-1812-7723>

Universidade Estadual Paulista, Brasil

E-mail: nathaliajanuario@outlook.com

Leonardo Perez Faverani

ORCID: <https://orcid.org/0000-0003-2249-3048>

Universidade Estadual Paulista, Brasil

E-mail: leonardo.faverani@unesp.br

Idelmo Rangel Garcia Júnior

ORCID: <https://orcid.org/0000-0001-8892-781X>

Universidade Estadual Paulista, Brasil

E-mail: irgcirurgia@gmail.com

Abstract

The installation of immediate implants after tooth extractions is becoming a common practice in the dental clinic. During this surgical procedure, complications such as the displacement of dental implants into the maxillary sinus may occur due to the close relationship between the floor of the maxillary sinus and the upper teeth. In these cases, treatment consists of removing the implant that has been displaced in order to prevent future complications such as maxillary sinusitis and oroantral fistula. The present study aims to present a clinical case in which the removal of the maxillary sinus implant was performed using the modified Caldwell-Luc Technique. The patient sought a private clinic for extraction of the left upper second molar and oral rehabilitation with implants. Even with little bone height between the floor of the maxillary sinus and the crest of the alveolar ridge, the professional opted for immediate implant installation after extraction, but when returning after 90 days, the implant had moved into the sinus. The implant was removed using the modified Caldwell-Luc technique, which consists of making a bone window in the lateral wall of the maxillary sinus, removing the fragment, replacing the bone window, and suturing the previously folded flap. Therefore, it can be concluded that the Caldwell-Luc technique benefits the closure of the bone defect, avoids fistulas and the area of fibrosis in the membrane, being an effective and viable alternative for removing implants in the maxillary sinus region.

Keywords: Mouth rehabilitation; Surgery oral; Maxillary sinus; Maxillary sinusitis.

Resumo

A instalação de implantes imediatos após exodontias vem se tornando uma prática comum na clínica odontológica. Durante este procedimento cirúrgico intercorrências como o deslocamento de implante dentário para o interior do seio maxilar podem ocorrer devido a estreita relação do assoalho do seio maxilar com os dentes superiores. Nestes casos o tratamento consiste na remoção do implante que foi deslocado com intuito de se prevenir futuras complicações como sinusite maxilar e fístula oroantral. O objetivo do presente trabalho é apresentar um caso clínico no qual a remoção de implante de seio maxilar foi realizada através da Técnica de Caldwell-Luc modificada. Paciente procurou uma clínica particular para exodontia do segundo molar superior esquerdo e reabilitação oral com implantes. Mesmo com pouca altura óssea entre o assoalho do seio maxilar e a crista do rebordo alveolar, o profissional optou por fazer a instalação imediata de implantes após a exodontia, mas ao retornar após 90 dias, o implante havia se deslocado para o interior do seio. A remoção do implante se deu pela técnica de Caldwell-Luc modificada que consiste na

confeção de uma janela óssea na parede lateral do seio maxilar, remoção do fragmento, reposição da janela óssea e sutura do retalho previamente rebatido. Sendo assim pode-se concluir que a técnica de Caldwell-Luc traz como benefício o fechamento do defeito ósseo, evita fístulas e área de fibrose na membrana sendo uma alternativa eficaz e viável para remoção de implantes na região do seio maxilar.

Palavras-chave: Reabilitação bucal; Cirurgia bucal; Seio maxilar; Sinusite maxilar.

Resumen

La instalación de implantes inmediatos tras la extracción de dientes se está convirtiendo en una práctica habitual en la clínica dental. Durante este procedimiento quirúrgico, pueden ocurrir complicaciones como el desplazamiento de los implantes dentales hacia el seno maxilar debido a la estrecha relación entre el piso del seno maxilar y los dientes superiores. En estos casos, el tratamiento consiste en retirar el implante que se ha desplazado para prevenir futuras complicaciones como sinusitis maxilar y fístula oroantral. El objetivo del presente estudio es presentar un caso clínico en el que se realizó la extracción del implante de seno maxilar mediante la técnica de Caldwell-Luc modificada. El paciente acudió a una clínica privada para la extracción del segundo molar superior izquierdo y rehabilitación oral con implantes. Incluso con poca altura ósea entre el piso del seno maxilar y la cresta del reborde alveolar, el profesional optó por la instalación inmediata del implante después de la extracción, pero al regresar a los 90 días, el implante se había movido hacia el seno. El implante se retiró mediante la técnica de Caldwell-Luc modificada, que consiste en realizar una ventana ósea en la pared lateral del seno maxilar, retirar el fragmento, reponer la ventana ósea y suturar el colgajo previamente plegado. Por tanto, se puede concluir que la técnica de Caldwell-Luc beneficia el cierre del defecto óseo, evita fístulas y la zona de fibrosis en la membrana, siendo una alternativa eficaz, viable para la extracción de implantes en la región del seno maxilar.

Palabras clave: Rehabilitación bucal; Cirugía bucal; Seno maxilar; Sinusitis maxilar.

1. Introduction

Introduced in the late 1970s, the concept of implants installed immediately after tooth extraction has become increasingly popular in dental clinics over the past few years. This growing success is largely due to the preservation of the patient's aesthetics, reduction of

clinical and surgical time, maintenance of alveolar walls and especially by avoiding alveolar bone resorption, common after a certain period of tooth extraction, which has been reflected in good prognosis (Del Fabbro, Boggian & Taschieri, 2009 and Hegde, Prasad, Shetty & Shetty, 2013).

However, the posterior region of the maxilla proves to be a challenge to perform this procedure right after extraction, when compared to other regions of the maxillary-mandibular complex, this because of its lower bone quality, presenting thin bony cortical and bone trabecular with great porosity (Albuquerque et al, 2014). Often, rehabilitation with immediate implants in these regions is still hampered by the phenomenon of pneumatization of the maxillary sinus and its proximity to the apex of the posterior teeth (Miloró, Ghali, Larsen & Waite, 2009).

To obtain greater criteria and safety in the rehabilitation with implants, especially in cases of low quantity and bone quality between the crest of the alveolar ridge and the floor of the maxillary sinus, the use of short implants and the procedure of elevating the floor of the maxillary sinus, which may or may not be associated with bone graft (Cavezzi Junior & Abdala Junior, 2013). These bone conditions, when present, limit the possibility of immediate rehabilitation, due to the great chances of several accidents and complications associated with the procedure, including the displacement of the implant itself into the maxillary sinus (Vergara & Caffesse, 2003 and Cavezzi Junior & Abdala Junior, 2013).

The displacement of foreign bodies into the maxillary sinus, such as a dental implant, may or may not be associated with signs and symptoms of sinus infection, but due to their potential to trigger such reactions, they must be removed in order to prevent them (Chiapasco et al. 2009 and Ueda & Kaneda, 1992 and Iida, Tanaka, Kogo & Matsuya, 2000).

Currently, the main means of removing foreign bodies from the interior of the maxillary sinus consists of endoscopic surgery (Kitamura, 2006 and Kim, Lee, Kwon & Kim, 2006), removal through the oral cavity by the Caldwell-Luc technique (Cavezzi Junior & Abdala Junior, 2013 and Ueda & Kaneda, 1992) or even the association of techniques, according to the individual need of the case. Although more invasive, the Caldwell-Luc technique offers better visualization of the operative field, facilitating access to the region, in addition to being able to be performed under local anesthesia (Cavezzi Junior & Abdala Junior, 2013).

2. Methodology

The work in question deals with a case report in a qualitative and descriptive way, with the objective of demonstrating the removal of a maxillary sinus implant using the modified Caldwell-Luc Technique, as well as its indications, of a patient attended at the dental school of Araçatuba UNESP/SP - Brazil. (Delanora et al. 2020).

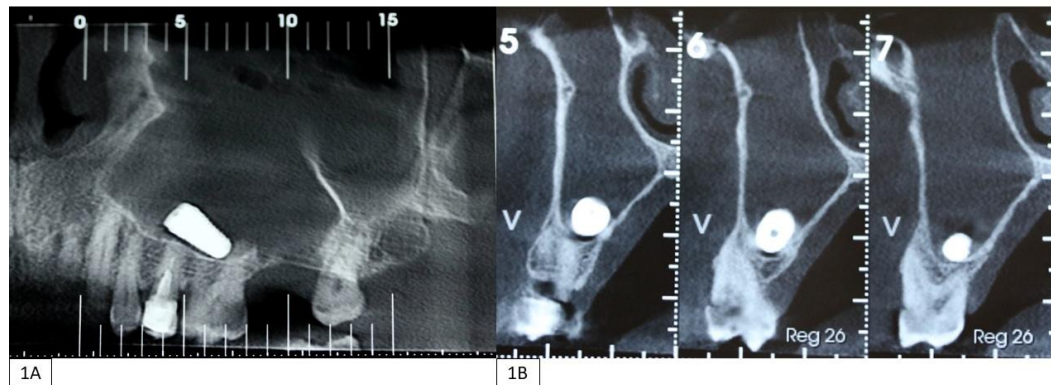
3. Case Report

A female patient, 50 years old, sought a private clinic for extraction of the left upper second molar and oral rehabilitation with implants at the extraction site. Even with little bone height between the floor of the maxillary sinus and the crest of the alveolar ridge, the dental surgeon chose to install the implant immediately after extraction. After 90 days, the patient attended the dental clinic for reopening surgery and the implant was no longer inserted in the alveolar ridge. The patient was then referred to São Paulo State University (Unesp), School of Dentistry, Araçatuba, so that the migration of the dental implant into the maxillary sinus could be treated.

In the anamnesis, the patient reported not having any systemic comorbidities, allergies, nor being a smoker or regularly drinking alcoholic beverages. In both the extra and intraoral exams, the patient did not present any noteworthy changes. However, the patient complained of paranasal discomfort.

On complementary imaging examination, using computed tomography (Figures 1A and 1B), the presence of a foreign body displaced into the left maxillary sinus was observed.

Figure 1A. Pre-surgical computed tomography by sagittal cut, showing the dental implant inside the maxillary sinus. **Figure 1B:** Coronal sections from pre-surgical computed tomography, showing the implant body inside the maxillary sinus.



Source: Personal archive.

Figure 1 shows the pre-surgical computed tomography showing the body of the dental implant that had been installed in the region of the left upper second molar and moved into the maxillary sinus; in A through the sagittal cut and in B through the coronal cuts.

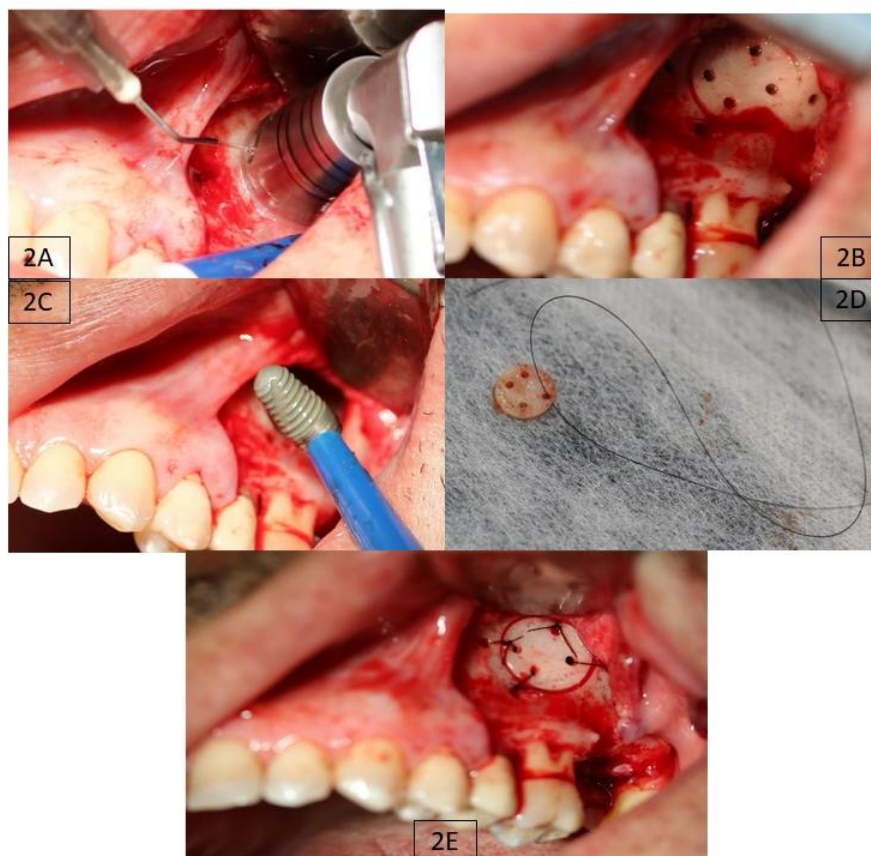
After receiving all the necessary guidance, opting for the treatment modality and complying with the procedures to be adopted, the patient signed the free and informed consent form, so that the treatment plan could be carried out with written consent.

For surgery, a preoperative drug regimen consisting of Dexamethasone 8 mg was prescribed, one hour before the procedure. Facial asepsis was performed with 10 mg / mL chlorhexidine digluconate and oral asepsis with 0.12% chlorhexidine digluconate. Anesthesia was performed with Mepivacaine 2% with adrenaline 1: 100000 in the regions of the posterior superior alveolar nerve, major palatine nerve and also through the infiltrative terminal technique in maxillary fornix.

The intraoral surgical technique for accessing the maxillary sinus through the modified Caldwell-Luc access, under local anesthesia, was chosen as the treatment method. Initially, the Novac-Peter incision was made and the mucoperiosteal flap was elevated to allow visualization of the surgical field, then a bone window was opened in the lateral wall of the maxillary sinus, through osteotomy with a trephine drill (10mm) coupled to an implant contra-angle under irrigation with saline solution (0,9%) (Figures 2A and 2B). After making the window, the sinus membrane was gently incised in order to enter the maxillary sinus and access the implant there. Once located, in the second premolar and first molar region, the apprehension was performed with the aid of the surgical sucker (Figure 2C). Perforations were made in the bone fragment removed from the maxillary sinus wall and in the vicinity of the surgical store in order to

stabilize the bone fragment through sutures with nylon 4.0 suture thread (Figure 2D). The membrane was sutured with Vicryl 6.0 thread and, finally, the flap was repositioned and sutured with Nylon 5.0 suture thread (Figure 2E).

Figure 2A. Making the bone window on the lateral wall of the maxillary sinus, through osteotomy with a trephine drill attached to an implant contra-angle under abundant irrigation with saline. **Figure 2B:** Bone window construction region after using the trephine drill. **Figure 2C:** Removal of the dental implant from inside the maxillary sinus with the aid of a surgical sucker. **Figure 2D:** Bone fragment removed from the lateral wall of the maxillary sinus with perforations made to facilitate subsequent suture. **Figure 2E:** Bone fragment repositioned and already sutured in the place where the bone window was opened.



Source: Personal archive.

Figure 2 shows the steps of the surgical procedure to perform the modified Caldwell-Luc access to remove the dental implant from inside the maxillary sinus. In A, the sinus lateral wall osteotomy is performed with a trephine drill under abundant irrigation, in B the bone aspect is evidenced after the osteotomy, in C the removal of the dental implant from inside the cavity is shown with the aid of a surgical sucker and in D the bone fragment removed from the

bone window, with some perforations made to facilitate the subsequent suture. Finally, in E, the bone fragment already repositioned and sutured at the location where the surgical access was performed is shown.

After surgery, the patient received printed and verbal care instructions, in addition to the prescription of Amoxicillin (Neo Química, SP, Brazil) three times a day for 8 days. It was also prescribed the use of nasal spray decongestant (Rinosoro® Farmasa, SP, Brazil) every 4 hours for 15 days and analgesic (sodium dipyrone - Eurofarma Laboratories Ltda., SP, Brazil) 30 drops 4 times a day in the first 72 hours for the control of post-surgical inflammatory symptomatology. The patient was instructed to wash the region with 0.12% chlorhexidine digluconate in a 20ml disposable syringe, twice a day for a period of 8 days, in order to control the microbial biofilm. Within 7 days, sutures were removed without complications.

The 30-day postoperative follow-up was very satisfactory, with no signs of irregularity or complaints. The patient is undergoing routine clinical follow-up, with a good healing aspect, regression of the post-surgical edema and without presenting complications, sinus changes or symptomatic complaints.

4. Discussion

There are countless benefits intrinsic to the technique of immediate implant installation, such as less bone resorption, preservation of patient aesthetics and reduction of treatment time and costs, many of them helping to reflect on a better prognosis (Hegde, Prasad, Shetty & Shetty, 2013 and Vergara & Caffesse, 2003). However, the procedure still presents considerably greater risks of complications, especially in the posterior region of the maxilla, due to the anatomical proximity between the floor of the maxillary sinus and the oral cavity (Kilic, Kamburoglu, Yuksel & Ozen. 2010), which may result in migrations, such as this clinical case.

There are several causes for both accidents and post-surgical complications associated with the installation of dental implants, such as displacement into the maxillary sinus. These cases, although rare, already have reports in the literature, including not only displacements to the maxillary sinus, but also sphenoid sinus (Felisati, Lozza, Chiapasco, & Borloni. 2007), ethmoidal sinus (Haben, Balys & Frenkiel. 2003), orbit (Kluppel et al. 2009) and cranial fossa (Cascone et al. 2010 and Cavezzi Junior & Abdala Junior, 2013). Among the causes for these occurrences, especially in the posterior region of the maxilla, the insufficient quantity and/or bone quality available at the installation site stands out, due to alveolar bone resorption or even

by the phenomenon of pneumatization of the maxillary sinus (Kluppel et al 2009 and Albuquerque et al, 2014).

The displacement of foreign bodies into the maxillary sinus, and the associated infections, such as maxillary sinusitis and oroantral fistula, are apparently sporadic and rarely reported (Iida, Tanaka, Kogo & Matsuya, 2000). But authors estimate that, with the significant increase in the placement of immediate implants in the posterior region of the maxilla, these complications will increase proportionately in the near future (Chiapasco et al. 2009). These tissue responses occur as a reaction of the maxillary sinus membrane in front of the foreign body that remains in contact, generating risks of the installation of inflammatory / infectious processes for hindering mucociliary flow. Therefore, removal is important as a form of prevention (Kim, Lee, Kwon & Kim, 2006 and Ueda & Kaneda, 1992).

Among the main approaches for removing foreign bodies, such as a dental implant, from the interior of the maxillary sinus are the Caldwell-Luc technique, through a direct access with the oral cavity (Ueda & Kaneda, 1992 and Cavezzi Junior & Abdala Junior, 2013) and by the endoscopic technique (Kim, Lee, Kwon & Kim, 2006 and Kitamura, 2006). Despite the current advances in the endoscopic technique, many indications for the Caldwell-Luc procedure remain, among them for the removal of foreign bodies, repair of oroantral fistulas, metaplasia with mucociliary system failure and failures in endoscopic surgeries (Cutler et al. 2003).

Studies indicate positive results related to the Caldwell-Luc technique regarding the regeneration of the sinus mucosa, better healing and less inflammatory cells in the region, when compared to the endoscopic technique (Cutler et al. 2003). In addition, the possibility of performing the procedure only under local anesthesia, generates less comorbidity to the patient and may reflect on a better prognosis (Cavezzi Junior & Abdala Junior, 2013).

Formatting of funding sources

This research did not receive any specific grant from funding agencies in the public, commercial, or not-for-profit sectors.

5. Final Considerations

Therefore, to avoid inflammatory / infectious responses resulting from migrations of dental implants to the interior of the maxillary sinus, it can be concluded that removal is always indicated. For this purpose, the Caldwell-Luc technique has the benefit of closing the

bone defect, preventing fistulas and area of fibrosis in the membrane, being an effective and viable alternative for removing implants in the maxillary sinus region.

References

Albuquerque, A., Cardoso, I., Da Silva, J., Germano, A., Dantas, W., & Gondim, A. (2014). Levantamento de Seio maxilar utilizando osso liofilizado associado a instalação imediata de implante do tipo cone morse: relato de caso. *Revista Da Faculdade De Odontologia - UPF*, 19(1).

Cascone, P., Ungari, C., Filiaci, F., Gabriele, G., & Ramieri, V. (2010). A dental implant in the anterior cranial fossae. *International Journal Of Oral And Maxillofacial Surgery*, 39(1), 92-93.

Cavezzi Junior, O., & Abdala Junior, R. (2013). Deslocamento de implante dentário para o seio maxilar: relato de caso. *Revista Portuguesa De Estomatologia, Medicina Dentária E Cirurgia Maxilofacial*, 54(4), 228-233.

Chiapasco, M., Felisati, G., Maccari, A., Borloni, R., Gatti, F., & Di Leo, F. (2009). The management of complications following displacement of oral implants in the paranasal sinuses: a multicenter clinical report and proposed treatment protocols. *International Journal Of Oral And Maxillofacial Surgery*, 38(12), 1273-1278.

Cutler, J., Duncavage, J., Matheny, K., Cross, J., Miman, M., & Oh, C. (2003). Results of Caldwell-Luc After Failed Endoscopic Middle Meatus Antrostomy in Patients With Chronic Sinusitis. *The Laryngoscope*, 113(12), 2148-2150.

Delanora, L. A., Souza, F. Ávila, da Costa, M. G., Faverani, L. P., & Bassi, A. P. F. (2020). Face injury by elastomer ammunition with important sequel: case report and brief literature review. *Research, Society and Development*, 9(9), e61996899.

Del Fabbro, M., Boggian, C., & Taschieri, S. (2009). Immediate Implant Placement Into Fresh Extraction Sites With Chronic Periapical Pathologic Features Combined With Plasma

Rich in Growth Factors: Preliminary Results of Single-Cohort Study. *Journal Of Oral And Maxillofacial Surgery*, 67(11), 2476-2484.

Felisati, G., Lozza, P., Chiapasco, M., & Borloni, R. (2007). Endoscopic removal of an unusual foreign body in the sphenoid sinus: an oral implant. *Clinical Oral Implants Research*, 18(6), 776-780.

Haben, M., Balys, R., & Frenkiel, S. (2003). Dental Implant Migration into the Ethmoid Sinus. *The Journal Of Otolaryngology*, 32(05), 342.

Hegde, R., Krishna Prasad, D., Shetty, D., & Shetty, M. (2014). Immediate Placement and Restoration of Implant in Periapical Infected Site in the Maxillary Esthetic Zone: A Case Report. *The Journal Of Indian Prosthodontic Society*, 14(S1), 299-302.

Iida, S., Tanaka, N., Kogo, M., & Matsuya, T. (2000). Migration of a dental implant into the maxillary sinus. *International Journal Of Oral And Maxillofacial Surgery*, 29(5), 358-359.

Kim, J., Lee, C., Kwon, T., & Kim, D. (2007). Endoscopic removal of a dental implant through a middle meatal antrostomy. *British Journal Of Oral And Maxillofacial Surgery*, 45(5), 408-409.

Kitamura, A. (2007). Removal of a migrated dental implant from a maxillary sinus by transnasal endoscopy. *British Journal Of Oral And Maxillofacial Surgery*, 45(5), 410-411.

Kluppel, L., Santos, S., Olate, S., Freire Filho, F., Moreira, R., & de Moraes, M. (2009). Implant migration into maxillary sinus: description of two asymptomatic cases. *Oral And Maxillofacial Surgery*, 14(1), 63-66.

Kilic, C., Kamburoglu, K., Yuksel, S. P., & Ozen, T. (2010). An Assessment of the Relationship between the Maxillary Sinus Floor and the Maxillary Posterior Teeth Root Tips Using Dental Cone-beam Computerized Tomography. *European journal of dentistry*, 4(4), 462-467.

Miloro, M., Ghali, G., Larse, P., & Waite, P. (2011). Peterson's Principles of Oral and Maxillofacial Surgery (3rd ed.). People's Medical Publishing House.

Ueda, M., & Kaneda, T. (1992). Maxillary sinusitis caused by dental implants: Report of two cases. Journal Of Oral And Maxillofacial Surgery, 50(3), 285-287.

Vergara, J., & Caffesse, R. (2003). Immediate Replacement of Single Upper Posterior Teeth: A Report of Cases. Clinical Implant Dentistry And Related Research, 5(2), 130-136.

Percentage of contribution of each author in the manuscript

Jucelía Maciel – 14%

Albanir Gabriel Borrasca – 14%

Leonardo Alan Delanora – 16%

Maria Eloise de Sá Simon – 14%

Nathália Januário de Araujo – 14%

Leonardo Perez Faverani – 14%

Idelmo Rangel Garcia Júnior – 14%