

Atrophic mandibular fracture treatment: prototyping as a tool in surgical planning

Tratamento de fratura de mandíbula atrófica: prototipagem como ferramenta no planejamento cirúrgico

Tratamiento de la fractura atrofica de la mandibula: prototipos como herramienta de planificación quirúrgica

Received: 28/08/2020 | Reviewed: 03/09/2020 | Accept: 06/09/2020 | Published: 07/09/2020

Reginaldo Fernandes da Silva

ORCID: <https://orcid.org/0000-0002-1734-6150>

Emergency and Trauma Hospital Dom Luiz Gonzaga Fernandes, Brazil

E-mail: regis.ferns@hotmail.com

Rebeca Valeska Soares Pereira

ORCID: <https://orcid.org/0000-0001-5376-6446>

Emergency and Trauma Hospital Dom Luiz Gonzaga Fernandes, Brazil

E-mail: rebecavaleska@gmail.com

Joana de Ângelis Alves Silva

ORCID: <https://orcid.org/0000-0001-6820-880X>

Emergency and Trauma Hospital Dom Luiz Gonzaga Fernandes, Brazil

E-mail: joanaangel22@hotmail.com

Gustavo José de Luna Campos

ORCID: <https://orcid.org/0000-0003-3540-8084>

Emergency and Trauma Hospital Dom Luiz Gonzaga Fernandes, Brazil

E-mail: camposctbmf@yahoo.com.br

Mário César Furtado da Costa

ORCID: <https://orcid.org/0000-0003-4125-3955>

Emergency and Trauma Hospital Dom Luiz Gonzaga Fernandes, Brazil

E-mail: marioddi@hotmail.com

Flaviano Falcão de Araújo

ORCID: <https://orcid.org/0000-0002-5434-6192>

Emergency and Trauma Hospital Dom Luiz Gonzaga Fernandes, Brazil

E-mail: flafalc@gmail.com

Abstract

Introduction: Atrophic mandibular fractures are injuries found in old age due to facial trauma. Its treatment is a challenge, even for experienced surgeons, due to the different approaches that can be taken from clinical decisions. Taking into consideration the limitations that the age presented by most of the affected patients brings, there are devices that stand out by seeking benefits in terms of predictability and time gain in the intraoperative period. The additive manufacturing is a valuable resource in the surgical planning and rehabilitation of these patients. **Objective:** To expose a clinical case that demonstrates the success in the use of surgical planning through a prototype printed in 3D technology. **Clinical case:** Elderly woman, 75 years old, victim of a fall from her own height who had a bilateral atrophic mandible fracture due to facial trauma. The surgical procedure was planned using a prototype printed in 3D technology providing predictability and reduced surgical time. The patient evolved in the postoperative period without complaints, with function immediately restored and without signs of infection or plate exposure. **Conclusions:** Atrophic mandible fractures are still related to a challenging treatment, therefore, adequate surgical planning and the use of auxiliary strategies such as 3D prototyping provide greater predictability of results, as well as time gain during the intraoperative.

Keywords: Mandibular fractures; Edentulous; 3-Dimensional printings.

Resumo

Introdução: As fraturas em mandíbula atrófica são lesões encontradas na terceira idade decorrentes de traumas na face. O tratamento, mostra-se como um desafio, inclusive para cirurgiões experientes pelas diversas abordagens que podem ser realizadas a partir das decisões clínicas. Levando em considerações as limitações que a idade apresentada pela maior parte dos pacientes acometidos traz, destacam-se artifícios que visam benefícios quanto a previsibilidade e ganho de tempo no transoperatório. A manufatura aditiva é um recurso valioso no planejamento operatório e reabilitação destes pacientes. **Objetivo:** Expor caso clínico que demonstra o sucesso no uso do planejamento cirúrgico por meio de um protótipo impresso em tecnologia 3D. **Caso clínico:** Idosa com 75 anos, vítima de queda da própria altura que apresentou fratura de mandíbula atrófica bilateral decorrente do trauma em face. Teve seu procedimento cirúrgico planejado por meio de protótipo impresso em tecnologia 3D, proporcionando previsibilidade e tempo cirúrgico reduzido. Paciente evoluiu no pós-operatório sem queixas, com função restabelecida de forma imediata e sem sinais de infecção ou exposição da placa. **Conclusões:** As fraturas de mandíbula atrófica ainda são consideradas

de tratamento desafiador, dessa forma, um planejamento cirúrgico adequado e o uso de estratégias auxiliares como a prototipagem 3D proporcionam maior previsibilidade de resultados, bem como, ganho de tempo no transoperatório.

Palavras-chave: Fratura mandibular; Arcada edêntula; Impressão em 3D.

Resumen

Introducción: Las fracturas en la mandíbula atrófica son lesiones que se encuentran en la vejez por traumatismo facial. El tratamiento es un desafío, incluso para cirujanos experimentados, debido a los diferentes enfoques que se pueden realizar en función de las decisiones clínicas. Teniendo en cuenta las limitaciones que trae la edad que presenta la mayoría de los pacientes afectados, existen dispositivos que buscan beneficios en cuanto a previsibilidad y ganancia de tiempo durante la operación. La fabricación aditiva es un recurso valioso en la planificación operativa y la rehabilitación de estos pacientes. Objetivo: Exponer un caso clínico que demuestre el éxito en el uso de la planificación quirúrgica a través de un prototipo impreso en tecnología 3D. Caso clínico: anciana de 75 años, víctima de una caída desde su propia altura que presenta una fractura atrófica bilateral de mandíbula por traumatismo facial. Su procedimiento quirúrgico se planificó utilizando un prototipo impreso en tecnología 3D, proporcionando previsibilidad y reducido tiempo quirúrgico. El paciente evolucionó en el postoperatorio sin quejas, con la función inmediatamente restaurada y sin signos de infección o exposición a placa. Conclusiones: Las fracturas atróficas de mandíbula todavía se consideran un tratamiento desafiante, por lo que la planificación quirúrgica adecuada y el uso de estrategias auxiliares como el prototipado 3D brindan una mayor predictibilidad de resultados, así como un ahorro de tiempo durante la operación.

Palabras clave: Fracturas mandibulares; Arcada edêntula; Impresión tridimensional.

1. Introduction

The edentulous mandible is more vulnerable to the occurrence of bone fractures, through trauma, due to the decrease in volume resulting from a series of biological mechanisms that cause the loss of the alveolar process. This phenomenon causes a progressive atrophy in this bone, weakening it (Wittwer et al., 2006; Brucoli et al., 2019; Maloney & Rutner, 2019).

The treatment of atrophic mandible fracture is considered challenging due to a number of characteristics, among which, those stand out: the age of the patient, who is often elderly,

with comorbidities associated with increased operative risks, compromised bone quality, reduced osteogenesis and fragments with reduced contact area that hinder the healing process (Wittwer et al., 2006; Shuker, 2015).

The open reduction of the fractures and the internal fixation are considered the gold standard of treatment and the most predictable method of managing atrophic mandibular fractures due to the benefits of recovering function immediately (Wittwer et al., 2006; Melo et al., 2011). Usually this type of fracture is fixed with a 2.4 system plate that exhibits an adequate mechanic resistance due to its thickness, this fact requires more time during the modeling process (Mardones, 2011).

The incorporation of health technology through image exams, such as computed tomography and magnetic resonance, allows the acquisition of images in three dimensions that provide a view of anatomical regions, contributing to the correct diagnosis and appropriate therapy for each patient (Liu et al., 2006; Rosa et al., 2004).

In recent years, Rapid Prototyping has demonstrated promise in helping medical and dental professionals to plan and execute surgical procedures. This technology is characterized by biomodels of human anatomy in 3D, created from the combination of the images obtained and computer systems, Computer Aided Design (CAD) and Computer Aided Manufacturing (CAM). Taking into account the area of actuation of Maxillofacial Surgery and Traumatology, the Rapid Prototyping provides benefits for preoperative planning and shortening surgery time (Safira et al., 2010).

The aging of the population turns the occurrence of this type of fracture an increasingly common event, consequently, it is necessary that the surgeons are prepared to make agile and satisfactory therapeutic decisions for the management of these patients. Thus, a clinical case is presented, in which the use of health technology through obtaining 3D prototyping was part of the planning process for the treatment of the atrophic mandible fracture through pre-modeling the plate that was used for a stable fixation of the fractured segments.

2. Methodology

This paper is characterized as descriptive observational case report. In the literature, scientific articles were searched, taking into consideration the theme addressed for review and support of the clinical case performed, through the Medline database, using PubMed and LILACS as search devices.

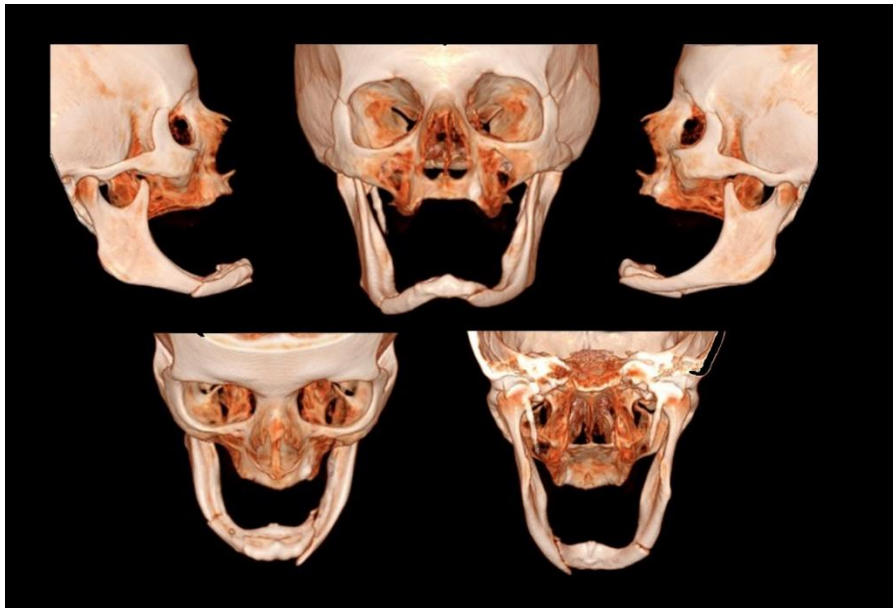
The use of a qualitative approach is emphasized, in which the researcher's perspective is important for interpretation taking into account his opinions about the studied phenomenon (Pereira et al., 2018), thus, adding scientific and technological knowledge applied to conduct clinic. It should be noted that the patient was aware of each treatment step, as well as, signed the free and informed consent form (ICF).

3. Case Report

Female patient, 75 years old, leukoderma, taken to the Hospital of Emergency and Trauma Dom Luiz Gonzaga Fernandes, in the city of Campina Grande, Paraíba, Brazil, by her family members with main complaint of pain to eat after a trauma in the face due to a fall from her own height. After being evaluated by General Surgery, with the release of this specialty, she was referred for assistance with Maxillofacial Surgery and Traumatology. Upon anamnesis, the patient reported a history of glaucoma, as well as pharmacologically controlled arterial hypertension. On clinical examination, the presence of uneven bone stumps in the right basilar was detected, as well as absence of limited mouth opening, ecchymosis in the left mental/submandibular region, and preserved laterality and protrusion movements.

A tomographic examination was performed and revealed a bilateral fracture of the atrophic mandible, located in the region of the right body and left parasymphysis, both with beveled characteristics. The fracture on the left side presented greater displacement compared to the one found on the contralateral side.

Figure 1 - 3D tomographic reconstruction in the preoperative period. Note the bilateral mandible fracture with beveling and slight displacement present.




Source: Authors (2020).

The tomography images were saved in DICOM format (Digital Imaging and Communications in Medicine) and sent to the Three-dimensional Technologies Laboratory (LT3D) of the Strategic Technologies in Health Center, Unit 2, located at the Hospital of Emergency and Trauma Dom Luiz Gonzaga Fernandes. In this Center, treatment procedures and necessary adequations were realized to obtain the 3D printing of the biomodel by the engineering team, using the STL (Stereolithography) process on the Form2 machines (Formlabs ©), using Standard Gray Resin (photocurable polymer), with printing time of 5h45min and 3h of processing.

Considering the patient's age, associated comorbidities and gain in intraoperative time, the surgical planning was made in the biomodel. Osteotomies of the fractured regions were performed for adequate reduction, taking into account the condylar position. For the ideal alignment maintenance, cyanoacrylate was used.

In order to proceed with the mandibular reconstruction, a 2.4 system plate with 16 holes modeled from the prototype before the surgical procedure was selected, consequently, it was possible to provide a favorable adaptation, the evaluation of the amount of screws that were necessary for fixing the plate, as well as their distribution.

Figure 2 - Prototyped model of fractured mandible with repositioned segment. A. Reconstruction plate before modeling. B. Modeled plate. C, D: Plate adapted to the model after modeling.

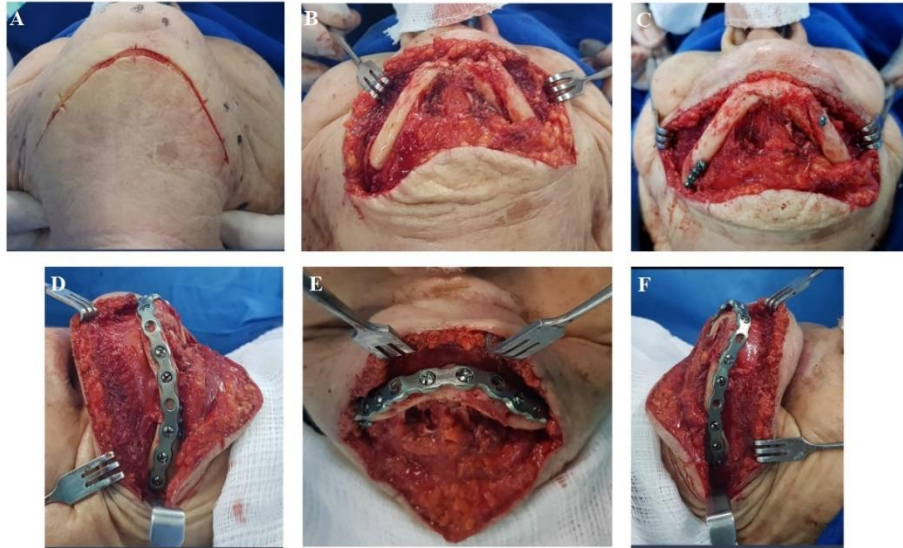


Source: Authors (2020).

Among the preoperative exams performed, including Hemogram, Coagulation test, Urea, Creatinine and Fasting Glucose, all of them presented values within those considered normal. The Degree of Cardiological Risk was defined as II, with the release of Cardiology specialty for the surgical procedure.

The surgery was performed under general anesthesia, the approach started by extended submandibular access for better visualization, anatomical reduction and fixation of the bone fractures. The simplification of bone fractures was performed using a 2.0 system plate, containing four holes, fixed with four screws in the right body basilar region and one screw using the “Lag Screw” technique in the left parasymphysis region. The reconstruction was made in the biomodel, with the pre-modeled 2.4 system plate, fixed using 12 bicortical screws with the pre-programmed distribution, without the need for new modeling. The plate and screws used for the simplification of the fractures were removed after fixing the reconstruction plate. The closure was due to tissue plans using Vicryl 3.0 and Nylon 5.0.

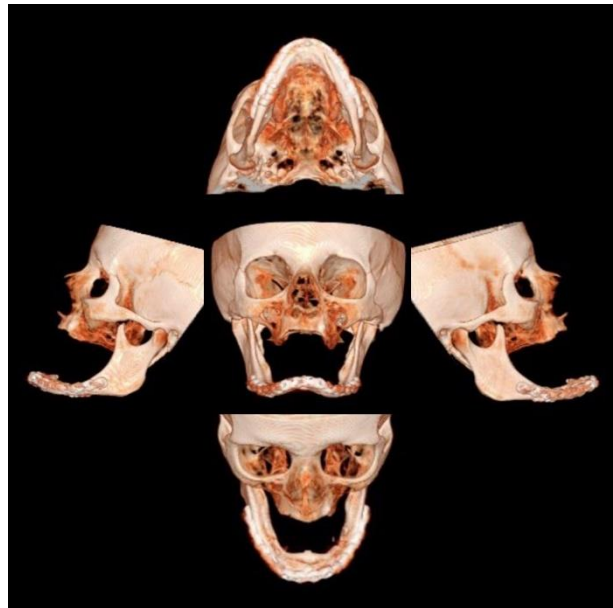Figure 3 - Transoperative images. A: Submandibular access extended. B: Exposure of bone fractures. C: Fracture reduction with the aid of 2.0 mm system plates and screws. D, E, F: Front and profile view of the reconstruction plate adaptation in the atrophic mandible.



Source: Authors (2020).

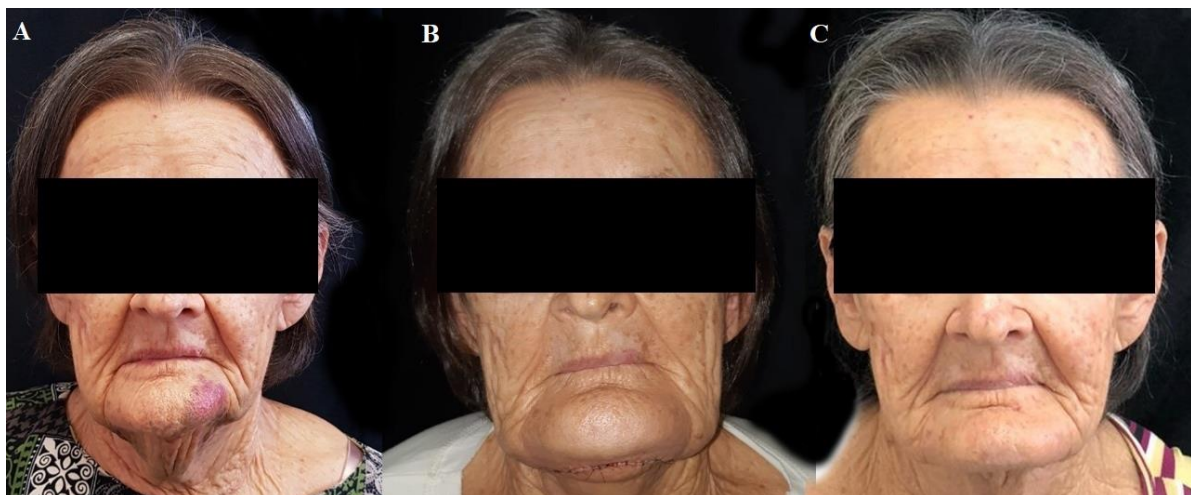In the postoperative period, the tomography performed demonstrated that the bone reduction and fixation were performed favorably with the reconstruction plate respecting the anatomical contour of the mandible. The patient evolved well, without associated complaints, as well as with a satisfactory mouth opening and preserved laterality and protrusion movements, with no signs of suture dehiscence or intraoral exposure of the fixation material.

Figure 4 - 3D tomographic reconstruction in the postoperative period. The good adaptation of the plaque is emphasized, restoring the mandibular contour.



Source: Authors (2020).

Figure 5 - Front view photo of the patient. A: Preoperative showing ecchymosis in the left parasphysis region and loss of mandibular contour. B: 7 days postoperative. C: 6 months postoperative with restored form and function.



Source: Authors (2020).

4. Discussion

The atrophy is characterized when the vertical height of the mandible is 20 mm or less, the weakening of this mandibular structure tends to occur due to decreased vascularization

and blood flow with tooth loss (Barber, 2001).

A study carried out in Russia (Pankratov & Melkumova, 2000) demonstrated that the occurrence of fractures in the elderly population occurs about 1.5 times more in edentulous patients than in those with toothed segments, being directly related to the fragility that affects the mandible in the process of physiological resorption of the alveolar ridge.

The most common etiology of mandibular fractures in elderly people was a fall in several studies in the literature (Nishiike et al., 2002; Brucoli et al., 2019; Melo et al., 2011), as well as how occurred with the patient of this case. Studies indicate that with adequate preparation and management, open surgical techniques regain function and bring immediate benefits to patients (Marciani, 2001; Wittwer et al., 2006; Melo et al., 2011).

Brucoli et al. (2019) conducted a study in which the average age of patients who had an atrophic mandible fracture was 75 years old. Studies highlight, considering the average age of patients, the presence of a high percentage of subjects with reports of one or more comorbidities (Brucoli et al., 2019; Maloney & Rutner, 2019; Castro-Núñez et al., 2018). These characteristics are in common with the patient in the case described.

In the study conducted by Melo et al. (2011), 41,17% of the patients had bilateral mandible fracture. The most affected region was the mandibular body, followed by the parasymphysis region. Corroborating the described tomographic findings.

In Luhr class III jaws (where the thickness of the bone is less than 10 mm), the prominence of the chin, together with the dramatically thinner body and parasymphysis regions, determine a change in the biomechanics of mandibular fractures: in this case, the body and the parasymphysis become the most frequent regions of fractures (Brucoli et al., 2019). This information brought from the literature corroborates with the profile of the fractures that occurred with the treated patient, the thickness of the atrophic mandible was 8 mm, being characterized as a Luhr class III.

The extraoral approach during the surgical approach avoids the complete periosteal removal of the mandible, thus reducing risks related to infection or exposure of plates (Hachleitner et al., 2014; Brucoli et al., 2020). Still, in Luhr class III, the inferior alveolar nerve is found in the most superior part of the alveolar crest, hindering an intraoral approach (Brucoli et al., 2020). The risk of damage to the facial nerve is a negative factor mentioned in the literature, as a consequence of the extraoral approach (Aziz & Najjar, 2009), however, there was no damage to it during the extraoral approach.

The AO principles in the treatment of atrophic mandible fracture recommend the reduction of the fracture and the immediate restoration of function, indicating that they should

be seen as a typical load bearing situation, in which, after the reduction, they must be stabilized with a 2.4 system reconstruction plate that shows greater resistance during the modeling process (Brucoli et al., 2020). Based on these principles, this system was used for the mandibular reconstruction.

Computed Tomography provides the images in a file format known as DICOM, this file is converted and its images are processed in specific programs for the STL format (Stereolithography), which consist of a set of 3D data responsible to form the prototype printed using the CAM system on specific printers (Sugar et al., 2004).

In surgeries that require a detailed planning, as well as a prediction of the results, as in the case of pathological lesions that cause structural bone weakness (Castro-Núñez et al., 2018), atrophic mandible fracture (Shuker, 2015), in implantology (Zhou et al., 2012), prototyping can be used. This tool has a great value in anatomical measurement, in the simulation of fracture reduction, osteotomies, resection techniques, assisting in the complete surgical planning (Kupfer et al., 2016).

Taking into account the advanced age of most patients who have atrophic mandible fractures, as well as the existence of associated comorbidities, the benefits provided by the use of biomodels should be considered for management. Among these benefits are surgery time interval shortening, consequently, the reduction of the period of the patient staying under general anesthesia and the risk of infection (Brito et al., 2016). Still, Maloney & Rutner (2019) emphasize the more precise adaptation of the plate to the bone anatomy of the mandible, compared to when the modeling is performed during the intraoperative period.

Martelli et al. (2016), in his systematic review where he analyzed 158 articles on topics related to the use of additive manufacturing technology in surgical procedures, between 2005 to 2015, highlighted the benefits related to its application as being: the multiple possibilities in preoperative planning, the anatomical precision that the biomodels provide and the reduced surgical time. These benefits are also emphasized during the conduction and explanation of the case.

The modeling of the plate used in the fixation allowed by the preparation of the biomodel in the preoperative period, also performed in other similar studies (Kupfer et al., 2016; Brito et al., 2016; Castro-Núñez et al., 2018; Maloney & Rutner, 2019), reduced the surgical time in approximately one hour.

5. Conclusion

Obtaining biomodels through additive manufacturing have great importance in the health area, with an emphasis on Maxillofacial Surgery and Traumatology, as demonstrated in this study. When there is an opportunity for the surgeon to use this tool, he provides benefits for the patient that range from the predictability of the procedure, reduction in surgical time, as well as an immediate recovery of function, especially in cases of patients with atrophic mandible fracture. Thus, the use of health technology devices is encouraged when available, such as prototyping, in order to reestablish the patient's health and well-being state.

References

Aziz, S. R., & Najjar, T. (2009). Management of the edentulous/atrophic mandibular fracture. *Atlas Oral Maxillofac Surg Clin North Am.*, 17(1), 75-79.

Barber, H. D. (2001). Conservative management of the fractured atrophic edentulous mandible. *Journal of Oral and Maxillofacial Surgery*, 59(7), 789-91.

Brito, N. M., Soares, R. S., Monteiro, E. L., Martins, S. C., Cavalcante, J. R., Grempel, R. G., & Neto, J. A. (2016). Additive Manufacturing for Surgical Planning of Mandibular Fracture. *Acta Stomatol Croat.*, 50(4), 348-353.

Brucoli, M., Boffano, P., Romeo, I., Corio, C., Benech, A., Ruslin, M., Forouzanfar, T., Rodríguez-Santamarta, T., Carlos de Vicente, J., Tarle, M., Dediol, E., Pechalova, P., Pavlov, N., Daskalov, H., Doykova, I., Kelemith, K., Tamme, T., Kopchal, A., Shumynsyi, I., Corre, P., Bertin, H., Bourry, M., Guyonvarc'h, P., Dovsak, T., Vozlic, D., Birk, A., Anicic, B., Konstantinovic, V. S., & Starch-Jesen, T. (2020). Surgical management of unilateral body fractures of the edentulous atrophic mandible. *Oral Maxillofac Surg.*, 24(1), 65-71.

Brucoli, M., Boffano, P., Romeo, I., Corio, C., Benech, A., Ruslin, M., Forouzanfar, T., Rodríguez-Santamarta, T., Carlos de Vicente, J., Tarle, M., Dediol, E., Pechalova, P., Pavlov, N., Daskalov, H., Doykova, I., Kelemith, K., Tamme, T., Kopchal, A., Shumynsyi, I., Corre, P., Bertin, H., Bourry, M., Guyonvarc'h, P., Dovsak, T., Vozlic, D., Birk, A., Anicic, B.,

Konstantinovic, V. S., & Starch-Jesen, T. (2019). The epidemiology of edentulous atrophic mandibular fractures in Europe. *J Craniomaxillofac Surg.*, 47(12), 1929-1934.

Castro-Núñez, J., Shelton, J. M., Snyder, S., & Sickels, J. V. (2018). Virtual Surgical Planning for the Management of Severe Atrophic Mandible Fractures. *Craniomaxillofac Trauma Reconstr.*, 11(2), 150-156.

Hachleitner, J., Enzinger, S., Brandtner, C., & Gaggl, A. (2014). The role of the titanium functionally dynamic bridging plate for the treatment of the atrophic mandible fractures. *J Craniomaxillofac Surg.*, 42(5), 438-42.

Kupfer, P., Saadad, N., & Hughes, P. J. (2016). Open reduction and internal fixation of bilateral atrophic mandible fractures utilizing virtual surgical planning, custom cutting guides and reconstruction plate. A case report. *J Oral Maxillofac Surg.*, 74(9), 74-89.

Liu, Q., Leu, M. C., & Schmitt, S. M. (2006). Rapid prototyping in dentistry: technology and application. *Int. J. Adv Manuf Technol.*, 29, 317-335.

Maloney, K. D., & Rutner, T. (2019). Virtual Surgical Planning and Hardware Fabrication Prior to Open Reduction and Internal Fixation of Atrophic Edentulous Mandible Fractures. *Craniomaxillofac Trauma Reconstr.*, 12(2), 156-162.

Marciani, R. D. (2001). Invasive management of the fractured atrophic edentulous mandible. *Journal of Oral and Maxillofacial Surgery*, 59(7), 792-5.

Mardones, M. M. (2011). Tratamiento de fracturas em mandíbulas atroficas: presentación de dos casos clinicos. *Int J Odontostomat.*, 5(2), 126-132.

Martelli, N., Serrano, C., van den Brink, H., Pineau, J., Prognon, P., Borget, I., & El Batti, S. (2016). Advantages and disadvantages of 3-dimensional printing in surgery: A systematic review. *Surgery*, 159(6), 1485-1500.

Melo, A. R., de Aguiar Soares Carneiro, S. C., Leal, J. L., & Vasconcelos, B. C. (2011). Fracture of the atrophic mandible: case series and critical review. *J Oral Maxillofac Surg*, 69(5), 1430-1435.

Nishiike, S., Sakata, Y., Kato, T., Nagai, M., & Konishi, M. (2002). 35 mandibular fracture cases. *Nippon Jibiinkoka Gakkai Kaiho*, 105(10), 1065-70.

Pankratov, A. S., & Melkumova, A. I. (2000). The clinical characteristics of mandibular fractures in middle-aged and elderly subjects. *Stomatologiya (Mosk)*, 79(4), 28-33.

Pereira, A. S., Shitsuka, D. M., Parreira, F. J., & Shitsuka, R. (2018). *Metodologia do trabalho científico. [e-Book]*. Santa Maria. Ed. UAB/NTE/UFSM. Retrieved from https://repositorio.ufsm.br/bitstream/handle/1/15824/Lic_Computacao_Metodologia_Pesquisa-Cientifica.pdf.

Rosa, E. L. S., Oleskovictz, C. F., & Aragão, B. N. (2004). Rapid prototyping in maxillofacial surgery and traumatology: case report. *Braz Dent J.*, 15(3), 243-7.

Safira, L. C., Costa Bastos, L., Beal, V. B., de Azevedo, R. A., Francischone, C. E., & Sarmiento, V. A. (2010). Accuracy of rapid prototyping biomodels plotted by three dimensional printing technique: ex vivo study. *ACT.*, 2(2), 41-45.

Shuker, S. T. (2015). Interrami intraoral fixation technique utilized as a conservative approach to edentulous/atrophicmandibular fractures. *J Craniofac Surg.*, 26(3), 677-9.

Sugar, A., Bibb, R., Morris, C., & Parkhouse J. (2004). The development of a collaborative medical modeling service: organizational and technical considerations. *Br J Oral Maxillofac Surg.*, 42(4), 323-30.

Wittwer, G., Adeyemo, W. L., Turhani, D., & Ploder, O. (2006). Treatment of atrophic mandibular fractures based on the degree of atrophy--experience with different plating systems: a retrospective study. *J Oral Maxillofac Surg.*, 64(2), 230-4.

Zhou, L., Shang, H., Feng, Z., Ding, Y., Liu, W., Li, D., Zhao, J., & Liu, Y. (2012). Prototyped flexible grafting tray for reconstruction of mandibular defects. *Br J Oral Maxillofac Surg.*, 50(5), 435-9.

Percentage of contribution of each author in the manuscript

Reginaldo Fernandes da Silva – 18%

Rebeca Valeska Soares Pereira – 18%

Joana de Ângelis Alves Silva – 14%

Gustavo José de Luna Campos – 14%

Mário César Furtado da Costa – 18%

Flaviano Falcão de Araújo – 18%