

Colles external fixator as alternative in comminuted mandibular fractures treatment

**Fixador externo Colles como alternativa no tratamento de fraturas mandibulares
cominutivas**

**Fijador externo de Colles como alternativa en el tratamiento de fracturas mandibulares
conminutas**

Received: 08/30/2020 | Reviewed: 09/09/2020 | Accept: 09/21/2020 | Published: 09/23/2020

Luiz Henrique Soares Torres

ORCID: <https://orcid.org/0000-0003-3652-3754>

São Paulo State University, Brazil

E-mail: luiz-lhst@hotmail.com

Caio Pimenteira Uchoa

ORCID: <https://orcid.org/0000-0002-6937-0267>

University of Pernambuco, Brazil

Oswaldo Cruz University Hospital, Brazil

E-mail: caiopuch@gamil.com

Mateus Barros Cavalcante

ORCID: <https://orcid.org/0000-0002-6842-2416>

University of Pernambuco, Brazil

Oswaldo Cruz University Hospital, Brazil

E-mail: mateus_bcf@hotmail.com

Virgílio Bernardino Ferraz Jardim

ORCID: <https://orcid.org/0000-0001-5462-1599>

University of Pernambuco, Brazil

Oswaldo Cruz University Hospital, Brazil

E-mail: virgilioferraz84@hotmail.com

Éwerton Daniel Rocha Rodrigues

ORCID: <https://orcid.org/0000-0003-1969-8288>

University of Pernambuco, Brazil

Oswaldo Cruz University Hospital, Brazil

E-mail: ewertondaniel27@hotmail.com

Rebeca Valeska Soares Pereira

ORCID: <https://orcid.org/0000-0001-5376-6446>

Dom Luiz Gonzaga Fernandes Emergency and Trauma Hospital, Brazil

E-mail: rebecavaleska@gmail.com

Luiza Monzoli Côvre

ORCID: <https://orcid.org/0000-0001-6983-9910>

São Paulo State University, Brazil

E-mail: lumcovre@gmail.com

Belmiro Cavalcanti do Egito Vasconcelos

ORCID: <https://orcid.org/0000-0002-6515-1489>

University of Pernambuco, Brazil

Oswaldo Cruz University Hospital, Brazil

E-mail: belmirovasconcelos@gmail.com

Emanuel Dias de Oliveria e Silva

ORCID: <https://orcid.org/0000-0002-7482-7815>

University of Pernambuco, Brazil

Oswaldo Cruz University Hospital, Brazil

E-mail: luiz.lhst@gmail.com

Valfrido Antônio Pereira Filho

<https://orcid.org/0000-0001-8736-7507>

São Paulo State University, Brazil

E-mail: valfrido.pereira-filho@unesp.br

Abstract

Objective: to report a surgical case of comminuted mandible fracture caused by a firearm projectile treated with external fixation. Methodology: male patient, 18 years old, attended the Emergency Department of the Maxillofacial Surgery service after trauma in the mandibular region by a firearm projectile. On clinical examination, edema was observed in the cervical zone II and mandibular region, penetrating orifice of entry of the projectile in the genial region and mobility in the mandibular body. CT scan revealed a comminuted fracture in the mandible. Transcutaneous perforations were performed with pins, anatomical reduction of the fracture and stabilization to the external nail, adapting to the mandibular anatomy. Following postoperative follow-up, the patient progresses without pain complaints, with functional and satisfactory mouth opening, without mobility in bone fragments, and reestablished mandibular

framework. Results and Conclusion: mandibular fractures by firearms are frequent in the routine of the buccomaxillofacial surgeon. Cases of bone comminution present individual peculiarities that must be taken into account in their management. The correct indication of external fixation proved to be adequate and satisfactory for cases of mandible comminution.

Keywords: Mandible; External fixators; Gunshot wounds.

Resumo

Objetivo: relatar um caso cirúrgico de fratura cominutiva de mandíbula por projétil de arma de fogo tratado com fixação externa. Metodologia: paciente gênero masculino, 18 anos de idade, compareceu ao Pronto Atendimento do serviço de Cirurgia Bucomaxilofacial após trauma em região mandibular por projétil de arma de fogo. Ao exame clínico, foi observado edema em zona cervical II e região mandibular, orifício penetrante de entrada do projétil em região geniana e mobilidade em corpo mandibular. Ao exame tomográfico foi percebida fratura cominutiva em mandíbula. Realizou-se perfurações transcutâneas com pinos, redução anatômica da fratura e estabilização à haste externa, adaptando-se a anatomia mandibular. Em acompanhamento pós-operatório, o paciente evolui sem queixas álgicas, com abertura bucal funcional e satisfatória, sem mobilidade nos fragmentos ósseos, arcabouço mandibular restabelecido. Resultados e Conclusão: as fraturas mandibulares por arma de fogo são frequentes na rotina do cirurgião Bucomaxilofacial. Casos de cominuição óssea apresentam particularidades individuais que devem ser levadas em consideração em seu manejo. A correta indicação da fixação externa mostrou-se adequada e satisfatória para casos de cominuição de mandíbula.

Palavras-chave: Mandíbula; Fixadores externos; Ferimentos por arma de fogo.

Resumen

Objetivo: reportar un caso quirúrgico de fractura conminuta de mandíbula por proyectil de arma de fuego tratado con fijación externa. Metodología: paciente masculino de 18 años que acudió al Servicio de Urgencias del servicio de Cirugía Maxilofacial tras traumatismo en región mandibular por proyectil de arma de fuego. Al examen clínico se observó edema en la zona cervical II y región mandibular, un orificio penetrante para la entrada del proyectil en la región genial y movilidad en el cuerpo mandibular. La tomografía computarizada reveló una fractura conminuta en la mandíbula. Se realizaron perforaciones transcutáneas con clavos, reducción anatómica de la fractura y estabilización al clavo externo, adaptándose a la anatomía mandibular. En el seguimiento postoperatorio el paciente evoluciona sin quejas de

dolor, con apertura bucal funcional y satisfactoria, sin movilidad en fragmentos óseos y marco mandibular reestablecido. Resultados y Conclusión: las fracturas mandibulares por arma de fuego son frecuentes en la rutina del cirujano buccomaxilofacial. Los casos de conminución ósea presentan peculiaridades individuales que deben tenerse en cuenta en su manejo. La correcta indicación de la fijación externa resultó ser adecuada y satisfactoria para los casos de conminución mandibular.

Palabras clave: Mandíbula; Fijadores externos; Heridas por arma de fuego.

1. Introduction

In the last years the management of mandibular fractures due to firearm injury has undergone significant changes. Several treatments are reported in the literature, including the use of steel wires, maxillomandibular block, internal fixation with miniplates and screws and, in some cases, the use of external fixation (Ellis & Bretta, 2007; Ellis, Muniz & Anand, 2009).

The treatment of comminuted mandibular fractures by firearm injury is still a controversial thematic when it comes to knowing the best moment for the surgical approach (Abreu et al. 2009), as well as to which fixation method is the ideal and can be used in all cases. Some factors influence in the conduct and decision making, such as the bad dentition, the inadequate nutrition of the patients, soft tissue and bone fragments aspect, fixation materials availability and surgeon's experience (Holmes, Hardee & Anand, 2002).

In the beginning, the accepted idea for treating these fractures included the maxim that surgical exploration would lead to loss of blood supply of bone fragments, what would cause a bigger incidence of bone sequestration, necrosis and outbreaks of infection, but this theory was modified (Smith & Teenier, 1996). Another modified factor refers to the idea of "sterile injury", it is now known that the heat generated by the propellant discharge and friction between the bullet and the cylinder are not sufficient to sterilize the projectile, what justifies those being contaminated injuries (Abreu et al. 2009).

Currently most of these lesions have been treated with open reduction and the use of functionally stable internal fixation. This technique provides the return of the mandibular form and function, good bone consolidation and enables some comfort to the patient² however, the use of external fixators is an option for treating mandibular firearm injuries, and is now an uncommon choice in the treatment of these fractures (Gibbons, Mackenzie & Breederveld, 2011) nevertheless, when correctly indicated, it is an effective therapy.

The objective of this paper is to present a clinic case of comminuted fracture in the mandibular body region caused by a firearm injury, treated with an orthopedic device of external fixation, as well as to discuss about indications, limitations, management and clinic experiences showing that, when correctly conducted, the use of these fixators is a viable alternative in the surgical treatment of traumas caused by firearm injuries in the mandibular region.

2. Methodology

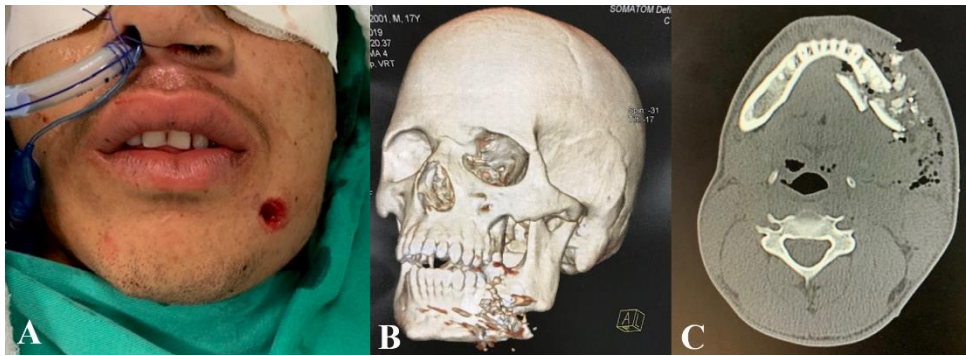
A descriptive observational study was carried out, whose objective is to present, by means of a case report and bibliographic survey, scientific data on the topic addressed. (Pereira, et al., 2018). The study has a descriptive and qualitative content, once that it considers the studied reality and intends to expose the details. There was no need for approval by the Research Ethics Committee, considering that it is a case report. However, the patient authorized the use of images, clinical, radiographic and socioeconomic data for educational and research purposes and signed an informed consent form (ICF).

3. Case Report

Patient, male gender, 18 years old, victim of a firearm injury in the left mandibular body region, attended the emergency care unity at the Bucco maxillofacial surgery and traumatology service of the Hospital da Restauração – Recife/PE. Upon physical evaluation, an edema in the mandibular region and cervical zone II was observed, penetrating orifice of the projectile in the genian region without exit injury as shown in figure 1.A. Acceptable intraoral hygiene condition, mobility and crackling in the mandible and pain during the manipulation was noticed. Vascular Surgery feedback and image exam were requested for a secondary evaluation.

Figure 1 (B and C) shows the computed tomographic and angiotomographic examination, respectively, demonstrated hyperdense fragments, suggesting projectile shrapnel, comminuted fracture in the mandibular body, presence of *bone gap* and vascular injury in the external jugular vein. Based on the information collected from the anamnesis, images and discussion with the Vascular Surgery team, a surgical approach to the fracture and observation of the edema and venous injury in the cervical region were chosen.

Figure 1. Initial clinical aspect and tomographic examination.

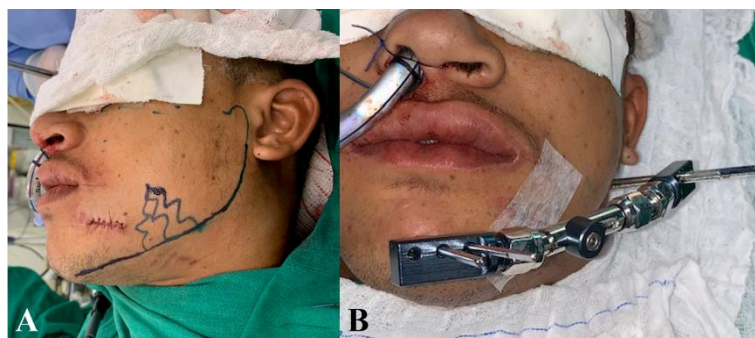

Source: Own author.

Note the initial surgical aspect (gunshot injury) and the three-dimensional reconstruction of the preoperative computed tomography and axial views with bone fragments.

In the intraoperative time, a maxillary-mandibular blockade using steel wire was performed, surgical cleaning with copious irrigation with 0.9% saline and 2% chlorhexidine, removal of viable projectile fragments and suture of the entrance orifice. Closed fracture treatment and stabilization using the external fixation system were chosen by adapting an external wrist fixation – Colles fixator. Methylene blue was used for demarcating the fracture zone and the mandibular base; through small incisions and transcutaneous trocar. Figure 2 (A and B) demonstrate the four bicortical pins installed, two on each side of the fracture, united by the articulated nail of the fixator, adapting itself to the mandibular anatomy, where it was adjusted and fixed. Posteriorly, the maxillary-mandibular blockade was removed.

Figure 2. Trans-operative aspect and immediate follow-up of external fixator installation.



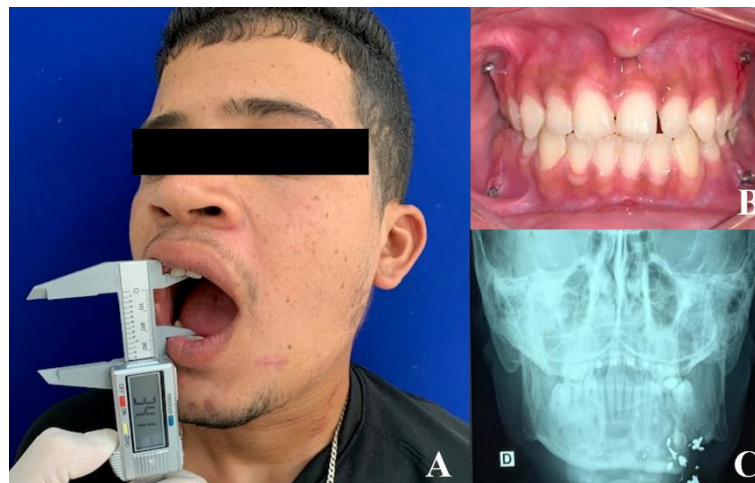Source: Own author.

The schematization of the mandibular base and fracture zone is an auxiliary method to emphasize the bone fragments and planning. The intraoperative aspect of the external fixator of Colles in mandibular positioning.

After the surgical manipulation, a significant increase in the edema located in the cervical region was noticed, and a new opinion from the vascular surgery was requested, opting for the surgical approach at this second moment.

In the immediate postoperative period, elastic bands were installed to stabilize and guide the occlusion, maintained for 60 days. Figure 3A shows the outpatient follow-up, with a satisfactory mouth opening, absence of pain, infection, and mobility. Antibiotic therapy and care guidelines for the transcutaneous pins, oral hygiene, diet and physical therapy were followed. As shown in the Figure 3 (B and C), the fixator was removed after two months under local anesthesia. In the six-month postoperative radiograph evaluation, a local bone callus formation was noted and functional occlusion was noted.

Figure 3. 6-month follow-up. Mouth opening, occlusion and radiograph outcomes.



Source: Own author.

Note the six-month postoperative mouth opening outcome (34.1mm). The occlusion after 30 days follow-up is satisfactory. The pos-operative radiograph shows the bone fracture consolidation.

4. Discussion

The literature reports that the mandibular fracture is the second in incident in relation to the total facial fractures, being surpassed only by cases of nasal fractures (Zarpellon et al.

2015). In general, physical aggression and car accidents are the most frequent trauma mechanisms, however in the Brazilian northeast region, accidents and firearm aggression are more prevalent (Pita Neto et al. 2018).

In open surgical treatment to comminuted mandible fractures, mucoperiosteal detachment is necessary, what causes a possible vascular impairment of the region, increasing the incidence of non-bone union and infections. Adding this situation to the firearm aggression, these complications become more commonly contaminated (Braidy & Ziccardi, 2009).

In firearm injuries, the projectile velocity, mass and design strongly influence the wound production, as the interaction of each of these factors provides varying amounts of kinetic energy, thus generating a range of injuries, from classic comminuted fractures to more complex injuries, with tissue avulsions, bone dislocations, airway obstructions and major vascular contaminated lesions. Currently, although the use of external fixation is less common, in specific cases it is recommended, either as an initial and definitive approach or as a second choice for comminuted mandibular fractures initially treated with fixation with progression to osteomyelitis, bone sequestration and the need to remove bone synthesis material (Berryman, 2019; Gadicherla, Kamath, Aramanadka & Pentapati, 2018; Shukla, Kamath & Nayak, 2018).

The closed reduction and use of external fixation are an interesting alternative for patients with edema in the region to be addressed – as in this reported case. Opting for this procedure reduces the risk of injury to noble structures during the surgical approach, moreover, this choice is less morbid to the patient. The absence of permanent installation of osteosynthesis material, reduced procedure time and the avoidance of large extraoral incisions are other advantages of this technique (Braidy & Ziccardi, 2009; Katarzyna & Piotr, 2012).

However, high complication rates in mandibular fractures treated with external fixators are found, according to Cornelius et al., it is up to 35%. Postoperative infections, non-bone union, cellulitis around the transcutaneous pins, malocclusions and loosening of the pins. Nevertheless, these high numbers of cases with complications are also attributed to the nature of the trauma and the severity and complexity of the fractures (Cornelius, Augustin & Sailer, 2009).

In specific cases, the use of external fixation of Colles is shown to be an effective option in the treatment of complex mandibular lesions caused by firearm injuries. When correctly indicated, this treatment has lower morbidity when compared to the open treatment, allowing an adequate repair of bone and adjacent soft tissues and less potential for infection

when compared to the open treatment (Ellis, Muniz & Anand, 2009; Braidy & Ziccardi, 2009; Oredugba Folakemi & Nzomiwu Chioma, 20150

Although it is not formatted for the mandible, the external wrist fixator – Colles' fixator – can be successfully used to treat mandibular injuries. Some topographic limitations are found, there may be a need for a preoperative modeling of the external nail for a better mandibular contour or, depending on the mandibular area affected, small bends and movements are allowed by the orthopedic device itself – as in the reported case – presenting large versatility (Ribeiro et al. 2012; E.M, 2017; Alencar, Bortoli, Silva, Silva & Laureano Filho, 2018).

5. Final Considerations

The mandibular fractures by firearm are frequent in the maxillofacial surgeon's routine, being essential to understand the trauma mechanisms, to realize an accurate diagnosis and a correct approach to the trauma. Bone comminution cases have individual characteristics that should be taken into consideration in their management, as well as in the traumas caused by firearms.

It is known that there are several forms of treating comminuted mandibular fractures, and the use of an orthopedic device is an option in the range of possibilities. Moreover, it is noteworthy that the use of external fixation allowed a shorter surgical time and less morbidity to the patient, treatment effectiveness – when correctly indicated and conducted – and reduced cost – when compared to other fixing methods. In this case, although there was no bone repair for the first intention, even with the formation of the callus, the mandibular architecture was resumed, adapting the shape and function of the mandible.

Despite the advent of internal fixation with plates and bone screws, the external fixation of fractures still remains as a great management when well indicated. Future works should compare the effectiveness of this approach with conventional ones and explore the development of easily-handling devices with low patient morbidity.

References

Abreu, M. E. R., Viegas, V. N., Ibrahim, D., et al. (2009) Treatment of comminuted mandibular fractures: A critical review. *Med Oral Patol Oral Cir Bucal*. 14(5), e247-51.

Alencar, M. G. M., Bortoli, M. M., Silva, T. C. G. D., Silva, E. D. O. E., Laureano Filho JR. (2018) Suitability of wrist external fixator for treatment of mandibular fracture. *J craniofac surg.* (4),e371–2.

Berryman, H. E. (2019) A systematic approach to the interpretation of gunshot wound trauma to the cranium. *Forensic Sci Int.* 301(1),306-17.

Braidy, H. F., Ziccardi, V. B. (2009) External fixation for mandible fractures. *Atlas Oral Maxillofac Surg Clin North Am.* 17(1), 45-53.

Cornelius, C. P., Augustin, J. B., Sailer, L. K. (2009). External pin fixation for stabilization of the mandible-comeback of a method: historical review and first experiences with the ‘mandible external fixator’. *Oral Maxillofac Surg.* 13(1), 1-14.

Em, C. J., & Saputra, F. E. (2017) The evaluation of delayed treatment on dentoalveolar trauma by surgical reposition and wire-composite splint technique. *Journal of International Dental and Medical Research.* 10(2), 384-91.

Ellis, E., Bretta, A. M. (2007) Fractures of the Mandible: A Technical Perspective. *Plastic and Reconstructive Surgery.* 120(7 Suppl 2), 76s-89s.

Ellis, E., Muniz, O., Anand, K. (2003) Treatment Considerations for Comminuted Mandibular Fractures. *J Oral Maxillofac Surg.* 61(8), 861-70.

Gadicherla, S., Kamath A. T., Aramanadka, C., Pentapati, K. C. (2018) Oculocardiac reflex during zygomatico maxillary complex fracture management - a retrospective study. *J Int Dent Med Res.* 11(1), 243-7.

Gibbons, A. J., Mackenzie, N., Breederveld, R. S. (2011) Use of a custom designed external fixator system to treat ballistic injuries to the mandible. *Int. J. Oral Maxillofac. Surg.* 40(1):103-5.

Holmes, S., Hardee, P., Anand, P. (2002) Use of an orthopaedic fixator for external fixation of the mandible. *Br J Oral Maxillofac Surg.* 40(3):238-40.

Katarzyna, B., Piotr, A. (2012) Closed reduction and skeletal traction apparatus in the treatment of complete monofragment zygomatic tetrapod fractures. *Int Dent Med Res.* 5(2),60-6.

Oredugba Folakemi, A., Nzomiwu Chioma, L. (2015) Causes and pattern of traumatic dental injuries in children presenting for care at a tertiary health center. *J Int Dent Med Res.* 8(2):40-5.

Pita Neto, I. C., Franco, J. M. P. L., Araújo Junior, J. L., et al. (2018) Factors Associated with the Complexity of Facial Trauma. *The Journal of Craniofacial Surgery.* 29(6):e562-6.

Pereira, A. S., et al. (2018). *Metodologia da pesquisa científica*. [e-book]. Santa Maria. Ed. UAB/NTE/UFSM. Recuperado de https://repositorio.ufsm.br/bitstream/handle/1/15824/Lic_Computacao_Metodologia-Pesquisa-Cientifica.pdf?sequence=1.

Singh, A., & Solomon. C. (2017) Osteoid osteoma of the mandible: A case report with review of the literature. *J. Dent. Sci,* 12(2), 185-189.

Ribeiro, I. L. H., Cerqueira, L. S., Dultra, F. K., Dultra, J. A., Carneiro Junior, B., Azevedo R. A. (2012) Treatment for fracture mandibular of firearm with external fixation: case report. *R Ci Med Biol.* 11(3), 341-5

Shukla, A. D., Kamath, A. T., Nayak S. (2018) Use of ATLS protocol for the management of poly trauma patient with maxillofacial injuries. *Journal of International Dental and Medical Research.* 11(2), 482-5.

Smith, B. R., Teenier, T. J. (1996) Treatment of comminuted mandibular fractures by open reduction and rigid internal fixation. *J Oral Maxillofac Surg.* 54(3), 328-31.

Zarpellon, A. T., Cruz, G. O. A., Gus, I. O., Moreira, G. H. G., Chamma, R. S., De Masi F. D. J. (2015) Review of 150 cases of mandible fracture between 2010 and 2013 at the Cajuru University Hospital, Curitiba, PR. *Brazilian Journal of Plastic Surgery.* 30(4), 609-14.

Percentage of contribution of each author in the manuscript

Luiz Henrique Soares Torres - 10%

Caio Pimenteira Uchoa - 10%

Mateus Barros Cavalcante - 10%

Virgílio Bernardino Ferraz Jardim - 10%

Éwerton Daniel Rocha Rodrigues - 10%

Rebeca Valeska Soares Pereira - 10%

Luiza Monzoli Côvre - 10%

Belmiro Cavalcanti do Egito Vasconcelos - 10%

Emanuel Dias de Oliveria e Silva - 10%

Valfrido Antônio Pereira Filho - 10%