

Large-extension osteosarcoma with involvement of multiple maxillofacial structures: a rare case report

Osteossarcoma de grande extensão com envolvimento de múltiplas estruturas maxilofaciais: um relato de caso raro

Osteosarcoma de gran extensión con la participación de estructuras maxilofaciales múltiples: un informe de caso raro

Received: 09/14/2020 | Reviewed: 09/17/2020 | Accept: 09/19/2020 | Published: 09/21/2020

Rani Iani Costa Gonçalves

ORCID: <https://orcid.org/0000-0002-6762-135X>

Universidade Federal do Rio Grande do Norte, Brasil

E-mail: ranigoncalo@gmail.com

Cristianne Kalinne Santos Medeiros

ORCID: <https://orcid.org/0000-0003-2439-2523>

Universidade Federal do Rio Grande do Norte, Brasil

E-mail: cristiannekalinne@gmail.com

Humberto Pereira Chaves Neto

ORCID: <https://orcid.org/0000-0002-7556-536X>

Universidade Federal do Rio Grande do Norte, Brasil

E-mail: humbertopchaves@gmail.com

Janaina Lessa de Moraes dos Santos

ORCID: <https://orcid.org/0000-0002-8939-0839>

Universidade Federal do Rio Grande do Norte, Brasil

E-mail: janainalessa84@gmail.com

Adriano Rocha Germano

ORCID: <https://orcid.org/0000-0002-1661-8038>

Universidade Federal do Rio Grande do Norte, Brasil

E-mail: adrianorgermano@yahoo.com.br

Lélia Maria Guedes Queiroz

ORCID: <https://orcid.org/0000-0003-3380-0226>

Universidade Federal do Rio Grande do Norte, Brasil

E-mail: imgqueiroz@hotmail.com

Abstract

Background: Osteosarcoma is a malignant neoplasm that occurs most often in long bones, with the head and neck region being rarely affected, accounting for less than 1% of all cancers in this region. **Objective:** To report a rare case of a large-extension osteosarcoma with emphasis on its clinical and diagnostic aspects. **Case presentation:** A 43-year-old woman presenting an intraoral exophytic lesion with involvement of other maxillofacial structures, such as nostril, zygoma and orbit. Despite the initial clinical diagnosis of actinomyces, an incisional biopsy confirmed the histopathological diagnosis of osteosarcoma, showing a wide morphological variety. **Conclusion:** This case highlights the importance of clinical and histopathological findings for the correct diagnosis of osteosarcoma. Moreover, it shows that, although surgical resection is the primary treatment for this neoplasia, depending on the extent of the tumor and its proximity to vital anatomical structures, the most appropriate conduct is not always feasible.

Keywords: Oral cavity; Head and neck Neoplasms; Bone neoplasm; Osteosarcoma.

Resumo

Introdução: O osteossarcoma é uma neoplasia maligna que ocorre mais frequentemente em ossos longos, sendo a região da cabeça e pescoço raramente afetada, correspondendo a menos de 1% de todos os cânceres nessa região. **Objetivo:** Relatar um caso raro de osteossarcoma de grande extensão, com ênfase em seus aspectos clínicos e diagnósticos. **Apresentação do caso:** Mulher de 43 anos apresentando lesão exofítica intraoral com envolvimento de outras estruturas maxilofaciais, como narina, zigoma e órbita. Apesar do diagnóstico clínico inicial de actinomicose, a biópsia incisional confirmou o diagnóstico histopatológico de osteossarcoma, apresentando uma grande variedade morfológica. **Conclusão:** O caso clínico destaca a importância dos achados clínicos e histopatológicos para o diagnóstico correto do osteossarcoma. Além disso, mostra que, embora a ressecção cirúrgica seja o tratamento primário dessa neoplasia, dependendo da extensão do tumor e de sua proximidade com estruturas anatômicas vitais, a conduta mais adequada nem sempre é viável.

Palavras-chave: Cavidade oral; Neoplasias de cabeça e pescoço; Neoplasia óssea; Osteossarcoma.

Resumen

Introducción: El osteosarcoma es una neoplasia maligna que se presenta con mayor frecuencia en huesos largos, siendo raramente afectada la región de cabeza y cuello, lo que corresponde a

menos del 1% de todos los cánceres de esa región. Objetivo: Reportar un caso raro de osteosarcoma a gran escala, con énfasis en sus aspectos clínicos y diagnósticos. Presentación del caso: mujer de 43 años que presenta una lesión intraoral exofítica con afectación de otras estructuras maxilofaciales, como fosa nasal, cigoma y órbita. A pesar del diagnóstico clínico inicial de actinomicosis, la biopsia incisional confirmó el diagnóstico histopatológico de osteosarcoma, presentando una amplia variedad morfológica. Conclusión: El caso clínico destaca la importancia de los hallazgos clínicos e histopatológicos para el correcto diagnóstico del osteosarcoma. Además, muestra que, si bien la resección quirúrgica es el tratamiento primario de esta neoplasia, dependiendo de la extensión del tumor y su proximidad a estructuras anatómicas vitales, el abordaje más adecuado no siempre es factible.

Palabras clave: Cavidad oral; Neoplasias de cabeza y cuello; Neoplasia ósea; Osteosarcoma.

1. Introduction

Osteosarcoma is a malignant bone tumor characterized by the formation of bone or osteoids by tumor cells (Nissanka, Amaratunge & Tilakaratne, 2007; Chen et al., 2017; Krishnamurthy & Palaniappan, 2018). The tumor most commonly appears in the metaphases of the long bones of children and adolescents, and is rare in the head and neck, comprising from 6% to 10% of all osteosarcomas and less than 1% of all cancers located in this region (Nissanka et al., 2007; Laskar et al., 2008; Chen et al., 2017; Kimura et al., 2017; Krishnamurthy & Palaniappan, 2018). Despite its rarity in the oral-maxillofacial region, it is the second most common malignancy in this location in children and adolescents (de Arruda et al., 2017).

Contrary to what occurs in long bones, head and neck osteosarcoma affect individuals at a later stage, mainly in the third and fourth decades of life. In addition, metastasis is rare, although local recurrences are common (Laskar et al., 2008; Krishnamurthy & Palaniappan, 2018). In the oral and maxillofacial region, mandible is the most affected site, followed by maxilla and palate (de Carvalho et al., 2020). The tumor may be classified according to the most prevalent type of extracellular matrix, namely osteoblastic, chondroblastic and fibroblast (Nissanka et al., 2007; Krishnamurthy & Palaniappan, 2018). According to some studies, almost half of jaw osteosarcomas are chondroblastic (Nissanka et al., 2007; Laskar et al., 2008).

Surgical tumor resection is the main treatment, although there is no standard protocol regarding patient management (Laskar et al., 2008; Chen et al., 2017; Jeong, Lee, Nam, Cha,

Kim 2017; Krishnamurthy & Palaniappan, 2018). Some studies have shown that adjuvant chemotherapy leads to patient survival improvement (Nissanka et al., 2007; Chen et al., 2017; Liang et al., 2019). Within this context, the aim of this study is to report a rare case of maxillary osteosarcoma with extensive maxillofacial involvement, and to discuss the clinicopathological features and management.

2. Methodology

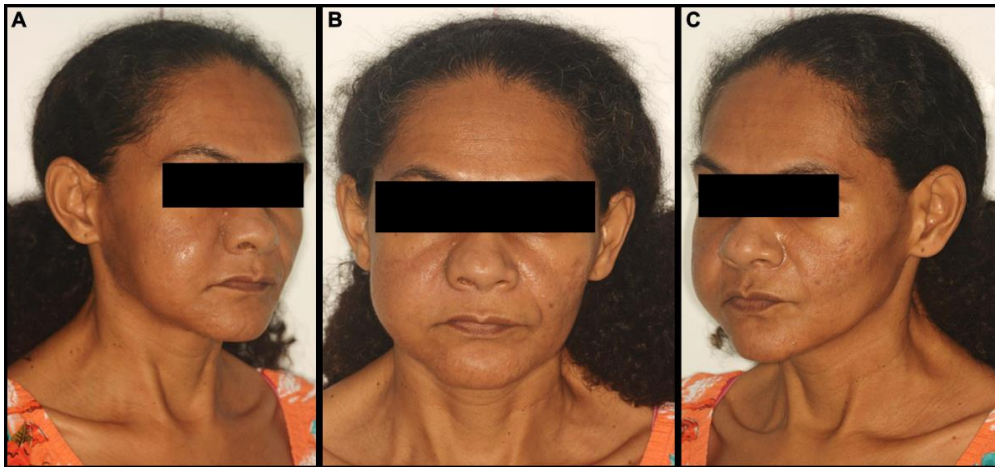
The present study consists of a descriptive and qualitative case study. According to Crowe et al. (2011), this type of study aims to provide insights into aspects of the clinical case and, in doing so, illustrate broader lessons that may be learned. Considering ethical aspects, the patient has previously authorized the anonymous divulgence of the present case upon signature of the Informed Consent Form, in which she declares to be aware of the treatment and use of medical records, radiographs and photographs for didactic use, research or dissemination in scientific journals, respecting the current code of ethics

As a means of complementing and supporting the study, a brief review of the literature was carried out based on the search for scientific articles in the MEDLINE database through the PubMed portal.

3. Case Report

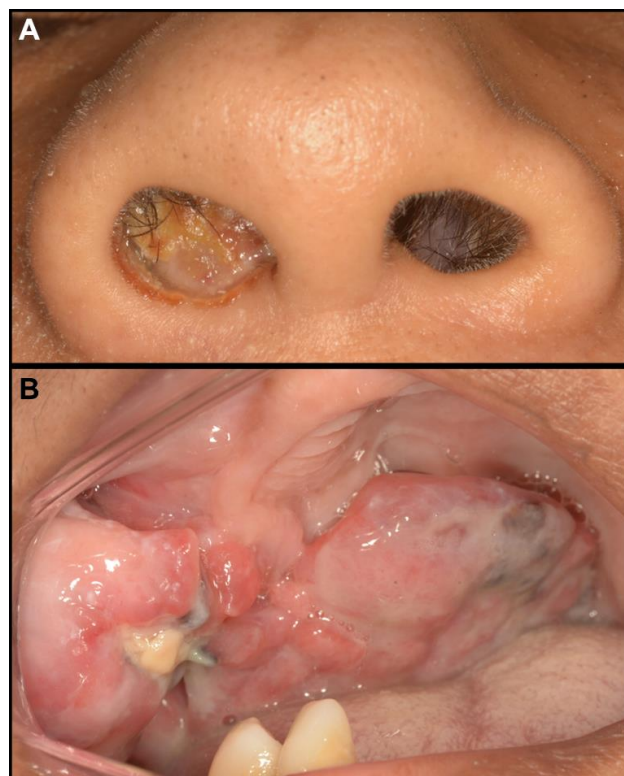
A 43-year-old female patient was referred to bucomaxillofacial service with the chief complaint of "facial pain" and swelling in the right hemiface (Figure 1). An exophysis tumor lesion was found upon physical examination, located in the right alveolar ridge and palate, extending to the ipsilateral nostril (Figure 2), presenting a partially ulcerated surface, mucosa-like color and a firm consistency, with painful symptomatology. In addition, the presence of a purulent secretion and unsatisfactory oral hygiene were observed. Due to the clinical presentation and the regression history after six-month antibiotic therapy, an initial diagnostic hypothesis of actinomycosis was suggested.

Figure 1 - Extraoral clinical features. (A) Increase of volume on the right hemiface. (B) At the frontal aspect, we observe facial asymmetry due to tumor growth. (C) Absence of alterations on the left facial aspect.



Source: Authors.

Figure 2 - Intraoral clinical features of the lesion. (A) Extensive tumoral lesion involving the hard palate region and right upper alveolar ridge. (B) Involvement of the right nasal mucosa.

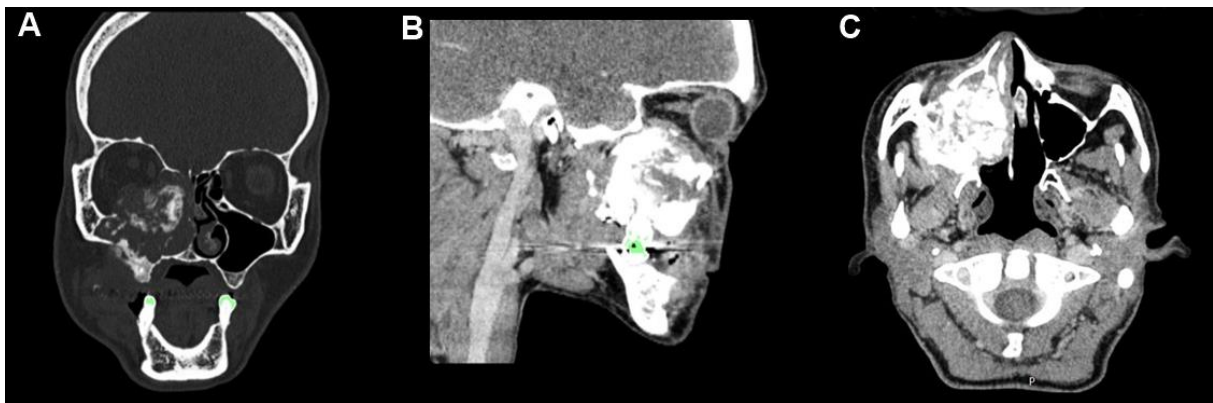

Source: Authors.

After performing a computed tomography scan, we observed the presence of a poorly defined lesion, demonstrating mixed hyperdensity and hypodensity areas, with complete

involvement of the maxillary right sinus, nasal cavity, orbital cavity, ethmoidal sinus, zygomatic bone and basilar region of the skull (Figures 3A, 2B and 2C).

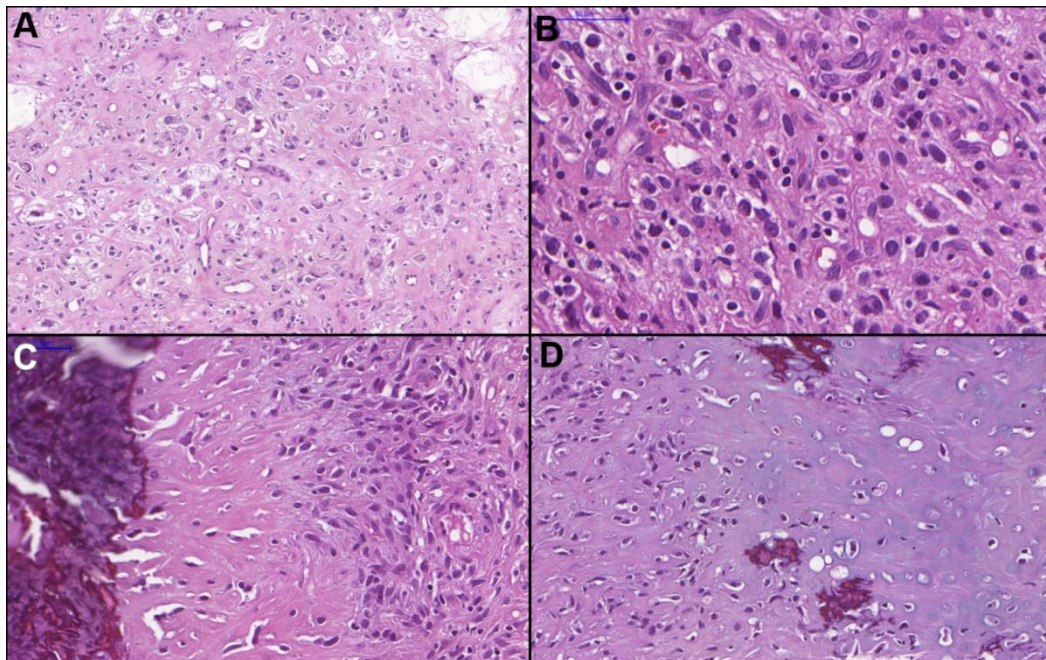
Figure 3 – Imaginological features. A, B, C- Computed tomography scans showing involvement by the lesion of multiple structures, such as nasal cavity, orbital cavity, ethmoidal sinus, zygomatic bone and basilar region of the skull.



Source: Authors.

An incisional biopsy and removal of multiple fragments were performed on the hard palate, alveolar ridge and right nostril. At histopathological examination, we observed a malignant neoplasm of mesenchymal origin, characterized by intense cellularity and bone and osteoid matrix deposition by neoplastic cells. These cells presented varied shapes, both rounded and fusiform, with an intense cellular and nuclear pleomorphism, hyperchromatic nuclei and eosinophilic cytoplasm also evidenced, with few mitosis figures. A chondroblastic differentiation of the matrix deposited by the malignant cells was observed in some areas. Based on the observed clinical and microscopic aspects, a histopathological osteosarcoma diagnosis was reached (Figure 4).

Figure 4 - Histopathological features. (A) Malignant mesenchymal cells proliferation exhibiting cellular atypia in amidst of a dense and hyalinized fibrous connective stroma (1.000 μm ; Haematoxylin/Eosin). (B) Infiltrate of inflammatory cells predominantly lymphocytic around the neoplastic cells (500 μm Haematoxylin/Eosin). (C) Mature bone (left) and deposition of osteoid matrix (center) by neoplastic cells (right) (500 μm ; Haematoxylin/Eosin). (D) Area presenting chondroblastic differentiation of the stroma (1.000 μm ; Haematoxylin/Eosin).



Source: Authors.

The patient was referred to a reference hospital in the region for treatment. Initially, the proposed treatment plan included the surgical removal of the lesion and 20 chemotherapy sessions. However, due to the absence of a surgical margin, resection was not possible. As a result of the lesion size, the patient presented compromised respiratory functions and had to perform a tracheostomy. In addition, a nasoenteric probe was installed to maintain the patient's diet. The patient then began chemotherapy, but only 3 sessions were performed, since the patient died.

4. Discussion

Osteosarcoma is a primary malignant bone tumor characterized by the production of immature bone. Due to its rarity in the head and neck region, studies and case reports that highlight the occurrence of this disease in this location are of great clinical relevance, thus

enabling proper diagnosis and clinical management. The present study highlights clinical, imaginological and histopathological features of a maxillofacial osteosarcoma in a 43-year-old female in order to provide physicians and dental surgeons a better understanding about the aspects of this disease.

Osteosarcoma etiology has not yet been fully elucidated. However, some predisposing factors are involved in its development, including previous exposure to radiation, Paget's disease, fibrous dysplasia, multiple osteochondromatosis and osteomyelitis. Ossificans trauma and myositis have also been mentioned as predisposing factors for osteosarcoma development (Nissanka et al., 2007; Yamamoto-Silva et al., 2017; Krishnamurthy & Palaniappan, 2018). It was not possible to identify which predisposing factor could have triggered the emergence of this malignity, as the patient did not present any systemic disorder or previous trauma in the tumor region.

As observed by Paparella et al., 2013, the female gender was more affected, and the mean age of patients was 43 ± 18 years, with incidence peak around the fifth decade of life. These findings agree with the present case. The most common osteosarcoma symptoms are enlargement of the affected area, pain, paresthesia and ulceration. In addition, nasal obstruction may be present when the tumor occurs in the maxilla (Yamamoto-Silva et al., 2017; Krishnamurthy & Palaniappan, 2018). However, these signs are also common to several other types of lesions, requiring complementary tests such as imaging and biopsies for a correct diagnosis. Regarding radiographic features, the sunburst pattern typical for long bone osteosarcomas are less evident in jaw bones osteosarcomas (Yildiz et al., 2014). A variety of benign lesions also clinically and morphologically overlap with low-grade osteosarcoma such as fibrous dysplasia, ossifying fibroma and desmoplastic fibroma (Demicco, Deshpande, Petur Nielsen, Kattapuram & Rosenberg, 2010; Kimura et al., 2017). In the present case, the initial clinical diagnosis of actinomycosis was established based only on clinical findings and history of lesion remission after previous antibiotic therapy, and the correct osteosarcoma diagnosis was established only by a histopathological analysis of the lesion.

The treatment of head and neck osteosarcoma is complicated due to the absence of universal protocols (DeAngelis et al., 2012; Chen et al., 2017; Kimura et al., 2017). Surgical tumor resection is the most commonly applied therapy and may be associated with chemotherapy. However, this anatomical region does not always present surgical access conditions and, in these cases, treatment options such as neoadjuvant chemotherapy have been indicated, although its role is still not clearly defined (Laskar et al., 2008; Thariat et al., 2013;

Krishnamurthy & Palaniappan, 2018). In the present case, it was not possible to surgically treat the tumor due to its size, consequently, contributing to the patient's decreased survival and death, even after beginning the chemotherapy treatment. Krishnamurthy and Palaniappan conducted a retrospective study in 2018, in which 14 patients with a mean age of 37 years who had received curative treatment for osteosarcoma of the head and neck region were evaluated. When analyzing several prognostic factors such as sex, age, anatomic location, histological variant, soft tissue extension and postoperative margin positivity, the authors verified that the latter factor was the only variable that affected the results in relation to patient survival, as it was related to a higher local tumor recurrence rate.

Some studies have shown that approximately half of the osteosarcoma cases occurring in the maxilla correspond to the chondroblastic subtype and the presence of neoplastic tissue with a cartilaginous aspect increases the possibility of the tumor presenting a high degree of malignancy, being considered a negative prognosis factor (Demiccio et al., 2010; Paparella et al., 2013; Krishnamurthy & Palaniappan, 2018). Characteristics reported in the literature, such as osteoid deposition, material presenting a chondroid appearance, intense cellularity and high atypia degree were evidenced in the histopathological examination of the patient presented herein, and these alterations could be related to the greater aggressiveness of this tumor.

5. Conclusion

Osteosarcoma of the maxillary bones consists of a malignant neoplasm in proximity to noble structures. Its diagnosis should be performed based on a clinical, imaging and histopathological evaluations. Surgical tumor removal is the treatment of choice, but this therapeutic approach is not always possible and, in this type of situation, neoadjuvant chemotherapy may be a treatment option, creating subsidies for surgical tumor removal by reducing its size. However, early diagnosis and the degree of tumor malignancy are extremely important for successful treatment.

References

Chen, Y., Gokavarapu, S., Shen, Q., Liu, F., Cao, W., Ling, Y., & Ji, T. (2017). Chemotherapy in head and neck osteosarcoma: Adjuvant chemotherapy improves overall survival. *Oral oncology*, 73, 124-131.

Crowe, S., Cresswell, K., Robertson, A., Huby, G., Avery, A., & Sheikh, A. (2011). The case study approach. *BMC medical research methodology*, 11(1), 100.

de Arruda, J. A. A., de Oliveira Silva, L. V., de Oliveira, C. D. N. A., Schuch, L. F., Batista, A. C., Costa, N. L., & Sobral, A. P. V. (2017). A multicenter study of malignant oral and maxillofacial lesions in children and adolescents. *Oral Oncology*, 75, 39-45.

DeAngelis, A. F., Spinou, C., Tsui, A., Iseli, T., Desai, J., Wiesenfeld, D., & Chandu, A. (2012). Outcomes of patients with maxillofacial osteosarcoma: a review of 15 cases. *Journal of oral and maxillofacial surgery*, 70(3), 734-739.

de Carvalho, W. R. S., de Souza, L. L., Pontes, F. S. C., Uchôa, D. C. C., Corrêa, D. L., et al. (2020). A multicenter study of oral sarcomas in Brazil. *Oral diseases*, 26(1), 43-52.

Demicco, E. G., Deshpande, V., Nielsen, G. P., Kattapuram, S. V., & Rosenberg, A. E. (2010). Well-differentiated osteosarcoma of the jaw bones: a clinicopathologic study of 15 cases. *The American journal of surgical pathology*, 34(11), 1647-1655.

Jeong, H. I., Lee, M. J., Nam, W., Cha, I. H., & Kim, H. J. (2017). Osteosarcoma of the jaws in Koreans: analysis of 26 cases. *Journal of the Korean Association of Oral and Maxillofacial Surgeons*, 43(5), 312-317.

Kimura, Y., Tomihara, K., Tachinami, H., Imaue, S., Nakamori, K., Fujiwara, K., & Noguchi, M. (2017). Conventional osteosarcoma of the mandible successfully treated with radical surgery and adjuvant chemotherapy after responding poorly to neoadjuvant chemotherapy: a case report. *Journal of Medical Case Reports*, 11(1), 1-6.

Krishnamurthy, A., & Palaniappan, R. (2018). Osteosarcomas of the head and neck region: a case series with a review of literature. *Journal of maxillofacial and oral surgery*, 17(1), 38-43.

Laskar, S., Basu, A., Muckaden, M. A., D'Cruz, A., Pai, S., Jambhekar, N., & Shrivastava, S. K. (2008). Osteosarcoma of the head and neck region: lessons learned from a single-institution experience of 50 patients. *Head & Neck: Journal for the Sciences and Specialties of the Head and Neck*, 30(8), 1020-1026.

Liang, L., Zhang, T., You, Y., He, Q., Fan, Y., & Liao, G. (2019). An individual patient data meta-analysis on the effect of chemotherapy on survival in patients with craniofacial osteosarcoma. *Head & neck*, 41(6), 2016-2023.

Nissanka, E. H., Amaratunge, E. A. P. D., & Tilakaratne, W. M. (2007). Clinicopathological analysis of osteosarcoma of jaw bones. *Oral diseases*, 13(1), 82-87.

Paparella, M. L., Olvi, L. G., Brandizzi, D., Keszler, A., Santini-Araujo, E., & Cabrini, R. L. (2013). Osteosarcoma of the jaw: an analysis of a series of 74 cases. *Histopathology*, 63(4), 551-557.

Thariat, J., Schouman, T., Brouchet, A., Sarini, J., Miller, R. C., Reychler, H., & Bompas, E. (2013). Osteosarcomas of the mandible: multidisciplinary management of a rare tumor of the young adult a cooperative study of the GSF-GETO, Rare Cancer Network, GETTEC/REFCOR and SFCE. *Annals of oncology*, 24(3), 824-831.

Yamamoto-Silva, F. P., Silva, B. S. D. F., Batista, A. C., Mendonça, E. F. D., Pinto-Junior, D. D. S., & Estrela, C. (2017). Chondroblastic osteosarcoma mimicking periapical abscess. *Journal of Applied Oral Science*, 25(4), 455-461.

Yildiz, F. R., Avci, A., Dereci, O., Erol, B., Celasun, B., & Gunhan, O. (2014). Gnathic osteosarcomas, experience of four institutions from Turkey. *International Journal of Clinical and Experimental Pathology*, 7(6), 2800.

Percentage of contribution of each author in the manuscript

Rani Iani Costa Gonçalo – 30%

Cristianne Kalinne Santos Medeiros – 20%

Humberto Pereira Chaves Neto – 15%

Janaina Lessa de Moraes dos Santos – 15%

Adriano Rocha Germano – 10%

Lélia Maria Guedes Queiroz – 10%