

Performance of methods for detecting occlusal caries lesions: ICDAS X radiological image

Desempenho de métodos para detecção de cárie oclusal: ICDAS vs. imagem radiológica

Métodos de desempeño para detección de caries oclusales: ICDAS vs. imagen radiológica

Received: 09/15/2020 | Reviewed: 09/16/2020 | Accept: 09/20/2020 | Published: 09/22/2020

Tânia Cristina Simões

ORCID: <https://orcid.org/0000-0002-9918-8685>

Instituto Federal de Educação, Ciência e Tecnologia do Paraná, Brasil

E-mail: tania.simoed@ifpr.edu.br

Leonardo Carmezini Marques

ORCID: <https://orcid.org/0000-0003-3772-0856>

Instituto Federal de Educação, Ciência e Tecnologia do Paraná, Brasil

E-mail: leonardo.carmezini@ifpr.edu.br

André Tomazini Gomes de Sá

ORCID: <https://orcid.org/0000-0001-9634-8543>

Instituto Federal de Educação, Ciência e Tecnologia do Paraná, Brasil

E-mail: andre.sa@ifpr.edu.br

Sandra Mara Maciel

ORCID: <https://orcid.org/0000-0002-0508-6240>

Universidade Norte do Paraná, Brasil

E-mail: sandramaciel53@gmail.com

Marcelo Lupion Poleti

ORCID: <https://orcid.org/0000-0003-1904-5762>

Instituto Federal de Educação, Ciência e Tecnologia do Paraná, Brasil

E-mail: marcelo_poleti@yahoo.com.br

Fabíola Stahlke Prado

ORCID: <https://orcid.org/0000-0002-1594-2426>

Universidade Norte do Paraná, Brasil

E-mail: fabiola_stahlkeprado@hotmail.com

Alejandra Hortênciã Miranda González

ORCID: <https://orcid.org/0000-0003-2982-8736>

Universidade Norte do Paraná, Brasil

E-mail: alejandra.horten@anhanguera.com

Izabel Regina Fischer Rubira-Bullen

ORCID: <https://orcid.org/0000-0002-5069-9433>

Universidade de São Paulo, Brasil

E-mail: izrubira2000@yahoo.com.br

Sandra Kalil Bussadori

ORCID: <https://orcid.org/0000-0002-9853-1138>

Universidade Nove de Julho, Brasil

E-mail: sandra.skb@gmail.com

Sandra Kiss Moura

ORCID: <https://orcid.org/0000-0002-1530-65500>

Universidade Nove de Julho, Brasil

E-mail: kissmoura@gmail.com

Abstract

Objective: We investigated the precision and accuracy of methods to detect caries lesions on the occlusal surface in vitro using ICDAS and radiological image. **Methodology:** Human third molars (n=14) were placed in an acrylic resin base and maintained wet during the study. The occlusal surfaces were visually inspected by three examiners using the International Caries Detection and Assessment System (ICDAS) method. The condition of each tooth was registered by images obtained with Digital Radiography (DR), Microcomputed Tomography (μ -CT) and Histologic Specimen (HS). For each tooth and method utilized in the study, an image was selected based on the largest extension of caries found, wherein the three examiners attributed a score to the lesion in accordance with the visual description of each method. The Kappa index, Fisher's exact test and the Spearman's correlation coefficient were used for evaluating reliability and accuracy, with a significance level of 5%. **Results:** Considerable interobserver reliability values were found for ICDAS (k = 0.701), almost perfect for μ -CT (k = 0.855) and HS (k = 0.920), and reasonable for DR (k = 0.221). Significant statistical difference was observed for ICDAS (p < 0.05), and for DR and μ -CT methods (p < 0.01). The correlation was moderate for ICDAS (r = 0.597), high for DR (r = 0.764) and perfect for μ -CT (1.000). **Conclusions:** the most reliability method for detecting caries lesions on occlusal surfaces in vitro was μ -CT, followed by ICDAS and DR. The most accurate method was μ -CT, followed by DR and ICDAS.

Keywords: Dental caries; Efficiency; X-Rays; Diagnosis.

Resumo

Objetivo: Investigou-se a precisão e acurácia dos métodos para detectar lesões de cárie na superfície oclusal in vitro, usando ICDAS e imagem radiológica. **Metodologia:** Terceiros molares humanos (n = 14) foram colocados em uma base de resina acrílica e mantidos úmidos durante o estudo. As superfícies oclusais foram inspecionadas visualmente por três examinadores pelo método ICDAS. A condição de cada dente foi registrada por imagens obtidas com Radiografia Digital (RD), Microtomografia Computadorizada (μ -CT) e Corte Histológico (CH). Para cada dente e método utilizado no estudo, foi selecionada uma imagem com base na maior extensão de cárie encontrada, em que os três examinadores atribuíram uma pontuação à lesão de acordo com a descrição visual de cada método. O índice Kappa, o teste exato de Fisher e o coeficiente de correlação de Spearman foram usados para avaliação da precisão e acurácia, com nível de significância de 5%. **Resultados:** Consideráveis valores de precisão interobservador foram encontrados para ICDAS (k = 0,701), quase perfeitos para μ -CT (k = 0,855) e CH (k = 0,920), e razoáveis para RD (k = 0,221). Diferença estatística significativa foi observada para ICDAS (p <0,05), e para os métodos RD e μ -CT (p <0,01). A correlação foi moderada para ICDAS (r = 0,597), alta para RD (r = 0,764) e perfeita para μ -CT (1,000). **Conclusão:** o método mais preciso para detectar lesões de cárie em superfícies oclusais in vitro foi o μ -CT, seguido pelo ICDAS e RD. O método mais acurado foi o μ -CT, seguido pelo RD e ICDAS.

Palavras-chave: Cárie dentária; Eficiência; Raios X; Diagnóstico.

Resumen

Objetivo: La precisión y exactitud de métodos para detectar lesiones de caries en superficie oclusal in vitro, utilizando ICDAS y imágenes radiológicas fue investigada. **Metodología:** Terceros molares humanos (n = 14) se colocaron sobre una base de resina acrílica y se mantuvieron húmedos durante el estudio. Las superficies oclusales fueron inspeccionadas visualmente por tres examinadores utilizando el método ICDAS. El estado de cada diente se registró mediante imágenes obtenidas con Radiografía Digital (RD), Microtomografía Computarizada (μ -CT) y Corte Histológico (CH). Para cada diente y método utilizado se seleccionó una imagen basada en la mayor extensión de caries encontrada, en que los tres examinadores asignaron una puntuación a la lesión de acuerdo con la descripción visual de cada método. Para evaluar la precisión y exactitud se utilizaron el índice Kappa, prueba exacta de Fisher y coeficiente de correlación de Spearman, con un nivel de significancia del 5%. **Resultados:** Se encontraron valores de precisión interobservador considerables para ICDAS (k

= 0,701), casi perfectos para μ -CT ($k = 0,855$) y CH ($k = 0,920$), y razonables para RD ($k = 0,221$). Se observó una diferencia estadística significativa para ICDAS ($p < 0,05$) y para los métodos RD y μ -CT ($p < 0,01$). La correlación fue moderada para ICDAS ($r = 0,597$), alta para RD ($r = 0,764$) y perfecta para μ -CT (1,000). Conclusión: el método más preciso para detectar lesiones de caries en superficies oclusales *in vitro* fue μ -CT, seguido de ICDAS y RD. El método más exacto fue μ -CT, seguido de RD y ICDAS.

Palabras clave: Caries dental; Eficiencia; Rayos X; Diagnóstico.

1. Introduction

The diagnosis of caries lesions on the occlusal surfaces of human teeth is commonly done by conventional methods—visual inspection and tactile exam—by which the dentist detects the presence of the disease with the unaided eye or in association with a blunt-tip dental explorer (Ismail, 2004). When associated with other techniques, the precision of these methods can be improved (Ko et al., 2012). Complementary methods for detecting caries lesions are currently available, such as the ICDAS and radiological technologies.

The efficacy of visual inspection methods, such as the International Caries Detection and Assessment System (ICDAS), for the early diagnosis of caries lesions can be observed in the literature (Pitts & Ekstrand, 2013; Ekstrand et al., 2007; Ekstrand et al., 2018). Developed in 2002, the ICDAS is the most recent effort by researchers to create a tool for diagnosing caries through scientifically based evidences about systems of clinical detection of caries (Banting et al., 2012). It is a clinical method for visual inspection that describes a standard for measuring a caries lesion, detecting it in different degrees of severity, and assessing its extension in a systematic manner—both on an individual and collective level—and classifying it (Braga et al., 2009; Zandoná & Zero, 2006). Moreover, this system improves diagnosis (Ekstrand et al., 2018), treatment and prognosis, contributing to the ability of dentists to accompany the evolution of a patient's general oral health as well as assisting them with the oral health education of the patient (Brocklehurst et al., 2012).

The histologic test is frequently used as the gold standard for validating the detection of caries *in vitro* (Mitropoulos et al., 2012; Park et al., 2011; Hintze & Wenzel, 2006); however, it makes long-term study impossible because it destroys the sample. By comparison, radiographic technology has contributed to investigations that evaluate the ICDAS method by measuring the physical alterations that have occurred due to caries on the mineralized portion of the tooth (Zou et al., 2011). Interproximal digital radiography is the complementary method

adopted by dentists for supporting conventional methods of detecting the caries lesion. It presents good sensitivity and high specificity in cavitated lesions (Neuhaus et al., 2011). It is effective for interproximal caries, but ineffective for the detection of occlusal caries lesions located in enamel. This is due to the quantity of healthy tissue that inhibits the X-ray beams (Rechmann et al., 2012). The radiographic measure is an estimate of the continual mineral loss and does not detect certain stages of the lesion or its activity, except in situations in which it's possible to compare sequential radiographic images of the same caries lesion for a period of time (Young et al., 2015).

The μ -CT has been suggested as an approach to investigating *in vitro* alterations in mineralized samples of small dimensions. Analyses of dynamic processes—such as caries lesions—are possible because the technique permits non-destructive tridimensional analysis with high spatial resolution image quality, achieving up to 1 micrometer (μm) (Marques & Appoloni, 2015; Davis et al., 2013). It also permits the detection of caries lesions in the initial stage, at which point it is imperceptible with the unaided eye because it is sensitive to the concentration of the sample's minerals (Elfrink et al., 2013). It is a method of inspection that provides detailed transverse images of the internal region of the analyzed minerals (Özkan et al., 2015; Soviero et al., 2012). Such images enable the reconstruction of a succession of X-rays, also called projections, of a given volume of the sample. Each projection is a mapping of the linear attenuation coefficient of the region where the X-ray beam is transmitted (Marques & Appoloni, 2015).

Despite the complementary methods for detecting caries lesions are currently available, studies demonstrating the outcomes of the comparison between ICDAS and radiological imaging *in vitro* are scarce. Thus, this study was conducted to assess the reliability and accuracy of methods of detecting caries lesions on occlusal surfaces *in vitro* using ICDAS, digital radiography and μ -CT.

2. Methodology

This research is characterized by an experimental study, quantitative, exploratory, and descriptive study, in which the search strategy was the international system for the detection and evaluation of caries injuries (ICDAS), carried out in several databases available at the time.

After receiving approval for the project from the Ethics in Research Committee (N° 811.736), 14 human third molars—extracted for therapeutic reasons—and affected by the caries

disease at different levels and without sealant or restorative treatments, were included in the sample.

The teeth were disinfected for 7 days in a solution of chloramine-T (Vetec Química Fina Ltda.; Rio de Janeiro, Rio de Janeiro, Brazil) and 0.5% water at 4°C; cleaned—removing debris and soft tissue—by radicular scraping using periodontal curettes (Mcall; Hu-Fiedy Mfg. Co., LLC; Chicago, USA) and polished with pumice paste in association with a Robson brush attached to a Koncept slow-speed drill (KaVo of Brazil Ind. Com. Ltda., Joinville, Santa Catarina, Brazil). The clean teeth were stored in a glass jar containing ultrapure water to avoid dehydration (Elga; PurelabOption-Q DV25; São Paulo, Brazil), and later placed in an acrylic resin base and randomly coded from I to XIV.

ICDAS

Three examiners were calibrated to the criteria of the ICDAS visual inspection method. The training occurred in one single step using the electronic system (www.icdas.org), which provides an educational software package—an e-learning program (Topping et al., 2008). Immediately after the training, the teeth were cleaned by prophylaxis with pumice stone and water for 60 seconds (s), rinsed and dried for 5s with a triple syringe and placed on individual workbenches so that the occlusal surfaces of each tooth could be visually and independently inspected by the examiners. In cases of disagreement over the score number, the criterion of consensus was adopted. The ICDAS control group for evaluation was established this way.

The occlusal surface of each tooth was photographed at a 1:1 proportion for the purpose of registering the effect of caries on the 14 teeth assessed by the ICDAS. A digital camera (EOS Rebel T1i; Canon Inc.; Tokyo; Japan) equipped with a EF100mm f/2.8 Macro USM and a circular MR-14EX flash, all of the Canon brand, was used. The focal distance, the aperture and light sensitivity were, respectively: 100mm; f16; ISO 100. The images were adjusted—in relation to their size and exposure—and processed as a batch with the digital camera's processing, visualization and image editing software from Digital Photo Professional (Canon; Canon Inc., Tokyo; Japan).

DIGITAL RADIOGRAPHY (DR)

The radiographic image of the coronal portion of each tooth was obtained with a size 2 phosphorus plate digitizer—3X4 centimeters (cm), from the VistaScan Plus digital radiography system (Dürr Dental of Brazil; Porto Alegre; Rio Grande do Sul; Brazil), with an X-ray exposure time of 0.2s. The system was connected to the analogic X-ray equipment by Heliodente^{Plus} (Sirona Brasil; São Paulo, São Paulo, Brazil) with a voltage of 70kV and a current

of 7 milliamperes (mA), which was used to employ a technique similar to intraoral-interproximal radiography. The images were processed with a real resolution of 22 lines pairs per millimeter (lp/mm) using the digital radiography system's DBSWIN software (Dürr Dental of Brazil; Porto Alegre; Rio Grande do Sul; Brazil).

MICROCOMPUTED TOMOGRAPHY (μ -CT)

The specimens were scanned by the microtomograph (SkyScan 1172; Kontich; Bruker; Belgium) using a voltage of 100 kilovolts (kV), an electric current of 100 microamperes (μ A) applied to the X-ray tube, which had an aperture of 5 μ m. The pixel size of 8.99 μ m was used for a CCD camera of 11 megapixels (Mpixel). The thickness of the aluminum filter was 0.5 mm. All the samples were scanned in rotation steps of 0.3° for a total of 360°. Each projection was the result of an average of 4 projections in the same angular position of the sample. The average scanning time for each tooth was 172 minutes (min). The angular reconstruction of the images was conducted by the reconstruction program (NRecon version 1.6.4.7; Kontich; Bruker; Belgium). The reconstruction resulted in transversal images to the volume scanned. The visualization and analysis software (CTAn Kontich; Bruker; Belgium) was used to obtain vertical layers based on transversal images.

HISTOLOGIC SPECIMEN (HS)

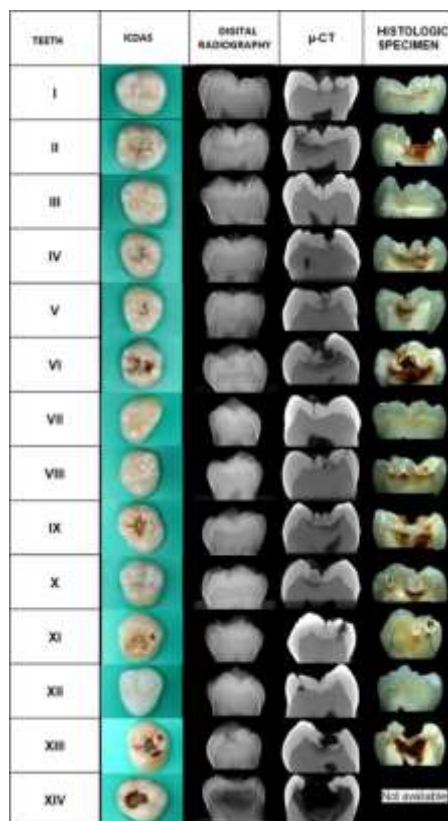
Each tooth was sectioned longitudinally in the mesio-distal direction em 5 equidistant sections of 1mm in thickness, passing through the central fissure of the occlusal surface; with the aid of an Extec 12205 diamond cutting disc (Erios, São Paulo, São Paulo, Brazil) attached to a ISOMET 1000 model cutting machine (Buhler Ltd., Lake Bluff, IL, USA), at a speed of 200 rotations per minute (rpm) under constant refrigeration with distilled water. Next, the coronal portions were separated from the roots by making another cut perpendicular to the long axis of the tooth, at the height of the cemento-enamel junction. The 4 sections obtained from each sample were individually stored in capped receptacles containing 2 ml of ultra-pure water.

The tooth sections were analyzed with Bel Photonics stereoscopic optics (Bel Microimager Analyser, Monza, Italy), with a 40 X amplification of the original and using a Microscope Eyepiece Camera 3.1 MP (ToupTek Photonics Co., Ltd; Hanzhou; Zhejiang, China), attached to the stereoscope. Each section was photographed and assessed using digital images enlarged with the software (ToupView Photonics Co., Ltd; Hangzhou; Zhejiang, China) and displayed on a computer monitor.

IMAGE PROCESSING

For each assessed tooth, independently of the method used, images were obtained that were adjusted in relation to the size and exposure, and processed as a batch with the processing, visualization and image editing software Digital Photo Professional (Canon; Canon Inc., Tokyo; Japan) which was provided with the digital camera. In Figure 1, images of each tooth are represented, being selected according to the greatest degree to which caries affected each tooth. This was determined by the deepest extension of color alteration and demineralization of the sample, as compared with healthy tissue.

Figure 1. Images representative of each method used in the study (n = 14).



Source: Authors.

SCORES

The images obtained from each method for each assessed tooth were analyzed independently by the three examiners of the ICDAS method using a HP Pavilion Ultrabook computer (Hewlett-Packard Brasil Ltda.; São Paulo; São Paulo; Brazil), with a 14-inch screen. For each assessed image, a score was attributed in accordance with the description in Table 1.

Table 1. Visual description attributed to the scores of the methods used in the study.

ICDAS	SCORE	DIGITAL RADIOGRAPHY / μ – CT	SCORE	HISTOLOGIC SPECIMEN	SCORE
Dental intact surface	0	No radiolucent image visible	0	No Demineralization	0
Visible initial change in restricted enamel-based pit and fissure	1	Radiolucent image visible in enamel	1	Demineralization involving 50% of the external surface of the enamel	1
Clearly visible change in enamel as white spot lesions or brown	2				
Discontinuity of the enamel surface (microcavitation) without visible dentine	3	Radiolucent image visible in dentine, restricted to the outer third	2	Demineralization involving from 50% of the inner surface of the outer enamel and 1/3 dentin	2
Shading of the underlying dentin or not cavitated enamel, dentin visible	4				
Cavity involving less than 50% of the enamel surface with visible dentine	5	Radiolucent image extending to the middle third of the dentine	3	Demineralization of the middle third of the dentine	3
Cavity involving more than 50% of	6	Radiolucent image reaching	4	Demineralization involving the	4

the enamel surface with visible dentine	the inner third of the dentine	inner third of the dentine
--	-----------------------------------	-------------------------------

Source: Authors

The scores were recodified in accordance with the presence of caries and without caries = 0 (ICDAS, DR, μ -CT, and Histologic Specimen = 0) and with caries = 1 (ICDAS ≥ 1 and ≤ 6 and DR, μ -CT and Histologic Specimen ≥ 1 and ≤ 4) and in accordance with the localization of the caries and without caries = 0 (ICDAS, DR, μ -CT and Histologic Specimen = 0); with caries in enamel = 1 (ICDAS ≥ 1 and ≤ 3 and DR, μ -CT and Histologic Specimen = 1) and with caries in dentin = 2 (ICDAS ≥ 4 and ≤ 6 and DR, μ -CT and Histologic Specimen ≥ 2 and ≤ 4) (Al-Khatrash et al., 2011). In cases of disagreement among the examiners about the number of the score, the criterion of consensus was adopted to determine the score of the tooth for each method. The histologic specimen method was adopted as the gold standard.

STATISTICAL ANALYSIS

The ordinal categorical data were compiled with Microsoft Office Excel 2010 and transferred to the program *Statistical Package for Social Sciences (SPSS)*, version 20.0. In order to express the reliability of the methods tested in this study, the Kappa Index (k) was used. In order to test possible associations and correlations between the methods, Qui-Quadrado Tests, Fisher's exact test and Spearman's coefficient correlation (p) were used. The significance level was set at 5%.

3. Results

Table 2 shows the interobserver reproducibility for ICDAS (k = 0.701), DR (k = 0.221), μ -CT (k = 0.855) and Histologic Specimen (k = 0.920).

Table 2. Kappa Index of the examiner assessments of diagnostic methods for caries lesions in vitro.

DIAGNOSTIC METHODS	SCORES						
	0	1	2	3	4	5	6
ICDAS							
Kappa score	1.0		0.546	0.65	0.546	0.717	0.475
p Kappa value	< 0.001		< 0.001	< 0.001	< 0.001	< 0.001	0.002
<i>Kappa Overall</i>				0.701			
<i>Overall p value</i>				< 0.001			
DIGITAL RADIOGRAPHY							
Kappa score	0.319	0.01	0.274	0.143	0.417		
p Kappa value	0.039	0.948	0.076	0.355	0.007		
<i>Kappa Overall</i>				0.221			
<i>Overall p value</i>				0.007			
μ - CT							
Kappa score	1.0		0.808	0.786	1.0		
p Kappa value	< 0.001		< 0.001	< 0.001	< 0.001		
<i>Kappa Overall</i>				0.855			
<i>Overall p value</i>				< 0.001			
HISTOLOGIC SPECIMEN							
Kappa score	1.0		1.0	- 0.024	0.904		
p Kappa value	< 0.001		< 0.001		< 0.001		
<i>Kappa Overall</i>				0.92			
<i>Overall p value</i>				< 0.001			

Source: Authors

Significant statistical differences were observed upon comparing the diagnosis of caries between the histologic specimen method (gold standard) and the other methods (Table 3). Greater difference was found using ICDAS, followed by DR. ICDAS underestimated the diagnosis of seven teeth with carie in dentin and DR underestimated two teeth when compared to the gold standard.

Table 3. Comparison between the histologic specimen (gold standard) and the methods for detecting caries according to local lesion.

DIAGNOSTIC METHODS	WITHOUT CARIES N (%)	WITH CARIES		p [†]
		ENAMEL	DENTIN	
		N (%)	N (%)	
HISTOLOGIC SPECIMEN*	2 (14.3)	0 (0.0)	12 (85.7)	
ICDAS	3 (21.4)	6 (42.9)	5 (35.7)	0.023
DIGITAL RADIOGRAPHY	2 (14.3)	2 (14.3)	10 (71.4)	0.001
μ-CT	2 (14.3)	0 (0.0)	12 (85.7)	0.011

† Fisher's Exact Test p<0.05

*Gold standard

Source: Authors

The methods of detecting caries lesions on occlusal surfaces correlated with the HS (Table 4). Significant statistical difference was observed for ICDAS ($p < 0.05$), and for DR and μ-CT methods ($p < 0.01$). The correlation was moderate for ICDAS ($r = 0.597$), high for DR ($r = 0.764$) and perfect for μ-CT (1.000).

Table 4. Correlation between the histologic specimen (gold standard) and the methods for detecting caries.

DIAGNOSTIC METHODS	ICDAS	DIGITAL RADIOGRAPHY	μ-CT
HISTOLOGIC SPECIMEN	0.597*	0.764**	1.000**

* Significant correlation $p < 0.05$.

** Significant correlation $p < 0.01$.

Source: Authors

4. Discussion

The ICDAS is among the alternatives to the visual and tactile methods of inspection recommended by the World Health Organization because of its high level of reproducibility and accuracy for assessing primary coronal caries lesions (Ekstrand et al., 2018). This method was studied in this research with the purpose of comparing it to the methods based on X-rays and to the histologic specimen method (gold standard) so as to assess its performance in detecting caries lesions on the occlusal surfaces of third molars.

In this study, the interobserver reproducibility on the ICDAS method was considerable (0.701). The results concurred with those found by Rodrigues et al. (2013) in which sixteen post-graduate students assessed the occlusal surfaces of 67 exfoliated deciduous teeth after only one training on a mannequin.

When correlated to the histologic specimen method and μ -CT, the visual inspection system ICDAS was moderate because a large number of teeth was classified with caries in only the enamel, being that the caries process had already affected dentin in accordance with the gold standard (Table 3). This could have occurred due to the visual limitation of the method, principally for score 3 where the enamel showed microcavitation, although without visualization of the dentin. In this approach, it is difficult to precisely assess the degree of the lesion's damage when no stains have occurred on the assessed surface. In Figure 1, it is possible to visualize the degree to which caries lesions have affected the teeth with all the methods tested in this study. This confirms the difficulty of indentifying the actual extension of the lesion without a supplemental exam (Jablonski-Momeni et al. 2008).

The results show that the methods that are more easily interpreted produced the best outcomes. This was the case with the μ -CT method, which after the statistical analyses showed a similar precision and a perfect correlation with the histologic specimen method. However, this method implies a high dose of radiation and requires extensive time for digitalization, reconstruction and processing of the images, making the cost-benefit relationship prohibitive (Özkan, et al., 2015).

In our study, the tridimensional data obtained with the μ -CT method showed more information about the condition of the occlusal tissue than digital radiography using the phosphorus plate method, which presented images with superimposition of structures on the occlusal surface, thus making diagnosis of caries in enamel more difficult (Krzyżostaniak et al., 2014).

Mineral density also has been considered as a parameter for the determination of demineralization and of remineralization in dental caries. This is because it offers insight into the dynamic alterations associated with the tridimensional spatial distribution of the mineral in caries lesions (Zou et al., 2011). In this study, the μ -CT method provided tridimensional images of the assessed teeth, which made it possible to generate precise assessment of the caries lesion within a tooth without needing to destroy the sample. Thus, the method permits reassessment of a sample when necessary in order to detect episodes of demineralization or remineralization in natural caries lesions (Zou et al., 2011). However, the longitudinal studies with repeated measures of samples with more than one series of demineralization or remineralization episodes

are not practical because of the limited availability of equipment and the operational costs. The variation in and the uncertainty of determining the composition of the enamel, be it healthy or decayed, limits the precision with which mineral concentrations of the enamel can be established based on reference values (Zou et al., 2011). It is difficult, however, to simulate a standard of mineral composition of the enamel and dentin structures since the quantification of minerals varies between individuals (Soviero et al., 2012).

In this study, the histologic section that was adopted as the reference for assessment was the section that was most visually affected by the caries lesion. Having obtained the histologic specimens in intervals of 1 mm, it was difficult to isolate a lesion that most represented the severity of the disease. This was due to the tridimensional nature of caries propagation as determined by the complex anatomy of occlusal surface. A lesion could originate in the same location on the surface of the tooth, but spread obliquely and asymmetrically below the surface of the enamel (Jablonski-Momeni et al., 2008). This makes diagnosis of a lesion's extension even more complex, and at the same time emphasizes the importance of using supplemental exams to diagnose the disease.

It is important to emphasize the difficulty the dentist encounters when detecting initial stage caries lesions, especially when they occur in the enamel of the occlusal surface. The methods commonly adopted for this purpose depend on visual acuity and are limited by subjectivity. Therefore, to associate these methods with the radiographic technology could improve the precision of detecting this type of lesion by means of quantifying the degree of mineral loss in the structure of the enamel, thus guaranteeing that the dentist adopts the appropriate intervention.

5. Conclusions

In summary, from the methods used during this research, the most reliability method for detecting caries lesions on occlusal surfaces in vitro was μ -CT, followed by ICDAS and DR. The most accurate method was μ -CT, followed by DR and ICDAS.

It is necessary to carry out clinical research with longitudinal monitoring, to evaluate the treatment of caries lesions according to the criteria of the ICDAS method, since the scientific evidence of the diagnostic method is confirmed by numerous studies.

Acknowledgements

To CAPES for the granting of a scholarship for Stricto Sensu Graduate Studies. To the State University of Londrina for the measurements made in the microtomograph of the Laboratory of Analysis by X-rays (LARX). To the University of Northern Paraná, for supporting the development of this research. In particular, for the collaboration of the graduate student in Dentistry, Maynara Gongora Rubim, in the data collection and tabulation phase of this study.

References

- Al-Khatrash, A. A., Badran, Y. M., & Alomari, Q. D. (2011). Factors affecting the detection and treatment of occlusal caries using the International Caries Detection and Assessment System. *Operative Dentistry*, 36(6), 597-607.
- Banting, D., Deery, C., Eggertsson, H., Ekstrand, K. R., Zandoná, A. F., Ismail, A. I., Longbottom, C., Martignon, S., Pitts, N. B., Reich, E., Ricketts, D., Selwitz, R., Sohn, W., Douglas, G. V. A., & Zero, D. T. (2012). Rationale and evidence for the international caries detection and assessment system (ICDAS II). Retrieved from <https://www.iccms-web.com/uploads/asset/592848be55d87564970232.pdf>.
- Braga, M. M., Oliveira, L. B., Bonini, G. V. C., Bönecker, M., & Mendes, F. M. (2009). Feasibility of the International Caries Detection and Assessment System (ICDAS-II) in epidemiological surveys and comparability with standard World Health Organization criteria. *Caries Research*, 43(4), 245-9.
- Brocklehurst, P., Ashley, J., Walsh, T., & Tickle, M. (2012). Relative performance of different dental professional groups in screening for occlusal caries. *Community Dentistry and Oral Epidemiology*, 40(3), 239-246.
- Davis, G. R., Evershed, A. N. Z., & Mills, D. (2013). Quantitative high contrast X-ray microtomography for dental research. *Journal of Dentistry*, 41(5), 475-82.

Ekstrand, K. R., Martignon, S., Ricketts, D. J., & Qvist, V. (2007). Detection and activity assessment of primary coronal caries lesions: a methodologic study. *Operative Dentistry*, 32(3), 225-35.

Ekstrand, K. R., Gimenez, T., Ferreira, F. R., Mendes, F. M., & Braga, M M. (2018). The International Caries Detection and Assessment System–ICDAS: A Systematic Review. *Caries Research*, 52(5), 406-419.

Elfrink, M. E. C., Ten Cate, J. M., Van Ruijven, L. J., & Veerkamp, J. S. J. (2013). Mineral content in teeth with deciduous molar hypomineralisation (DMH). *Journal of Dentistry*, 41(11), 974-8.

Hintze, H., & Wenzel, A. (2003). Diagnostic outcome of methods frequently used for caries validation: A comparison of clinical examination, radiography and histology following hemisectioning and serial tooth sectioning. *Caries Research*, 37(2), 115-24.

Ismail, A. I. (2004). Visual and visuo-tactile detection of dental caries. *Journal of Dental Research*, 83(Spec No C), 56-66.

Jablonski-Momeni, A., Stachniss, V., Ricketts, D. N., Heinzl-Gutenbrunner, M., & Pieper, K. (2008). Reproducibility and accuracy of the ICDAS-II for detection of occlusal caries in vitro. *Caries Research*, 42(2), 79-87.

Ko, H. Y., Kang, S. M., Kim, H. E., Kwon, H. K., & Kim, B. I. (2015). Validation of quantitative light-induced fluorescence-digital (QLF-D) for the detection of approximal caries in vitro. *Journal of Dentistry*, 43(5), 568-575.

Marques, L. C., & Appoloni, C. R. (2015). Quantification of fluids injection in a glass-bead matrix using X-ray microtomography. *Micron*, 74, 35-43.

Mitropoulos, P., Rahiotis, C., Kakaboura, A., & Vougiouklakis, G. (2012). The impact of magnification on occlusal caries diagnosis with implementation of the ICDAS II criteria. *Caries Research*, 46(1), 82-86.

Neuhaus, K. W., Rodrigues, J. A., Hug, I., Stich, H., & Lussi, A. (2011). Performance of laser fluorescence devices, visual and radiographic examination for the detection of occlusal caries in primary molars. *Clinical Oral Investigations*, 15(5), 635-641.

- Özkan, G., Kanli, A., Başeren, N. M., Arslan, U., & Tatar, I. (2015). Validation of micro-computed tomography for occlusal caries detection: an in vitro study. *Brazilian Oral Research*, 29(1), 1-7.
- Park, Y. S., Ahn, J. S., Kwon, H. B., & Lee, S. P. (2011). Current status of dental caries diagnosis using cone beam computed tomography. *Imaging Science in Dentistry*, 41(2), 43-51.
- Pereira, A. S., Shitsuka, D. M., Parreira, F. J., & Shitsuka, R. (2018). *Metodologia da pesquisa científica.[e-book]*. Santa Maria. Ed. UAB/NTE/UFSM. Retrieved from https://repositorio.ufsm.br/bitstream/handle/1/15824/Lic_Computacao_Metodologia-Pesquisa-Cientifica.pdf. https://repositorio.ufsm.br/bitstream/handle/1/15824/Lic_Computacao_Metodologia-Pesquisa-Cientifica.pdf?sequence=1
- Pitts, N. B., & Ekstrand, K. R. (2013). International Caries Detection and Assessment System (ICDAS) and its International Caries Classification and Management System (ICCMS) – methods for staging of the caries process and enabling dentists to manage caries. *Community Dent Oral Epidemiol*, 41, e41–e52.
- Rechmann, P., Charland, D., Rechmann, B. M. T., & Featherstone J. D. B. (2012). Performance of laser fluorescence devices and visual examination for the detection of occlusal caries in permanent molars. *Journal of Biomedical Optics*, 17 (3), 0360061-5.
- Rodrigues, J. A., De Oliveira, R. S., Hug, I., Neuhaus, K., & Lussi, A. (2013). Performance of Experienced Dentists in Switzerland After an E-Learning Program on ICDAS Occlusal Caries Detection. *Journal of Dental Education*, 77, 1086-1091.
- Soviero, V. M., Leal, S. C., Silva, R. C., & Azevedo, R. B. (2012). Validity of MicroCT for in vitro detection of proximal carious lesions in primary molars. *Journal of Dentistry*, 40 (1), 35-40.
- Topping, G. A., Hally J. D., Bonner B., & Pitts N. B. (2008). International Caries Detection and Assessment System (ICDAS) E-Learning Program. Package: interactive CD-ROM and Web-based software. *Smile-On*, London.
- Young, D. A., Nový, B. B., Zeller, G. G., & Hale, R. (2015). The American Dental Association Caries Classification System for Clinical Practice: A report of the American Dental Association Council on Scientific Affairs. *The Journal of the American Dental Association*, 146 (2), 79-86.

Zandoná, A. F., & Zero, D. T. (2006). Diagnostic tools for early caries detection. *The Journal of the American Dental Association*, 137 (12), 1675-84.

Zou, W., Hunter, N., & Swain, M. V. (2011). Application of polychromatic μ CT for mineral density determination. *Journal of Dental Research*, 90 (1), 18-30.

Percentage of contribution of each author in the manuscript

Tânia Cristina Simões – 25%

Leonardo Carmezini Marques – 14%

André Tomazini Gomes de Sá – 10%

Sandra Mara Maciel – 10%

Marcelo Lupion Poleti – 8%

Fabíola Stahlke Prado – 2%

Alejandra Hortência Miranda González – 2%

Izabel Regina Fischer Rubira-Bullen – 2%

Sandra Kalil Bussadori – 2%

Sandra Kiss Moura – 25%