

**A simplified technique to fabricate complete dentures from the previous prosthesis  
duplication for elderly patients**

**Técnica simplificada para confecção de próteses totais a partir da duplicação das  
próteses antigas para pacientes idosos**

**Técnica simplificada para la realización de prótesis completas a partir de la duplicación  
de prótesis antiguas para pacientes ancianos**

Received: 09/20/2020 | Reviewed: 09/20/2020 | Accept: 09/26/2020 | Published: 09/27/2020

**Natália Cristina Garcia Pinheiro**

ORCID: <https://orcid.org/0000-0002-8805-2272>

Universidade Federal do Rio Grande do Norte, Brasil

E-mail: [nataliacgpinheiro@gmail.com](mailto:nataliacgpinheiro@gmail.com)

**Aretha Heitor Veríssimo**

ORCID: <https://orcid.org/0000-0002-7951-8843>

Universidade Federal do Rio Grande do Norte, Brasil

E-mail: [aretha.heit@gmail.com](mailto:aretha.heit@gmail.com)

**Anne Kaline Claudino Ribeiro**

ORCID: <https://orcid.org/0000-0001-7839-1476>

Universidade Federal do Rio Grande do Norte, Brasil

E-mail: [anne\\_claudino@hotmail.com](mailto:anne_claudino@hotmail.com)

**Rachel Gomes Cardoso**

ORCID: <https://orcid.org/0000-0002-4548-418X>

Universidade Federal do Rio Grande do Norte, Brasil

E-mail: [rachelgcardoso@hotmail.com](mailto:rachelgcardoso@hotmail.com)

**Adriana da Fonte Porto Carreiro**

ORCID: <https://orcid.org/0000-0002-0833-1926>

Universidade Federal do Rio Grande do Norte, Brasil

E-mail: [adrianadafonte@hotmail.com](mailto:adrianadafonte@hotmail.com)

**Abstract**

Introduction: The time required for the complete dentures confection may be a limiting factor in the treatment of geriatric patients since these patients have age-related systemic conditions and morbidities that limit their mobility. Also, the elderly ability to adapt to a new prosthesis

with very different characteristics from the existing ones can be difficult. Methodology: This present study aims to describe a simplified technique to fabricate the complete dentures in two visits by duplicating the patient existent prosthesis, with the teeth area confectioned in wax and the other parts made of acrylic resin. The technique consists of using the replica of the patient's existent prosthesis to record the maxillomandibular relations and as a vehicle for obtaining the functional cast. Results: This technique showed the improvement of the esthetic factors, an increase of the occlusal vertical dimension, and lip support when compared to the patient's previous prosthesis. Conclusion: This technique allows the reduction of clinical steps and provides the patients with an easier adaptation of the new prosthesis.

**Keywords:** Elderly; Geriatric; Simplified complete dentures.

### **Resumo**

Introdução: O tempo necessário para a confecção das próteses totais pode ser um fator limitante no tratamento de pacientes geriátricos, uma vez que esses pacientes apresentam condições sistêmicas relacionadas à idade e morbidades que limitam sua mobilidade. Além disso, a capacidade do idoso de se adaptar a uma nova prótese com características muito diferentes das existentes pode ser difícil. Metodologia: O presente estudo tem como objetivo descrever uma técnica simplificada para confecção de próteses totais em duas visitas por meio da duplicação da prótese existente no paciente, com a área dos dentes confeccionada em cera e as demais peças em resina acrílica. A técnica consiste em utilizar a réplica da prótese existente do paciente para registro das relações maxilomandibulares e como veículo de obtenção do modelo funcional. Resultados: Esta técnica demonstrou melhora dos fatores estéticos, aumento da dimensão vertical oclusal e suporte labial quando comparada à prótese anterior do paciente. Conclusão: Esta técnica permite a redução das etapas clínicas e proporciona aos pacientes uma adaptação mais fácil da nova prótese.

**Palavras-chave:** Idoso; Geriátrico; Próteses totais simplificadas.

### **Resumen**

Introducción: El tiempo necesario para la confección de la dentadura completa puede ser un factor limitante en el tratamiento de pacientes geriátricos, ya que estos pacientes presentan afecciones sistémicas relacionadas con la edad y morbidades que limitan su movilidad. Asimismo, la capacidad del anciano para adaptarse a una nueva prótesis con características muy diferentes a las existentes puede resultar difícil. Metodología: El presente estudio tiene como objetivo describir una técnica simplificada para fabricar la dentadura completa en dos

visitas mediante la duplicación de la prótesis existente en el paciente, con el área de los dientes confeccionada en cera y las otras partes en resina acrílica. La técnica consiste en utilizar la réplica de la prótesis existente del paciente para registrar las relaciones maxilomandibulares y como vehículo para la obtención del modelo funcional. Resultados: Esta técnica mostró la mejora de los factores estéticos, aumento de la dimensión vertical oclusal y soporte labial en comparación con la prótesis anterior del paciente. Conclusión: Esta técnica permite la reducción de pasos clínicos y proporciona a los pacientes una adaptación más fácil de la nueva prótesis.

**Palabras clave:** Anciano; Geriátrico; Dentaduras postizas completas simplificadas.

## 1. Introduction

The traditional technique to rehabilitate with the conventional complete denture prosthesis is known by its methodological complexity and involves various clinical sessions (Carreiro et al., 2016). Conventionally, it consists at the following clinical steps: primary impression, functional impression, maxillomandibular relations and interocclusal records, proof of mounting, placement and post-placement care (Zarb et al., 2013). Thus, the time required for the complete dentures confection may be a limiting factor in the treatment of geriatric patients, since these patients have age-related systemic conditions and morbidities that limit their mobility (Müller, 2014).

Another important aspect at the elderly rehabilitation is the adaptation to the new complete prosthesis (Kamalakidis et al., 2016). In this population, the neuroplasticity necessary to learn new motor abilities or to adapt to the existent arrangements can be compromised (Luraschi et al., 2013). Consequently, the elderly ability to adapt to a new prosthesis with very different characteristics from the existing ones can be difficult, resulting in frustration for the patient and the dentist as well (Muller & Hasse-Sander., 1993).

In order to simplify the steps for complete denture fabrication, abbreviated techniques emerged, consisting in the elimination or simplification of some clinical and/or laboratorial phases of the traditional techniques (Cunha et al., 2013; 6. Heydecke et al., 2008; Paulino et al., 2015; Vecchia et al., 2014).<sup>5-8</sup> One of the time-reducing ways is the previous prosthesis duplication technique. Consisting to obtain the functional impression and interocclusal record from a replica of the previous prosthesis with self (Kulkarni & Pawar, 2017) or light-curing acrylic resin.<sup>10</sup> This technique is indicated in the case where the prosthesis replacement is necessary due to the wear, fractures or color alterations resulted by its long period of use

(Gorman & O'Sullivan., 2006). However, when major alterations are necessary, the adjustment during the maxillomandibular register is difficult due to the replica being fabricated completely in acrylic resin.

Aiming to facilitate the alterations on the maxillomandibular relation register, the technique proposed in this article consists of fabricating the replica with wax inserting 07 at the area corresponding to the artificial teeth and has only the base in acrylic resin. The wax easily allows for the addition or removal of material at the artificial teeth area during the esthetic adjustment and the maxillomandibular relation; moreover, it facilitates the artificial teeth arrangement by the dental prosthesis technicians.

## **2. Methodology**

The study proposes to present a description of the technique demonstrating a method for making a simplified total prosthesis using the technique of duplicating the old prosthesis through a clinical case report (case study) with descriptive, exploratory purposes, with a qualitative approach, according to Pereira, Shitsuka, Parreira, and Shitsuka (2018).

Thus, according to the knowledge from clinical practice and based on the scientific literature on the topic addressed, and considering the different possibilities of conducting the case presented, a simplified technique was proposed, which consists of using a replica of the prosthesis in use by the patient as an individual tray and registration of maxillomandibular relationships, in which the differential of our technique of the others already described in the literature is in fabricating the replica with wax insert 07 at the area corresponding to the artificial teeth and has only the base in acrylic resin.

In which the wax easily allows for the addition or removal of material at the artificial teeth area during the esthetic adjustment and the maxillomandibular relation. Moreover, it facilitates the artificial teeth arrangement by the dental prosthesis technicians. In addition to making the prosthesis will occur in two clinical consultations, favoring clinical time and adaptation patient's new prosthesis.

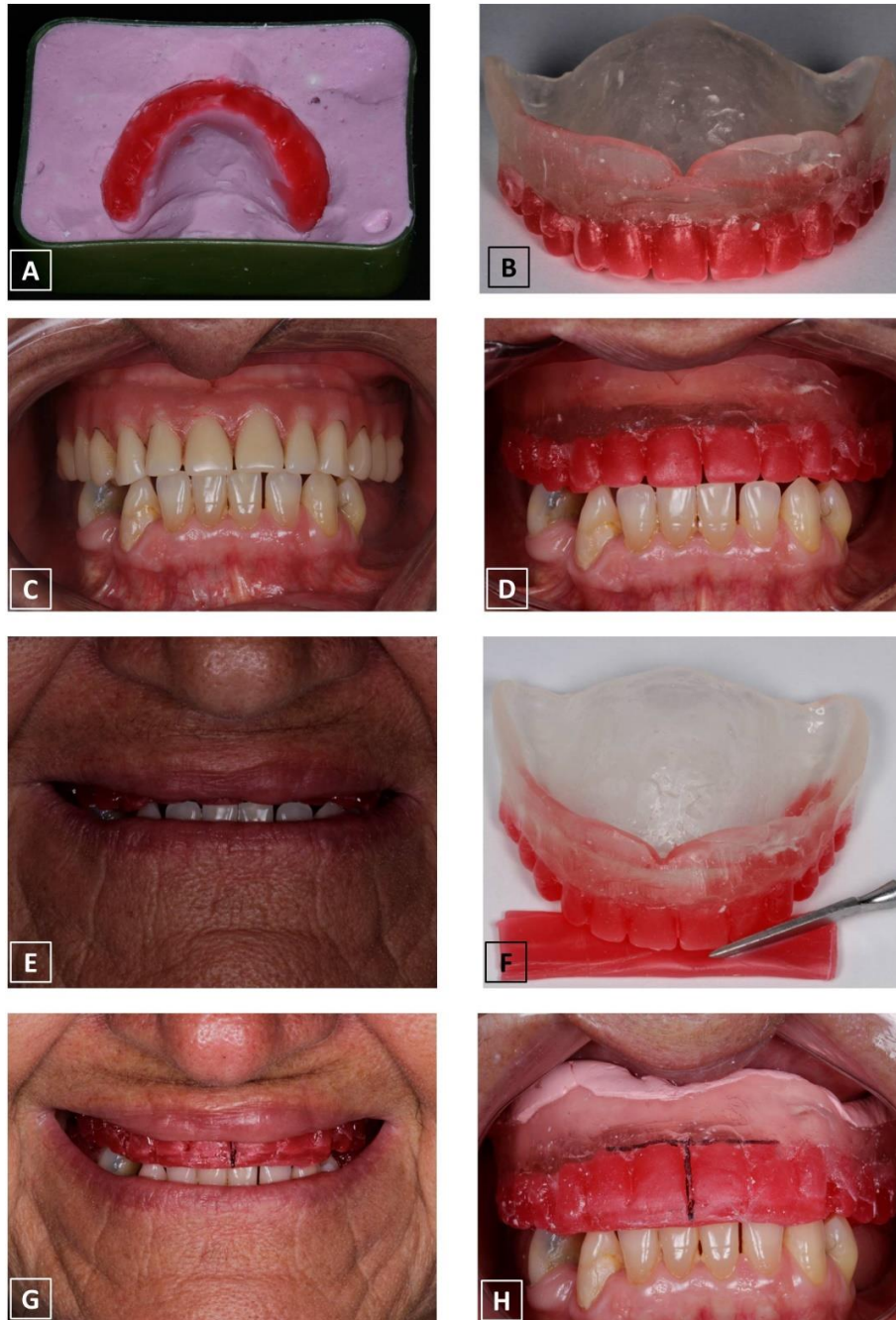
## **3. Technique**

### ***First session:***

1. Disinfection of the patient's previous prosthesis with 2.5% sodium hypochlorite (Asfer; Chemical Industry) during 10 minutes;

2. Duplication of the previous prosthesis in an adequate size plastic container filled with irreversible hydrocolloid impression material (Jeltrat; Dentsply International) and insertion of the prosthesis in the impression material;
3. Filling the negative space correspondent to the teeth with wax spacer 07 (Lysanda) (Figure 1A), then the insertion of self-curing colorless acrylic resin (VIPI) at the space corresponding to the base, and closing the container;
4. Immersion of the container in water inside a pressurized curing unit (Blue Dentistry and Medical Equipment Ltda) at 2.5 Kgf/cm during 20 minutes, aiming to promote as lower number of bubbles as possible at the resin base;
5. Finishing and polishing procedures at the duplicated prosthesis (Figure 1B), and confection of the occlusal plane of orientation over the antagonist cast;
6. Oral analysis of the maxillary complete denture (Figure 1C), duplicate prosthesis (Figure 1D), and adjustment of the retentive areas or at the soft-tissue areas with a maxi-cut bur (Wilcos of Brazil Industry and Commerce Ltda);
7. Evaluation of the duplicate prosthesis bearing area, if necessary perform adjustments to reduce or add to increase the edge extension with low-fusing modeling compound or heavy-bodied condensation silicone;
8. Esthetic adjustments of the lip support and the maxillary occlusal plane orientation on the duplicated prosthesis. Followed of the adjustment of the maxillomandibular relation register and marking the lines of reference to select the artificial teeth. Register the occlusal vertical dimension 1mm shorter to compensate the thickness of the impression material that will be subsequently accommodated (Figure 1E-G);
9. When necessary, obtain the peripheral impression with low-fusing modelling compound stick (Lysanda), closed-mouth functional impression with zinc and eugenol paste or an elastomeric material (Lysanda), using the duplicated prosthesis as the custom tray (Figure 1H);
10. Selection of the artificial teeth (Biolux, VIPI odontological products), and artificial gingival color.

**Figure 1.** First clinical visit: **A-** maxillary complete denture (CD) duplication with alginate and wax poured in the teeth area. **B-** CD replica. **C-** Previous CD in the mouth. **D-** Duplication trial in the mouth. **E-** Evaluation of the duplicated prosthesis lip support. **F-** Adjustment of the maxillary occlusal plane orientation. **G-** Duplicated prosthesis try-in after adjustments. **H-** Functional impression with closed mouth.



Source: Authors.

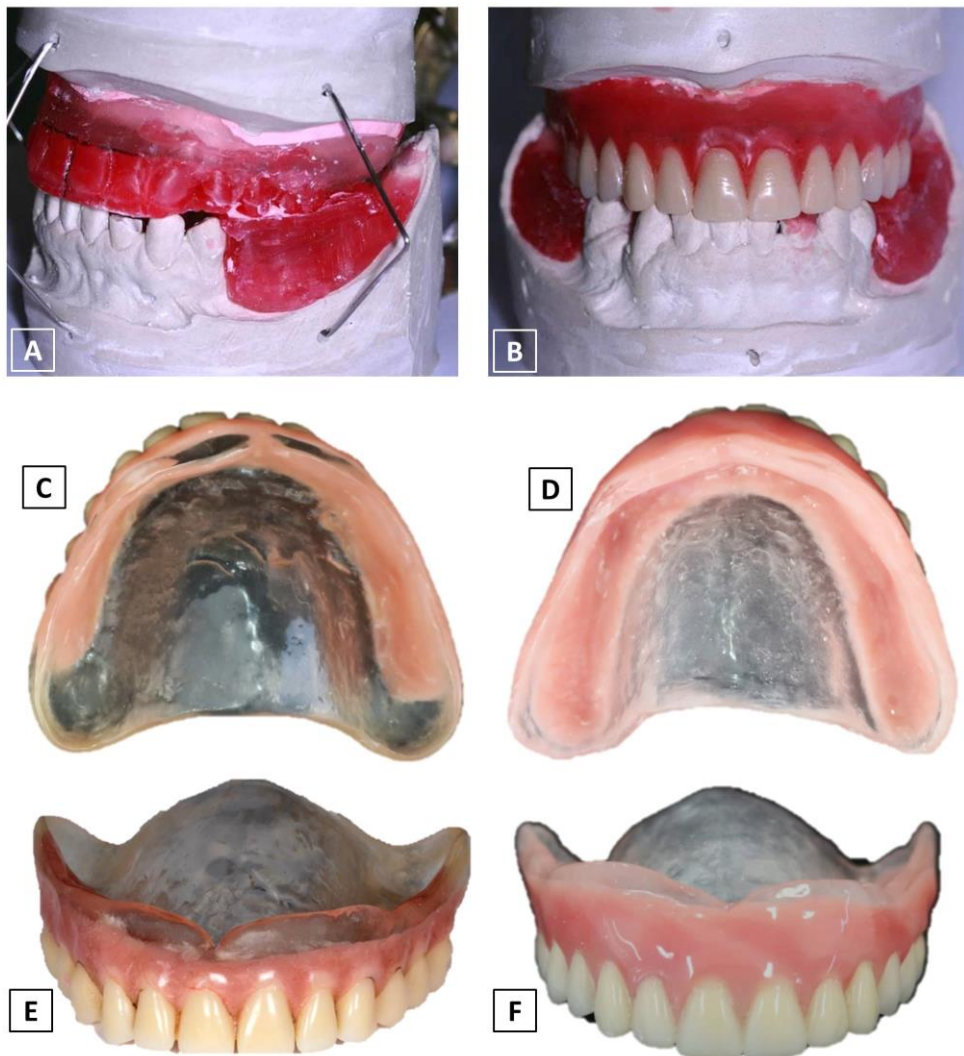
In image 1A, it is possible to observe the wax inserted in the duplication mold leaving the space for insertion of the acrylic resin. Image B with duplication completed, area of the teeth in wax, and base of the duplication in acrylic resin. Image C patient with old prosthesis intraoral view compared to duplication in image D. Image E shows a lack of lip support and

decrease in the height of the vertical dimension of occlusion, requiring adjustment and insertion of wax observed in images F and G, followed by a functional impression of the duplication in occlusion observed in image H.

**Laboratorial procedures:**

1. Confection of the functional cast and articulator mounting using the register (Figure 2A);
2. Teeth arrangement (Figure 2B) and acrylization (Figure 2C-F);

**Figure 2.** Laboratorial steps: **A-** Maxillomandibular relation register at the articulator mounting. **B-** Artificial teeth arrangement. Previous acrylic prosthesis base view (C) and frontal view (E). New acrylic prosthesis base (D) and frontal view (F).



Source: Authors.

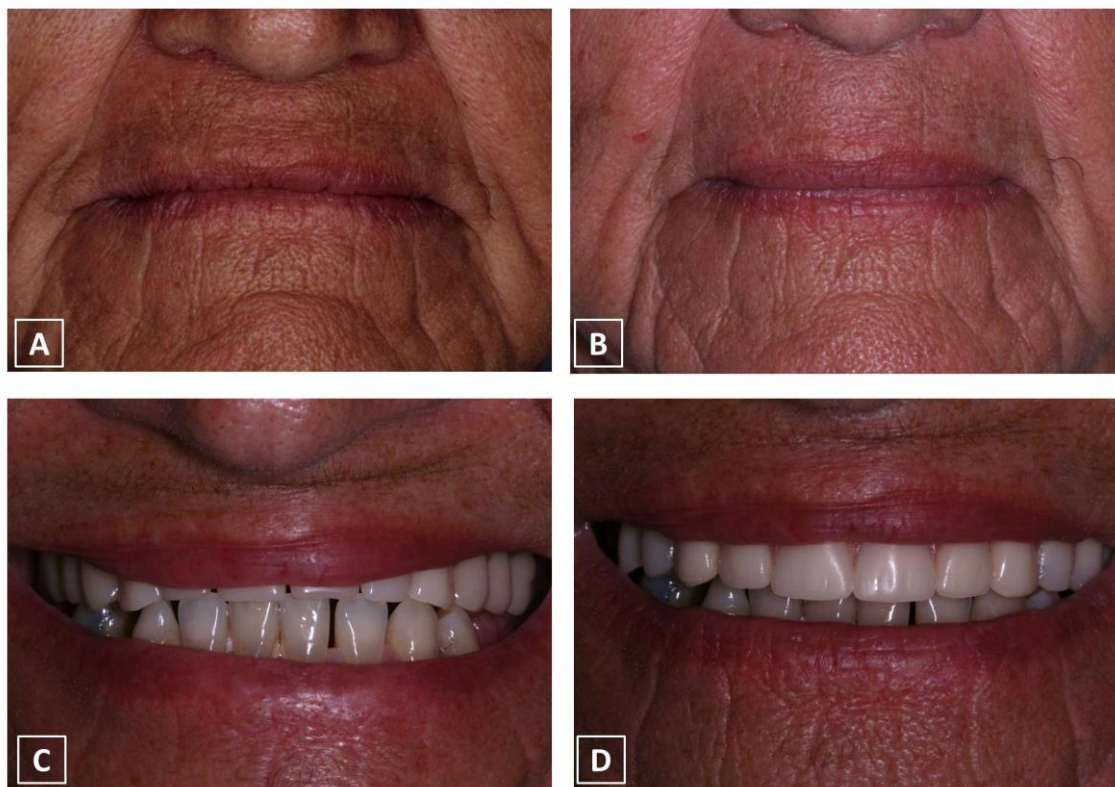Image 2A showing duplication of the total prosthesis after being fitted to an articulator

in which the necessary parameters for fitting the artificial teeth shown in image B can be observed. Images C and E showing old prosthesis with incisal wear and lower vestibular volume compared to images D and F that present the new prosthesis resulting from duplication, presenting better volume and vestibular height.

***Second and last session:***

Placement of the new prosthesis (Figure 3 A-D) and adjustments.

**Figure 3.** Second clinical visit: Patient with the previous prosthesis (A) and after the placement of the new prosthesis (B) with closed lip. Patient smiling with the previous (C) and new maxillary complete denture (D).



Source: Authors.

Image 3A and C of the patient with the old total prosthesis with impaired lip support and decreased vertical dimension of occlusion, observe the wear of the teeth of the old prosthesis. Images B and D patient after the installation of the new total prosthesis presented adequate lip support and vertical dimension of occlusion with aesthetic improvement.



#### **4. Discussion**

This technique showed the improvement of the esthetic factors, increase of the occlusal vertical dimension and lip support when compared to the patient's previous prosthesis. Moreover, the similarity of the bearing area of the new prosthesis with the old one is a favorable aspect for the patient adaptation with the new prosthesis (Gorman & O'Sullivan,, 2006; Carreiro et al., 2008).

The reduction in the number of the laboratorial and clinical steps also represents an advantage, compared to the conventional technique where there is an average of five or more clinical visits (Zarb et al., 2013). This present technique requires only two clinical visits. The reduction in the number of clinical visits represents higher convenience to the patients and a reduction in cost. Previous studies showed the average price for the confection of complete dentures through the traditional method is significantly more expensive compared with simplified methods (Cunha et al, 2013; Paulino et al, 2015; Vecchia et al., 2014; Kawai et al., 2010; Ceruti et al., 2017).

Regarding the laboratorial steps, the references of the previous prosthesis facilitates the artificial teeth arrangement. Moreover, since the teeth area is in wax spacer 07, it can be easily removed to enable the artificial teeth arrangement, which is not possible to occur when the replica is totally fabricated with acrylic resin. However, this technique presents a limitation requiring that the patient's previous complete denture present a minimal quality, associated to the bearing area, to use it as a parameter for the duplication.

#### **5. Conclusion**

The use of a replica/duplication from the patient's previous prosthesis as a custom tray and the maxillomandibular relation register can help to fabricate a new complete denture. A simplified technique was described where the new complete denture was fabricated in only two visits, favoring the chairside time and the patient's adaptation to the new prosthesis.

However, although the simplified technique previously described has advantages, there is a lack of controlled and randomized clinical studies that demonstrate the efficiency and effectiveness of this duplication technique as to its clinical performance in the short, medium, and long term. Because, it is necessary to prove clinically that the alternative duplication technique, which uses the old prosthesis as a reference for functional impression

and intermaxillary registration, promotes greater satisfaction, quality of life related to oral health, masticatory performance, and technical quality than the method conventional.

## References

Carreiro, A. F. P., Caderon, P. S., Duarte, A. R. C., Medeiros, A. K. B., Tôrres, A. C. S. P., Melo, L. A., & Farias, D. B. (2016.) *Protocolo clínico para confecção de próteses removíveis*. Natal, Rio Grande do Norte: EDUFRN.

Carreiro, A. F. P., de Torres, E. M., Souza, A. A., & Ribeiro, R. F. (2008) An alternative and simplified technique for the impression of completely edentulous ridges. *Gen Dent*; 56, 158-9.

Ceruti, P., Mobilio, N., Bellia, E., Borracchini, A., Catapano, S., & Gassino, G. (2017) Simplified edentulous treatment: a multicenter randomized controlled trial to evaluate the timing and clinical outcomes of the technique. *J Prosthet Dent*; 118, 462-467.

Cunha, T. R., Della Vecchia, M. P., Regis, R. R., Ribeiro, A. B., Muglia, V. A., & Mestriner, W. Jr. (2013) A randomized trial on simplified and conventional methods for complete denture fabrication: masticatory performance and ability. *J Dent*; 41, 133-42.

Gorman, C. M., & O'Sullivan, M. Fabrication of a duplicate denture using visible light-polymerized resin as an interim denture base. (2006) *J Prosthet Dent*; 96, 374-6.

Heydecke, G., Vogeler, M., Wolkewitz, M., Turp, J. C., & Strub, J. R. (2008) Simplified versus comprehensive fabrication of complete dentures: patient ratings of denture satisfaction from a randomized crossover trial. *Quintessence Int*; 39, 107-16.

Kamalakidis, S. N., Anastassiadou, V., Sofou, A., & Pissiotis, A. L. (2016) Comparative Study of Acceptance and Adaptation to New Complete Dentures, Using Two Construction Protocols. *J Prosthodont.*; 25(7), 536-543. doi:10.1111/jopr.12466

Kawai, Y., Murakami, H., Takanashi, Y., Lund, J. P., & Feine, J. S. (2010) Efficient resource use in simplified complete denture fabrication. *J Prosthodont*; 19, 512-6.

Kulkarni, R. S., & Pawar, R. S. (2017) Fabrication of complete dentures in three visits using existing prosthesis- a simplified technique for geriatric patients. *Spec Care Dentist*; 37, 99-101.

Luraschi, J., Korgaonkar, M., Whittle, T., Schimmel, M., Muller, F., & Klineberg, I. (2013) Neuroplasticity in the adaptation to prosthodontic treatment. *J Orofac Pain*; 27, 206–16.

Muller, F., & Hasse-Sander, I. (1993) Experimental studies of adaptation to complete dentures related to ageing. *Gerodontology*; 10, 23–7.

Müller F. (2014) Interventions for edentate elders--what is the evidence? *Gerodontology*;1, 44-51.

Paulino, M. R., Alves, L. R., Gurgel, B. C., & Calderon, P. S. (2015) Simplified versus traditional techniques for complete denture fabrication: a systematic review. *J Prosthet Dent*; 113, 12-6.

Pereira, A. S., et al. (2018). *Metodologia da pesquisa científica*. [e-book]. Santa Maria. Ed. UAB/NTE/UFSM. Recuperado de [https://repositorio.ufsm.br/bitstream/handle/1/15824/Lic\\_Computacao\\_Metodologia-Pesquisa-Cientifica.pdf?sequence=1](https://repositorio.ufsm.br/bitstream/handle/1/15824/Lic_Computacao_Metodologia-Pesquisa-Cientifica.pdf?sequence=1).

Vecchia, M. P., Regis, R. R., Cunha, T. R., de Andrade, I. M., da Matta, J. C., & de Souza, R. F. (2014) A randomized trial on simplified and conventional methods for complete denture fabrication: cost analysis. *J Prosthodont.*; 23, 182-91.

Zarb, G., Hobkirk, J., Eckert, S., & Jacob, R. (2013) *Prosthodontic Treatment for Edentulous Patients: Complete Dentures and Implant-Supported Protheses*. (13th ed.), St Louis: Mosby.. p. 464.

**Percentage of contribution of each author in the manuscript**

Natália Cristina Garcia Pinheiro – 20%

Aretha Heitor Veríssimo – 20%

Anne Kaline Claudino Ribeiro – 20%

Rachel Gomes Cardoso – 20%

Adriana da Fonte Porto Carreiro – 20%