

**Radiographic assessment of the influence of metopism in frontal sinus morphology – a
systematic review**

**Avaliação radiográfica da influência do metopismo na anatomia do seio frontal – uma
revisão sistemática**

**Evaluación radiográfica de la influencia del metopismo en la morfología del seno frontal
– una revisión sistemática**

Received: 10/02/2020 | Reviewed: 10/05/2020 | Accept: 10/07/2020 | Published: 10/09/2020

Raquel Porto Alegre Valente Franco

ORCID: <https://orcid.org/0000-0001-9398-9302>

Department of Forensic Medicine and Pathology, Faculty of Medicine of Ribeirão Preto,
Ribeirão Preto, Brazil

E-mail: raaquelvalente@gmail.com

Ademir Franco

ORCID: <https://orcid.org/0000-0002-1417-2781>

Division of Forensic Dentistry, Instituto de Pesquisas São Leopoldo Mandic, Faculdade São
Leopoldo Mandic, Campinas, Brazil

E-mail: franco.gat@gmail.com

Maria de Pádua Fernandes

ORCID: <https://orcid.org/0000-0002-8115-9827>

Department of Forensic Medicine and Pathology, Faculty of Medicine of Ribeirão Preto,
Ribeirão Preto, Brazil

E-mail: maria.padua.fernandes@usp.br

Adriele Alves Pinheiro

ORCID: <https://orcid.org/0000-0001-5429-0742>

Division of Forensic Dentistry, Instituto de Pesquisas São Leopoldo Mandic, Faculdade São
Leopoldo Mandic, Campinas, Brazil

E-mail: adriele.alves.pinheiro@gmail.com

Ricardo Henrique Alves da Silva

ORCID: <https://orcid.org/0000-0002-1532-1670>

Department of Stomatology, Public Health and Social Dentistry, Faculty of Dentistry of
Ribeirão Preto, Ribeirão Preto, Brazil

E-mail: ricardohenrique@usp.br

Abstract

Objective: This systematic literature reviews aimed to revisit radiographic observational studies the find out the potential influence of metopism in frontal sinus (FS) development. **Methodology:** Medline, Scopus, SciELO, LILACS and Web of Science databases were searched. Only cross-sectional and case-control original studies were eligible. Two reviewers independently participated in each phase of this review. General, methodological and outcome-related information of each study were extracted. Risk of bias was assessed with the Joanna Briggs Institute (JBI) Critical Appraisal tool for observational studies. Based on the limitations of each study, recommendations were made following EQUATOR/STROBE guidelines. **Results:** Depicted in an adapted PRISMA flowchart, three-hundred and sixty-five studies were identified and seven (published between 1959-2019) remained for qualitative analysis. Without considering studies with overlapping samples, five-hundred and nine skulls with metopism were detected. FS aplasia reached a prevalence of nearly 13%. Four studies (three with overlapping samples) observed a tendency of FS underdevelopment in skulls with metopism, while three studies suggested the opposite. Higher risk of bias was found in the latter. **Conclusion:** The available and most recent scientific literature points toward an eventual influence of metopism in FS underdevelopment. Due to the study of overlapping samples and the lack of standardized reporting protocols of methods and outcomes, however, the evidence extracted in the present systematic literature review does not confirm the association of FS underdevelopment and metopism.

Keywords: Anatomy; Frontal sinus; Metopism; Radiology; Suture.

Resumo

Objetivo: Esta revisão sistemática da literatura teve como objetivo revisar estudos observacionais radiográficos para descobrir a influência potencial do metopismo no desenvolvimento do seio frontal (FS). **Metodologia:** Foram pesquisadas as bases de dados Medline, Scopus, SciELO, LILACS e Web of Science. Somente estudos originais transversais e de caso-controle foram selecionados. Dois revisores participaram independentemente de cada fase desta revisão. Informações gerais, metodológicas e relacionadas aos resultados de cada estudo foram extraídas. O risco de viés foi avaliado com a ferramenta de avaliação crítica do Joanna Briggs Institute (JBI) para estudos observacionais. Com base nas limitações de cada estudo, as recomendações foram feitas seguindo as diretrizes EQUATOR / STROBE. **Resultados:** Descritos em um fluxograma PRISMA adaptado, trezentos e sessenta e cinco estudos foram identificados e sete (publicados entre 1959-2019) permaneceram para análise

qualitativa. Sem considerar estudos com amostras sobrepostas, foram detectados quinhentos e nove crânios com metopismo. A aplasia de FS atingiu uma prevalência de quase 13%. Quatro estudos (três com amostras sobrepostas) observaram uma tendência de subdesenvolvimento do FS em crânios com metopismo, enquanto três estudos sugeriram o contrário (estes com maior risco de viés). Conclusão: A literatura científica disponível e mais recente aponta para uma eventual influência do metopismo no subdesenvolvimento da SF. No entanto, devido ao estudo de amostras sobrepostas e à falta de protocolos padronizados para a publicação de métodos e resultados, as evidências extraídas na presente revisão sistemática da literatura não confirmam a associação de subdesenvolvimento de SF e metopismo.

Palavras-chave: Anatomia; Seio frontal; Metopismo; Radiologia; Sutura.

Resumen

Objetivo: Esta revisión sistemática de la literatura tuvo como objetivo revisar los estudios observacionales radiográficos para descubrir la posible influencia del metopismo en el desarrollo del seno frontal (SF). **Metodología:** Se realizaron búsquedas en las bases de datos de Medline, Scopus, SciELO, LILACS y Web of Science. Solo fueron elegibles los estudios originales transversales y de casos y controles. Dos revisores participaron de forma independiente en cada fase de esta revisión. Se extrajo información general, metodológica y relacionada con los resultados de cada estudio. El riesgo de sesgo se evaluó con la herramienta de evaluación crítica del Instituto Joanna Briggs (JBI) para estudios observacionales. Con base en las limitaciones de cada estudio, se hicieron recomendaciones siguiendo las pautas de EQUATOR / STROBE. **Resultados:** Representado en un diagrama de flujo PRISMA adaptado, se identificaron trescientos sesenta y cinco estudios y siete (publicados entre 1959-2019) quedaron para el análisis cualitativo. Sin considerar estudios con muestras superpuestas, se detectaron quinientos nueve cráneos con metopismo. La aplasia FS alcanzó una prevalencia cercana al 13%. Cuatro estudios (tres con muestras superpuestas) observaron una tendencia de subdesarrollo de FS en cráneos con metopismo, mientras que tres estudios sugirieron lo contrario. En este último se encontró un mayor riesgo de sesgo. **Conclusión:** La literatura científica disponible y más reciente apunta hacia una eventual influencia del metopismo en el subdesarrollo del SF. Sin embargo, debido al estudio de muestras superpuestas y la falta de protocolos de informes estandarizados de métodos y resultados, la evidencia extraída en la presente revisión sistemática de la literatura no confirma la asociación del subdesarrollo del SF y el metopismo.

Palabras clave: Anatomía; Seno frontal; Metopismo; Radiología; Sutura.

1. Introduction

The articulating system of the human skeleton may be classified in groups according to function as synarthroses, amphiarthroses and diarthroses (Moore et al., 2017). These groups indicate that articulating bones have slight (or non-existing), moderate and broad movement between each other, respectively (Schünke et al., 2014). Particularly in the synarthroses, most of the joints are fibrous, such as the cranial sutures (Totor & Nielsen, 2017). Depending on the edges of the articulating bones and the arrangement of their interface, sutures may be plane – between bones with smooth linear surfaces (e.g. intermaxillary suture), serrated – between bones with interdigitation (e.g. sagittal suture), overlapping – when the edge of one bone is covered by the edge of the other (e.g. squamosal suture), and schindylesis – a type of suture that fits bones ridge-to-groove (e.g. vomero-sphenoid suture) (Craigie, 1838; Rawlani & Rawlani, 2013).

The metopic suture (MS) represents one of the six primary sutures of the infant skull (Miura et al., 2009). From Nasion (intersection between internasal and frontonasal sutures) to the anterior fontanelle (latter replaced by the Bregma – intersection between coronal and sagittal sutures), the MS describes an indentate midsagittal pathway dividing the frontal bone in half (Skrzat et al., 2004). Early in life, this suture plays an important part in enabling the development of the encephalus together with other sutures and fontanelles (Lipsett & Steanson, 2019). Additionally, because it is anatomically displayed in the anterior neurocranium, the MS may have a secondary role in the symmetrical development of the upper third of the face (forehead). Whereas most of the cranial sutures reach synostosis during adolescence and young adulthood, the MS has estimated closure interval between three and nine months after birth (Vu et al., 2001). Metopism occurs when persisting MS are found in adults skulls (Bademci et al., 2007; Zdilla, et al., 2018; Vinchon et al., 2019).

Studies have pointed prevalence rates of metopism up to 7% depending on population (Aksu et al., 2014). However, statistics might vary not only based on ancestry, but also based on individual's systemic condition. Syndromic patients or individuals with preexisting morphological alterations (anatomical variation, anomaly or monstrosity), such as severe dentomaxillofacial discrepancies (Nelke et al., 2014) might present metopism more often. Obscurity remains on the influence of metopism in morphological alterations of the frontal sinuses (FS) (Nikolova et al., 2018). These are cavities bilaterally present in the frontal bone split by an intersinus septum, beneath the anterior cortical plate (Silva et al., 2019). Didactically, FS belong to the four types of paranasal sinuses, together with maxillary,

sphenoidal and etmoidal air cells (Silva et al., 2014). In practice, the FS have clinical and forensic applications. In the former, they reduce the weight of the skull and participate in immune systems by producing mucus to be distributed into the upper airways (Fahrioglu et al., 2018). In the latter, the distinctive morphology of the FS may be used for human identification and anthropological investigations (Silva et al., 2008; Silva et al., 2009; Silva et al., 2013; Silva et al., 2017; Furtado et al., 2018). What clinical and forensic applications have in common is the study of the FS by means of radiographic qualitative or quantitative assessment as a non-invasive approach to exam sinus integrity, outline, volume and content (Beaini et al., 2014; Sahlstrand-Johnson et al., 2011; Ribeiro, 2000).

Compiling studies to better understanding the potential influence of metopism in morphological alterations of the FS is a current need in science. This study revisited original articles that radiographically assessed FS in individuals with metopism in the search for potential associations. The hypothesis addressed in the present systematic review was that FS morphology is indeed affected by metopism. In order to test the hypothesis, methods and outcomes of these eligible studies were analyzed to find out the answer for the following question: “What is the available evidence to affirm morphological alteration of the FS influenced by metopism in radiographs of the human skull?”

2. Methodology

2.1 Study Design

Secondary data was assessed in this study. Ethical clearance was obtained. The nature of the study was qualitative, and consisted of a systematic literature review (Pereira et al., 2018). The review was designed following the Preferred Reporting Items for Systematic Reviews and Meta-Analyses (PRISMA) (Moher et al., 2015) and based on Cochrane (Higgins & Green, 2011) guidelines.

2.2 Eligibility Criteria

Studies exclusively dedicated to the investigation of metopism and its influence on the development of the FS by means of imaging were included. Studies with retrospective or prospective sampling from image databases were included. Literature reviews (systematic or not), case reports, case series, letter to the editor, editorials, abstracts in proceedings of

conferences and unpublished academic material were excluded. Original observational studies that did not state clearly their intention to investigate the influence of metopism on FS morphology were excluded as well. Finally, studies that clearly investigated samples of individuals with developmental disorders, systemic diseases/conditions and history of trauma also fit to the exclusion criteria (to avoid the bias of condition over FS anatomy).

2.3 Research and Sources

Population (P), variables (V) and outcomes (O) retrospectively represented by human skull, metopism and radiographic alterations of FS morphology were used to establish the research question previously presented.

Medline, LILACS, SciELO, Scopus and Web of Science were searched as primary data sources. A search string of keywords (predominantly built of Medical Subject Headings [MeSH] and Descriptors in Health Sciences [DeCS]) and Boolean operator (“AND”, “OR” and “NOT”) was built. The terms were clustered in two main groups with variations based on their plural forms. The first, related to the MS, namely “metopic suture”, “metopism”, “interfrontal suture” and “median frontal suture”; the second, related to the FS, namely “frontal sinus” and “paranasal sinus”. The search was performed on November 4th 2019. Restriction of the year of publication was not applied, while language of publication was restricted to English, Spanish and Portuguese.

The obtained studies were imported in Mendeley™ (Mendeley Ltd., London, UK) software for the removal of duplicates. Eventually remaining duplicates were manually removed.

2.4 Study Selection

Two main trained reviewers were enrolled during study selection. In every selection phase, a third reviewer was included to enable consensus in case of disagreement. The first phase of study selection consisted of the title reading. The reviewers read and excluded titles that were not related to the research topic. They were not blind for authorships and journals. Next, the abstracts were read and excluded based on eligibility criteria. Studies with missing abstracts proceeded to the next phase without exclusion. The third phase established full-text reading and exclusion. Studies excluded in this phase had the reason for their exclusion registered.

2.5 Data Extraction

Were extracted from each study publication data, such as authorship, year and country of publication, name of the article and name of the journal. Methodological information consisted of sample size, sample distribution for individuals with metopic suture, distribution of males and females, age interval (minimum and maximum age), type of image exam, imaging device, number of examiners and type of analysis (quantitative or qualitative). Extracted data related to outcomes were atrophy, hypertrophy or agenesis of the FS (right, left or bilateral).

2.6 Risk of Bias in Eligible Studies

The Joanna Briggs Institute (JBI) Critical Appraisal tool for assessing the risk of bias in observational cross-sectional studies was used (Munn et al., 2015). The eligible studies were rated based on their percentage of positive answers to the questions inherent to the JBI tool. High risk of bias was found when less than 50% of positive answers occurred. Moderate risk of bias ranged between 50 and 69% of positive answers, while low risk of bias was found in studies with more than 70% of positive answers. Given the possible limitations of the studies, recommendation will be provided for improvement of future investigations following the Enhancing the Quality and Transparency of Health Research (EQUATOR) and Strengthening the Reporting of Observational Studies in Epidemiology (STROBE).

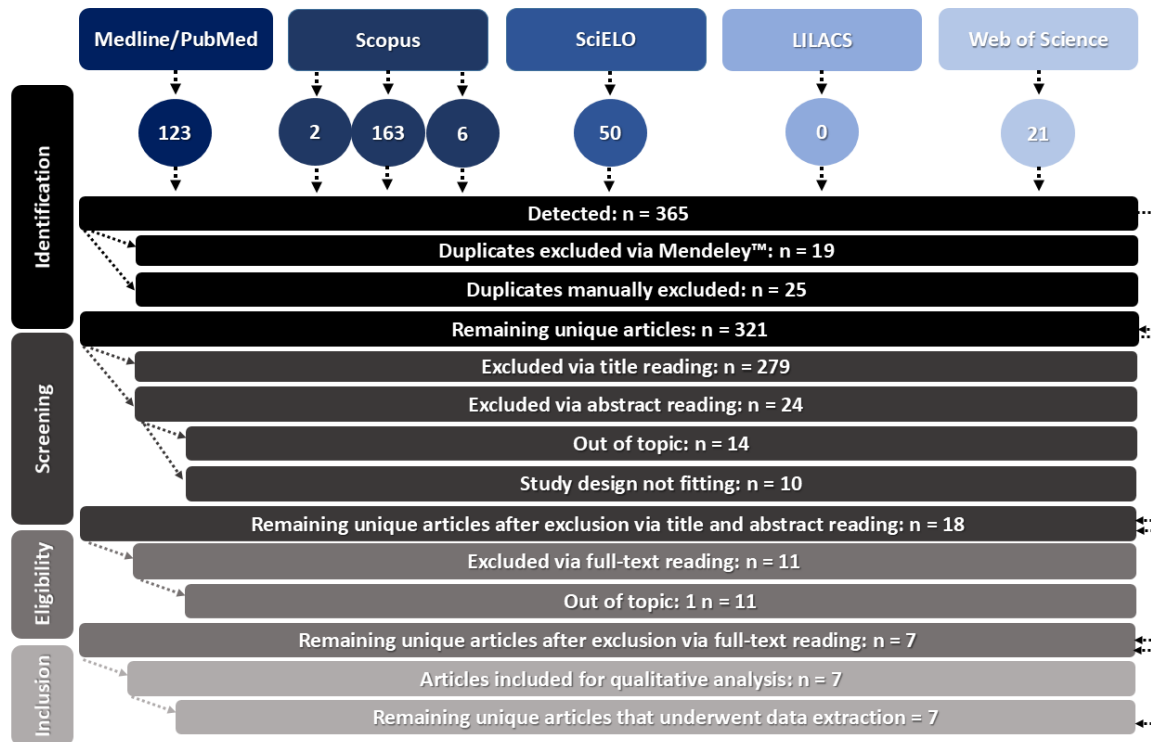
3. Results

3.1 Selection of Studies

The initial search found 365 studies. Twenty-five duplicates were automatically excluded via software checking, while manual exclusion removed additional 19 studies. Title reading was performed in 321 studies. Two-hundred seventy-nine studies were excluded, leaving 24 to be excluded through abstract reading. Eighteen studies remained for full-text reading. After careful reading and eleven exclusions, seven studies (Marciniak et al. & Nizankowski, 1959; Bilgin et al., 2013; Guerram et al., 2014; Nikolova et al., 2016; Sandre et al., 2017; Nikolova et al., 2018; Nikolova & Toneva, 2019) were included for qualitative analysis based on eligibility criteria (Figure 1). The studies removed in the last phase were

registered with their respective reasons for exclusion (Appendix I).

Figure 1 – Flowchart of the study selection process based on titles, abstract and full-text reading within the eligible criteria established in this systematic review.



Adapted from PRISMA
 Scopus search: 2 articles in Portuguese, 163 in English and 6 in Spanish language

Source: Authors.

3.2 Characteristics of the Studies

The studies were published between 1959 and 2019. The main countries of investigation were Brazil (n = 1), Bulgaria (n = 3), France (n = 1), Poland (n = 1) and Turkey (n = 1) (Table 1).

Most of the studies reported the sampled individuals as adults, except for a single study that reported age upper bound of 20 years with no clear lower limit. Sex was not always clearly described (Marciniak & Nizankowski, 1959; Guerram et al., 2014). Six (Marciniak & Nizankowski, 1959; Guerram et al., 2014; Nikolova et al., 2016; Sandre et al., 2017; Nikolova et al., 2018; Nikolova & Toneva, 2019) out of seven eligible studies were performed with osteological collections. Two studies that included analysis of the living dealt with existing

image databases (Marciniak et al. & Nizankowski, 1959; Bilgin et al., 2013) – retrospective sampling; while the studies with ex-vivo human skulls from osteological collections were prospective (by acquiring images from the existing skulls) (Table 2).

Table 1 - General publication information of the eligible articles.

#	Authors	Country	Title	Journal
1	Marciniak et al., ³² 1959	Poland	Metopism and its correlation with the development of the frontal sinuses	Acta Radiol
2	Bilgin et al., ³³ 2013	Turkey	Association between frontal sinus development and the persistent metopic suture	Folia Morphol
3	Guerram et al., ³⁴ 2014	France	Brief communication: the size of the human frontal sinuses in adults presenting complete persistence of the metopic suture	Am J Phys Anthropol
4	Nikolova et al., ³⁵ 2016	Bulgaria	A persistent metopic suture – incidence and influence on the frontal sinus development	Acta Morphol Anthropol
5	Nikolova et al., ³⁶ 2018	Bulgaria	Digital radiomorphometric analysis of the frontal sinus and assessment of the relation between persistent metopic suture and frontal sinus development	Am J Phys Anthropol
6	Sandre et al., ³⁷ 2017	Brazil	Prevalence of agenesis of frontal sinus in human skulls with metopism	J Forensic Odonto-Stomatol
7	Nikolova et al., ³⁸ 2019	Bulgaria	Frontal sinus dimensions in the presence of persistent metopic suture	Acta Morphol Anthropol

Numbers from #1 to #7 used for referencing eligible studies throughout tables. Source: Authors.

Five studies performed bidimensional (2D) analysis in radiographs (Marciniak et al. & Nizankowski, 1959; Guerram et al., 2014; Nikolova et al., 2016; Sandre et al., 2017; Nikolova et al., 2018) of the skulls (techniques included PA, Towne's, Waters' and Caldwell's projection), while two studies performed computed tomography scans (one included magnetic resonance imaging) (Bilgin et al., 2013; Nikolova & Toneva, 2019). Protocols for image acquisition highly varied between studies. Only three studies reported the number of involved examiners (Sandre et al., 2017; Nikolova et al., 2018; Nikolova & Toneva, 2019). Quantitative analyses (metric) were performed in three studies (Sandre et al., 2017; Nikolova et al., 2018; Nikolova & Toneva, 2019) (Table 3).

Table 2 – Methodological data extracted from the eligible articles, part 1 (sample aspects).

#	n	F	M	Age (years)	Origin	Sampling interval	Image acquisition
1	3.512	>1.240	>778	<20	living / osteological collection	3 years / skulls from ≈1939	retrospective / prospective
2	631	414	217	30-93 (mean: 48.37)	living	7 months	retrospective
3	143	>40	>40	adults	osteological collection	contemporary skulls	prospective
4	82	0	82	adults	osteological collection	skulls from 1912-1918	prospective
5	230	0	230	adults	osteological collection	skulls from 1912-1918	prospective
6	245	>3*	>11*	adults	osteological collection	contemporary skulls	prospective
7	125	0	125	adults	osteological collection	skulls from 1912-1918	prospective

#1-7: study referencing number (Table 1); n: total sample size; F: females; M: males. Retrospective image acquisition: revisiting existing image databases of living patients; *anthropological sex estimation. Prospective image acquisition: obtaining images from existing human skulls. Study #6 was the only mentioning ethical approval. Source: Authors.

Skulls with metopism (persistent metopic suture) varied from 17 to 278 among the eligible studies. Out of the studies that reported the prevalence of aplasia of FS (n = 6), skulls with metopism accounted 599. Considering that some articles had overlapping samples (Nikolova et al., 2016; Nikolova et al., 2018; Nikolova & Toneva, 2019), a final reduction of the overall sample size of metopic skulls was performed to narrow it to 509. In this context, FS affected with aplasia accounted for nearly 13%. Without considering overlapping conclusions (studies with overlapping samples), two studies had a final statement towards the indication of FS underdevelopment in skulls with metopism (Nikolova et al., 2016; Nikolova & Toneva, 2019), while three studies suggested that metopism might not influence alterations in FS development (Marciniak et al. & Nizankowski, 1959; Bilgin et al., 2013; Sandre et al., 2017) (Table 4).

Table 3 – Methodological data extracted from the eligible articles, part 2 (image aspects).

#	Image	Technique	Device	Protocol	Examiners	Analysis
1	radiographs	PA and half-axial (Towne) projection	n/r	n/r	n/r	unclear
2	CT scans and MRI	Head in neutral position: coronal, sagittal and axial plane views	CT: 64-slice spiral Aquilion™ (Toshiba, Tokyo, Japan) MRI: 1.5T Essenza™ (Siemens, Munich, Germany)	CT: slice thickness and interval of 5 and 3 mm. 550 mA, 135 kV, 1.5 seconds	n/r	unclear
3	radiographs	Waters' view	n/r	n/r	n/r	qualitative
4	radiographs	Caldwell's view	XT H 225™ (Nikon, Tokyo, Japan)	80-100 mA*, 95-16 kV, 1 second	n/r	qualitative
5	radiographs	Caldwell's view	XT H 225™ (Nikon, Tokyo, Japan)	104-176 mA*, 99-144 kV, 0.5 seconds / 94-144 mA, 94-124 kV, 0.7 seconds	Two	qualitative and quantitative
6	radiographs	PA projection	MobileDaRt Evolution™ (Shimadzu, Kyoto, Japan)	16 mA, 64 kV	Two	qualitative and quantitative
7	CT scans	n/r	XT H 225™ (Nikon, Tokyo, Japan)	100 mA*, 100 kV, 0.5 seconds	One	qualitative and quantitative

#1-7: Studies referencing number (Table 1); CT: computed tomography; MRI: magnetic resonance imaging; PA: posteroanterior; n/r: not reported; *: authors original report was μ A instead of mA. Source: Authors.

Table 4 – Main outcomes of the eligible studies (size of sinuses and highlight statement).

#	Metopism	Aplasia	Hypoplasia	Medium	Hyperplasia	Highlight statement
1	278 skulls	66 sinuses**	-	-	-	Do not support the association of metopism and under-developed frontal sinuses ^b
2	61 skulls	21 underdeveloped sinuses (6 bilateral, 7 right, 2 left)*				No significant relationship in metopism and frontal sinus abnormal development ^b
3	63 skulls	9 sinuses	64 sinuses	51 sinuses	2 sinuses	Over half of the skulls with metopism presented underdeveloped frontal sinuses ^a
4	40 skulls	14 sinuses	18 sinuses	48 sinuses	0	Metopism possibly represses the development of frontal sinuses ^a
5	93 skulls	25 sinuses	29 sinuses	102 sinuses	30 sinuses	Shows a tendency of metopism in skulls with underdeveloped frontal sinuses ^a
6	14 skulls	4 sinuses	0	16 sinuses	8 sinuses	Does not support frontal sinus underdevelopment in skulls with metopism ^b
7	50 skulls	17 sinuses	(Mean frontal sinus width: 46.57 ±14.27)*			Metopism significantly manifested with underdeveloped frontal sinuses ^a

*#1-7: Studies referencing number (Table 1); Study #6 originally had 17 skulls with metopism, but one was not radiographically assessed because of destruction; equal letters after the highlight statements show converging opinions; *: studies that did not fit exactly within the classification of aplasia, hypoplasia, medium and hyperplasia; **: aplasia based on both sides. Source: Authors.*

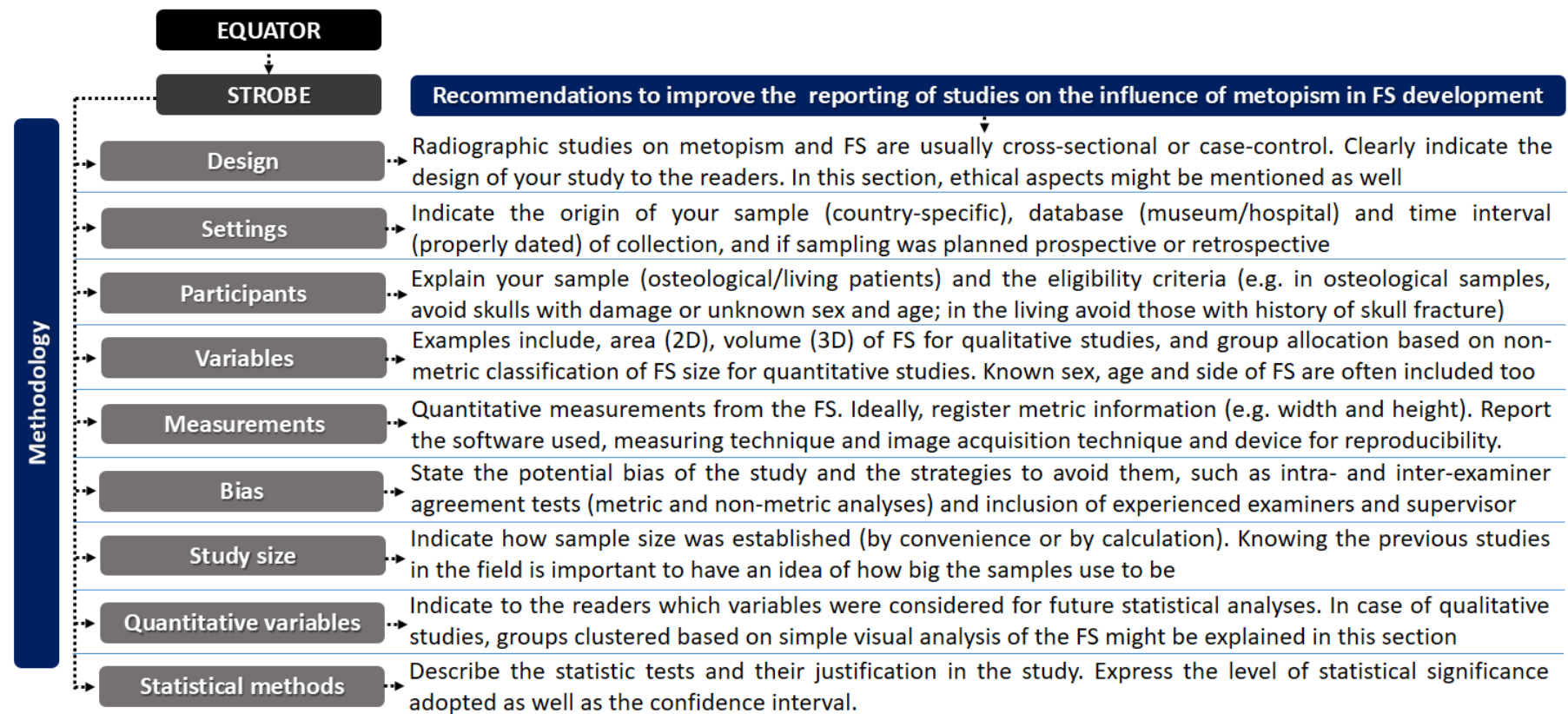
3.3 Risk of Bias of Eligible Studies

Three studies reached low risk of bias with 100% of positive answers (Guerram et al., 2014; Sandre e ta l., 2017; Nikolova et al., 2018), two studies reached low risk of bias with 75% of positive answers (Nikolova et al., 2016; Nikolova & Toneva, 2019) and two studies had high risk of bias with 37.5% of positive answers (Marciniak & Nizankowski, 1959; Bilgin et al., 2013) (Table 5). Based on the limitations found within each manuscript, recommendations for the improvement and standardization of reporting methods and outcomes were established (Figure 2).

Table 5 – Outcomes of the assessment of the risk of bias within eligible studies.

Authors	Q1	Q2	Q3	Q4	Q5	Q6	Q7	Q8	%	Risk
Marciniak et al., ³² 1959	Yes	Yes	U	U	No	No	U	Yes	37.5	High
Bilgin et al., ³³ 2013	No	Yes	Yes	No	No	No	U	Yes	37.5	High
Guerram et al., ³⁴ 2014	Yes	Yes	Yes	Yes	Yes	Yes	Yes	Yes	100	Low
Nikolova et al., ³⁵ 2016	Yes	Yes	Yes	Yes	No	No	Yes	Yes	75	Low
Nikolova et al., ³⁶ 2018	Yes	Yes	Yes	Yes	Yes	Yes	Yes	Yes	100	Low
Sandre et al., ³⁷ 2017	Yes	Yes	Yes	Yes	Yes	Yes	Yes	Yes	100	Low
Nikolova et al., ³⁸ 2019	Yes	Yes	Yes	Yes	No	No	Yes	Yes	75	Low

Q1) Were the criteria for inclusion in the sample clearly defined? Q2) Were the study subjects and the setting described in detail? Q3) Was the exposure measured in a valid and reliable way? Q4) Were objective, standard criteria used for measurement of the condition? Q5) Were confounding factors identified? Q6) Were strategies to deal with confounding factors stated? Q7) Were the outcomes measured in a valid and reliable way? Q8) Was appropriate statistical analysis used? U: uncertain. Source: Authors.



.....
 Based on *Enhancing the Quality and Transparency of Health Research (EQUATOR)*³⁰
 Based on *Strengthening the Reporting of Observational Studies in Epidemiology (STROBE)*³¹

4. Discussion

The uncertainty surrounding the influence of metopism (persistent metopic suture in adults) in the abnormal development of the frontal sinuses dates at least from 61 years ago (Marciniak & Nizankowski, 1959). Without clear answers in the scientific literature, this systematic review compiled the available information from articles filtered based on eligibility in order to contribute to the improvement of current knowledge.

Seven studies emerged as eligible after inclusion and exclusion criteria and deep reading of titles, abstract and full-texts. Other studies that previously appeared in reference lists of the eligible studies were not included for reasons registered in Appendix I. Some of the articles not included were not exclusively dedicated to investigate frontal sinus development in metopic individuals/skulls (Torgersen, 1950; Baaten et al., 2003) – in other words, they did not establish the influence of MS in FS as primary topic and outcome of interest. The inclusion of these articles would lead to extracted and tabulated data with too many gaps and missing information. Consequently, their risk of bias (for not properly fitting to the eligibility criteria) would be high and known beforehand – justifying their exclusion. It is important to note that some studies related to frontal sinus (Welcker, 1862; Rochlin & Rubaschewa, 1934; Monteiro et al., 1957) were detected from the reference lists of eligible articles (Nikolova et al., 2016) – however, they were excluded firstly based on language of publication. Another study was filtered out because it was not found full-text (Monteiro & Ramos, 1953) (the unsuccessful dedicated search for the full-text version was documented). Discussing these methodological decisions is essential to clarify this study and point out the way taken for selecting the ideal studies.

The sample, as depicted in this review, was divided into skulls from living and skulls from osteological collections. The strategies to acquire images from both types of samples were retrospective or prospective. The first is ideally designed for the living in order to avoid the exposure to ionizing radiation exclusively for research. Hence, retrospectively revisiting image databases with radiographs, and CT and MRI scans previously taken for therapeutic (diagnostic, intraoperative and follow-up) purposes is a feasible strategy. The second is commonly addressed in forensic osteological collections, in which radiographs are prospectively taken from the skulls. All the eligible studies designed sampling under ethical protocols (not exposing the living to radiation for morphological analysis of the FS). It is important to note, that the used collections were contemporary. So, the anatomy of the human skulls were all from modern humans. Additionally, most of the studies adults. This is an

important methodological aspect in order to reduce the bias of including individuals in which MS is not yet persistent, such as in young childhood. Currently, it is known that MS might close before the first year of life (Vu et al., 2001). However, some authors say that it may extend up to the first eight years after birth (Vikram et al., 2014). Picking adults guarantees a proper margin to safely sampling skulls with persistent MS.

Radiographic assessment of the FS was a pre-requisite to inclusion in this review. Despite recently published (85.7% during 2013-2019), most of the studies used bidimensional analysis of the frontal sinuses via plain radiography. This type of analysis was very heterogeneous for the chosen X-ray projection and device settings. Ideally, posteroanterior (PA) projections would enable a proper visualization of the region of interest, especially in Caldwell's views. Previous studies used PA techniques even for metric analysis of the FS (Rubira-Bullen et al., 2010; Silva et al., 2019). When it comes to metric or non-metric analysis, this review shows that only three studies performed linear measurements of the frontal sinuses in a quantitative scenario. These analyses enable a completely different set of statistical tests and maybe a deeper look into the influence of metopism in FS development. More accurate measurements, however, are achieved with computed tomography or any image modality that allows three-dimensional navigation resizing proportions and distances 1:1. The two studies that used computed tomography as image modality to assess the FS diverged in relation to their final opinion – one pointed to a trend of metopism manifesting in skull with underdeveloped FS (Sandre et al., 2017), while the other did not find evidence to support the influence of metopism in underdeveloped sinuses (Bilgin et al., 2013).

Finding out whether or not metopism affects FS development was the core purpose of this systematic literature review. The four studies that presented outcomes relating metopism with underdeveloped FS (not considering overlapping samples) had low risk of bias (two of them with 100% score). In the other hand, two out of the three studies that found opposite outcomes had high risk of bias (with score 37.5%) and the only study with low risk of bias had the smallest sample among the eligible studies (Sandre et al. 2017). In general, the studies that related metopism and FS alterations indicated first hypoplasia as the most common alteration, followed by aplasia. A drawback, however, emerges because sex information might naturally influence on the size of FS, which may be smaller in females. Specific analysis of FS and metopism based on sex were hampered because detailed information were not clearly described among studies. In order to cluster individuals within groups based on size, the studies must establish techniques for the proper classification. Among the qualitative analyses, Guerram's approach was the most used, while Ribeiro's approach enabled most of

the quantitative analyses. These techniques were originally designed for 2D analyses in radiographs. Validation in 3D scenarios could be interesting to translate their approach to more contemporary image modalities. In practice, the 3D analysis of FS would contribute to a multiplanar view of their pneumatization – which may extend along the vertical and horizontal plates of the frontal bone (Nikolova et al., 2018). Although expressing clinical manifestations very discretely, metopism may play a role in determining the morphology (outline) of the skull. Understanding if this phenomenon has influence over FS development is part of the anatomical study of the human skull. In order to improve future studies, the present review suggests a few recommendations for reporting methods on the investigation of the influence of metopism in FS development.

The methodological variances among the studies led to the recommendation of reporting guidelines based on well-known scientific standards, namely EQUATOR and STROBE. These guidelines were designed to enable homogeneity in future studies. Most of the studies in this systematic literature review did not report study design (e.g. experimental or observational, subdividing). Ethical approval was mentioned in the text of a single study (Sandre et al. 2017). Eligibility criteria for sampling was clearly defined in most of the studies but not necessarily in detail. Date of sample and interval of data collection were poorly reported, as well as the rationale behind sample size (e.g. calculation vs. convenience). Examiner reproducibility training, calibration and testing was mentioned in three studies only and shortly described – it is essential not only in metric studies but also for the allocation of FS based on size groups. Evidently, authors have the autonomy to design their own articles, but it is the duty of the present study to point out best practices to replace the existing limitations. Based on the exposed, future studies are encouraged to be carried out in a systematic and standardized way so better comparisons (eventually by means of meta-analysis) can be accomplished.

5. Final Considerations

Outcomes of the scientific literature dedicated to verify the possible influence of metopism in FS development via radiographic analysis varied among eligible studies. Data reported among studies were heterogeneous and hampered comparative and inferential analyses. Lower risk of bias was weighted in favor of studies that support a tendency of metopism in skulls with underdeveloped FS. Primary original studies with standardized protocol for reporting methods and results are encouraged to enable optimal and clear data extraction in

the future.

References

Aksu, F., Cirpan, S., Mas, N. G., Karabekir, S., & Magden, A. O. (2014). Anatomic features of metopic suture in adult dry skulls. *J Craniofac Surg*, 25(3), 1044-1046. <http://doi.org/10.1097/SCS.0000000000000564>.

Baaten, P. J. J., Haddad, M., Abi-Nader, K., Abi-Ghosn, A., Al-Kutoubi, A., & Jurjus, A. R. (2003). Incidence of metopism in the Lebanese population. *Clin Anat* 16(2), 148-151, <http://doi.org/10.1002/ca.10050>.

Bademci, G., Kendi, T., & Agalar, F. (2007). Persistent metopic suture can mimic the skull fractures in the emergency setting? *Neurocirugia*, 18(3), 238-240.

Beaini, T. L., Duailibi-Neto, E. F., Chilvarquer, I., & Melani RF. (2015). Human identification through frontal sinus 3D superimposition: pilot study with cone beam computer tomography. *J Forensic Legal Med*, 36, 63-69, <http://doi.org/10.1016/j.jflm.2015.09.003>.

Bilgin, S., Kantarcı, U. H., Duymus, M., Yildirim, C. H., Ercakmak, B., Orman, G. et al. (2013) Association between frontal sinus development and persistent metopic suture. *Folia Morphol*, 72(4), 306-310, <http://doi.org/10.5603/fm.2013.0051>.

Craigie, D. (1838). *Elements of anatomy, general, special, and comparative*. (7th ed.) Encyclopaedia Britannica, Chicago.

EQUATOR. (2020). Enhancing the quality and transparency of health research. Retrieved from <https://www.equator-network.org>.

Fahrioglu, S. L., & Andarolo, C. (2018). *Anatomy, head and neck, sinus function and development*. StatPearls Publishing, Treasure Island.

Furtado, C., Pompeo, D. D., Furtado, A., Paranhos, L. R., Franco, A., & Rivera, L. M. L. (2018). Lack of significant volumetric alteration after rapid maxillary expansion supports the

use of frontal sinuses for human identification purposes. *J Forensic Radiol Imag*, 12, 64-67, <http://doi.org/10.1016/j.jofri.2018.02.008>.

Guerram, A., Le Minor, J. M., Renger, S., & Bierry, G. (2014). Brief communication: the size of the human frontal sinuses in adults presenting complete persistence of the metopic suture. *Am J Phys Anthropol*, 154(4), 621-627, <http://doi.org/10.1002/ajpa.22532>.

Higgins, J. P. T., & Green, S. (2011). *Cochrane handbook for systematic reviews of interventions version*. The Cochrane Collaboration, London.

Lipsett, B. J., & Steanson, K. (2019). *Anatomy, head and neck, fontanelles*. StatPearls Publishing, Treasure Island.

Marciniak, R., & Nizankowski, C. (1959). Metopism and its correlation with frontal sinuses. *Acta Radiol*, 51, 343-352, <http://doi.org/10.3109/00016925909171105>.

Miura, T., Perlyn, C. A., Kinboshi, M., Ogihara, N., Kobayashi-Miura, M., Morriss-Kay, G. M., & Shiota, K. (2009). Mechanism of skull suture maintenance and interdigitation. *J Anat*, 215(6), 642-655, <http://doi.org/10.1111/j.1469-7580.2009.01148.x>.

Moher, D., Shamseer, L., Clarke, M., Ghersi, D., Liberati, A., Petticrew, M., et al. (2015). Preferred reporting items for systematic review and meta-analysis protocols (PRISMA-P) 2015 statement. *Syst Rev*, 4, 1, <http://doi.org/10.1186/2046-4053-4-1>.

Monteiro, H., & Ramos, A. (1953). Metopismo e seios frontais. *Acta Iber Radiol Cancerol*, 2, 57-61.

Monteiro, H., Pinto, S., Ramos, A., & Tavares, A. S. (1957). Aspects morphologiques des sinus para-nasaux. *Acta Anatomy*, 30, 508-522.

Moore, K. L., Dalley, A. F., & Agur, A. M. R. (2017). *Clinically oriented anatomy*. (8th ed.) Lippincott Williams and Wilkins, Philadelphia.

Munn, Z., Moola, S., Lisy, K., Riitano, D., & Tufanaru, C. (2015). Methodological guidance for systematic reviews of observational epidemiological studies reporting prevalence and cumulative incidence data. *Int J Evid Based Healthc*, 13(3), 147-153, <http://doi.org/10.1097/XEB.0000000000000054>.

Nelke, K. H., Pawlak, W., Kurlej, W., & Gerber, H. (2014). Metopic frontal suture in a patient with severe dentofacial deformity undergoing bimaxillary surgery. *J Craniofac Surg*, 25(2), 517-518. <http://doi.org/10.1097/SCS.0000000000000681>.

Nikolova, S., & Toneva, D. (2019). Frontal sinus dimensions in the presence of persistent metopic suture. *Acta Morphol Anthropol*, 26, 90-96.

Nikolova, S., Toneva, D., & Georgiev, I. (2016). A persistent metopic suture – incidence and influence on the frontal sinus development (preliminary data). *Acta Morphol Anthropol*, 23, 85-92.

Nikolova, S., Toneva, D., Georgiev, I., & Lazarov, N. (2018). Relation between metopic suture persistence and frontal sinus development. *InTech Open [epud]* <http://doi.org/10.5772/intechopen.79376>.

Nikolova, S., Toneva, D., Georgiev, I., Lazarov, N. (2018). Digital radiomorphometric analysis of the frontal sinus and assessment of the relation between persistent metopic suture and frontal sinus development. *Am J Forensic Anthropol* 165(3), 492-506, <http://doi.org/10.1002/ajpa.23375>.

Pereira, A. S., Shitsuka, D. M., Ferreira, F. J., Shitsuka, R. (2018). *Metodologia da pesquisa científica*, Santa Maria Federal University Press, Santa Maria.

Rawlani, S., & Rawlani, S. (2013). *Textbook of general anatomy*. 2nd ed. Jaypee Brothers Med Pub Ltd, London.

Ribeiro, F. A. (2000). Standardized measurements of radiographic films of the frontal sinuses: an aid to identifying unknown persons. *Ear Nose Throat J*, 79, 26-8, 30,32-33. <http://doi.org/10.1177/014556130007900108>.

Rochlin, D. G., Rubaschewa, A. (1934). Zum problem des metopismus, *Z Menschl Vererb Konstitutionsl*, 18, 339-348.

Rubira-Bullen, I. R. F., Rubira, C. M. F., Sarmiento, V. A., & Azevedo, R. A. (2010). Frontal sinus size on facial plain radiographs. *J Morphol Sci*, 27, 77-81.

Sahlstrand-Johnson, P., Jannert, M., Strömbeck, A., & Abul-Kasim, K. (2011). Computed tomography measurements of different dimensions of maxillary and frontal sinuses. *BMC Med Imaging*, 11, 8, <http://doi.org/10.1186/1471-2342-11-8>.

Sandre, L. B., Mundim-Picoli, M. B. V., Picoli, F. F., Rodrigues, L. G., Bueno, J. M., & Silva, R. F. (2017). Prevalence of agenesis of frontal sinus in human skulls with metopism. *J Forensic Odonto-Stomatol* 35, 20-27.

Schünke, M., Schulte, E., & Schumacher, U. (2014). *Prometheus LernAtlas der Anatomie*. (4th ed.), Georg Thieme Verlag KG, Stuttgart.

Silva, R. F., Franco, A., Dias, P. E. M., Gonçalves, A. S., Paranhos, L. R. (2013). Interrelationship between forensic radiology and forensic Odontology – a case report of identified skeletal remains. *J Forensic Radiol Imag*, 4(1), 201-206, <https://doi.org/10.1016/j.jofri.2013.06.005>.

Silva, R. F., Picoli, F. F., Botelho, T. L., Resende, R. G., & Franco, A. (2017). Forensic identification of decomposed human body through comparison between ante-mortem and post-mortem CT images of frontal sinuses: case report. *Acta Stomatol Croat*, 51(3), 227-231, <http://doi.org/10.15644/asc51/3/6>.

Silva, R. F., Prado, F. B., Caputo, I. G., Devito, K. L., Botelho, T. L., & Daruge Júnior, E. (2009). The forensic importance of frontal sinus radiographs. *J Forensic Legal Med*, 16(1), 18-23, <http://doi.org/10.1016/j.jflm.2008.05.016>.

Silva, R. F., Rodrigues, L. G., Manica, S., Franco, R. P. A. V., & Franco, A. (2019). Human identification established by the analysis of frontal sinus seen in anteroposterior skull

radiographs using the mento-naso technique – a forensic case report. *Rev Bras Odontol Legal RBOL*, 6(1), 62-66, <http://doi.org/10.21117/rbol.v6i1.222>.

Silva, R. F., Rodrigues, L. G., Picoli, F. F., Bueno, J. M., Franco, R. P. A. V., & Franco, A. (2019). Morphological analysis of frontal sinuses registered in an occlusal film by intraoral radiographic device – a case report. *J Forensic Radiol Imag*, 17, 1-4, <http://doi.org/10.1016/j.jofri.2019.03.001>.

Silva, R. F., Vaz, C. G., Domiciano, M. L., Franco, A., Nunes, C. A. B. C. M., & Prado, M. M. (2014) Radiographic alterations of the frontal sinus morphology according to variations of the vertical angle in posteroanterior radiographs of the skull. *Acta Scient Health Sci*, 36(1), 113-117, <http://doi.org/10.4025/actascihealthsci.v36i1.20243>.

Silva, R., Pinto, R. N., Ferreira, G. M., & Daruge Júnior, E. (2008). Importance of frontal sinus radiographs for human identification. *Braz J Otorhinolaryngol*, 74(5), 798, <http://doi.org/10.1590/S0034-72992008000500027>.

Skrzat, J., Walocha, J., & Zawiliński, J. (2004). A note on the morphology of the metopic suture in the human skull. *Folia Morphol*, 63(4), 481-484.

STROBE. (2020). Strengthening the reporting of observational studies in epidemiology. Retrieved from <https://www.strobe-statement.org>.

Torgersen, J. (1950). A roentgenological study of the metopic suture. *Acta Radiol*, 33(1), 1-11.

Tortora, G. J., & Nielsen, M. T. (2017). *Principles of human anatomy*. (14th ed.), John Wiley & Sons Inc, Hoboken.

Vikram, S., Padubidri, J. R., & Dutt, A. R. (2014). A rare case of persistent metopic suture in an elderly individual: Incidental autopsy finding with clinical implications. *Arch Med Health Sci*, 2, 61-63, <http://doi.org/10.4103/2321-4848.133817>.

Vinchon, M. (2019). The metopic suture: Natural history. *Neurochirurgie*, 65(5), 239-245, <http://doi.org/10.1016/j.neuchi.2019.09.006>.

Vu, H. L., Panchal, J., Parker, E. E., Levine, N. S., & Francel, P. (2001). The timing of physiologic closure of the metopic suture: a review of 159 patients using reconstructed 3D CT scans of the craniofacial region. *J Craniofac Surg*, 12(6), 527-532, <http://doi.org/10.1097/00001665-200111000-00005>.

Welcker, H. (1862). *Untersuchungen über wachstum und bau des menschlichen schädels. Allgemeine verhältnisse des schädelwachstums und schädelbaues. Normaler schädel deutschen stammes.* Engelmann, Leipzig.

Zdilla, M. J., Russell, M. L., Koons, A. W., Bliss, K. N., & Mangus, K. R. (2018). Metopism: a study of the persistent metopic suture. *J Craniofac Surg*, 29(1), 204-208, <http://doi.org/10.1097/SCS.0000000000004030>.

Percentage of contribution of each author in the manuscript

Raquel Porto Alegre Valente Franco – 25%

Ademir Franco – 20%

Maria de Pádua Fernandes – 20%

Adriele Alves Pinheiro – 15%

Ricardo Henrique Alves da Silva – 20%