

**Actinic cheilitis in a cardiac inpatient at intensive care unit: a case report**

**Queilite actínica em paciente cardíaco internado em unidade de terapia intensiva: relato de caso**

**Queilitis actínica en un paciente cardíaco ingresado en una unidad de cuidados intensivos: reporte de un caso**

Received: 10/16/2020 | Reviewed: 10/19/2020 | Accept: 10/25/2020 | Published: 10/25/2020

**Maria do Carmo Pessoa Nogueira Serrão**

ORCID: <https://orcid.org/0000-0002-0500-7485>

Hospital Metropolitano Dom José Maria Pires, Brasil

E-mail: [carminha11@hotmail.com](mailto:carminha11@hotmail.com)

**Thamires Pereira Gomes**

ORCID: <https://orcid.org/0000-0001-7208-8134>

Hospital Metropolitano Dom José Maria Pires, Brasil

E-mail: [thamipereira@hotmail.com](mailto:thamipereira@hotmail.com)

**Andreia Medeiros Rodrigues Cardoso**

ORCID: <https://orcid.org/0000-0002-2682-1048>

Hospital Metropolitano Dom José Maria Pires, Brasil

E-mail: [andreiamedeiros29@yahoo.com.br](mailto:andreiamedeiros29@yahoo.com.br)

**Ana Karla Rodrigues Costa Araújo**

ORCID: <https://orcid.org/0000-0003-2096-6016>

Hospital Metropolitano Dom José Maria Pires, Brasil

E-mail: [dra.anakarlarodrigues@gmail.com](mailto:dra.anakarlarodrigues@gmail.com)

**Mario Toscano de Brito Filho**

ORCID: <https://orcid.org/0000-0003-3323-0315>

Hospital Metropolitano Dom José Maria Pires, Brasil

E-mail: [mtoscano57@gmail.com](mailto:mtoscano57@gmail.com)

**Gilberto Costa Teodósio**

ORCID: <https://orcid.org/0000-0002-5200-4658>

Hospital Metropolitano Dom José Maria Pires, Brasil

E-mail: [gte\\_od@hotmail.com](mailto:gte_od@hotmail.com)

**Bruno da Silva Brito**

ORCID: <https://orcid.org/0000-0001-5040-997X>

Hospital Metropolitano Dom José Maria Pires, Brasil

E-mail: [brunosilvabrito@hotmail.com](mailto:brunosilvabrito@hotmail.com)

**Alessandro Elery Ramos**

ORCID: <https://orcid.org/0000-0002-5260-4071>

Hospital de Emergência e Trauma Senador Humberto Lucena, Brasil

E-mail: [baruck.3@hotmail.com](mailto:baruck.3@hotmail.com)

**Daniel Furtado Silva**

ORCID: <https://orcid.org/0000-0003-3319-2996>

Universidade Federal da Paraíba, Brasil

E-mail: [furtado.ds@gmail.com](mailto:furtado.ds@gmail.com)

**Ana Carolina Lyra de Albuquerque**

ORCID: <https://orcid.org/0000-0002-6532-5020>

Universidade Federal de Campina Grande, Brasil

E-mail: [lina.lyra@gmail.com](mailto:lina.lyra@gmail.com)

**Fernando Martins Baeder**

ORCID: <https://orcid.org/0000-0001-7101-5689>

Universidade Cruzeiro do Sul, Brasil

E-mail: [fernandobaeder@uol.com.br](mailto:fernandobaeder@uol.com.br)

**Abstract**

Actinic cheilitis (AC) is a oral disorder potentially malignant with dysplastic proliferations of keratinocytes. The lesion has a predilection for the red zone of the lower lip and may be closely related to excessive exposure to sunlight. The aim of this study was to report a clinical case of AC in a cardiac patient, admitted to the intensive care unit. Male patient, leucoderma, 82 years old, with a whitish lesion on the red zone of the lower lip, pedicled and sessile areas, well-marked limits and irregular shape. The incisional biopsy was performed in the intensive care unit bed and sent to the laboratory of pathological analysis in the State of Paraíba (LACEN). Microscopy showed an epidermis thickened by acanthosis, with cells showing nuclear pleomorphism and hyperchromism. In the dermis, the presence of vascular ectasia, diffuse lymphocytic infiltrate and basophilic degeneration of elastic fibers, areas with foci of superficial erosion of the lining epithelium covered by a crust of necrotic and

fibrinoleucocytic material were also observed. The anatomopathological diagnosis was ulcerated actinic cheilitis. The treatment performed was total surgical excision with monitoring of the healing process until the patient's hospital discharge. It was concluded that the treatment proposed to the patient was decisive. Also the presence of the dentist in a hospital environment facilitated the access and treatment of a oral disorder potentially malignant, favoring the prognosis of the case.

**Keywords:** Actinic cheilosis; Dentistry hospital unit; Hospital assistance.

### Resumo

A Queilite Actínica (QA) é uma desordem oral potencialmente maligna com proliferações displásicas de queratinócitos. A lesão tem predileção pela zona vermelha do lábio inferior e pode estar intimamente relacionada com exposição excessiva à luz solar. O objetivo deste estudo foi de relatar um caso clínico de QA em paciente cardiopata, internado em unidade de terapia intensiva. Paciente do sexo masculino, leucoderma, 82 anos, com lesão na zona vermelha do lábio inferior de cor esbranquiçada, áreas pediculadas e sésseis, limites nítidos e formato irregular. A biópsia incisional foi realizada em leito da unidade de terapia intensiva e enviada ao laboratório de análise patológica do Estado da Paraíba (LACEN). A microscopia apresentou uma epiderme espessada por acantose, com células apresentando pleomorfismo e hiperchromismo nuclear. Na derme presença de ectasia vascular, infiltrado linfocitário difuso e degeneração basófila de fibras elásticas, ainda foram observadas áreas com focos de erosão superficial do epitélio do revestimento recobertos por crosta de material necrótico e fibrinoleucocitário. O diagnóstico anatomopatológico foi de queilite actínica ulcerada. O tratamento realizado foi a excisão cirúrgica total com acompanhamento do processo de cicatrização até a alta hospitalar do paciente. Concluiu-se que o tratamento proposto ao paciente foi resolutivo e que a presença do cirurgião dentista em ambiente hospitalar facilitou o acesso e tratamento de uma desordem oral potencialmente maligna, favorecendo o prognóstico do caso.

**Palavras-chave:** Queilose actínica; Unidade hospitalar de odontologia; Assistência hospitalar.

### Resumen

La queilitis actínica (QA) es un trastorno oral potencialmente maligno con proliferaciones displásicas de queratinocitos. La lesión tiene predilección por la zona roja del labio inferior y puede estar estrechamente relacionada con la exposición excesiva a la luz solar. El objetivo de este estudio fue reportar un caso clínico de QA en un paciente cardíaco ingresado en la unidad

de cuidados intensivos. Paciente masculino, leucodermia, 82 años, con lesión blanquecina en zona roja del labio inferior, zonas pediculadas y sésiles, bordes afilados y forma irregular. La biopsia incisional se realizó en la cama de la unidad de cuidados intensivos y se envió al laboratorio de análisis patológico en el Estado de Paraíba (LACEN). La microscopía mostró una epidermis engrosada por acantosis, con células con pleomorfismo nuclear e hiperchromismo. En la dermis también se observó la presencia de ectasia vascular, infiltrado linfocítico difuso y degeneración basófila de fibras elásticas, áreas con focos de erosión superficial del epitelio de revestimiento recubierto por una costra de material necrótico y fibrinoleucocítico. El diagnóstico anatomopatológico fue queilitis actínica ulcerada. El tratamiento realizado fue la exéresis quirúrgica total con seguimiento del proceso de cicatrización hasta el alta hospitalaria del paciente. Se concluyó que el tratamiento propuesto al paciente fue determinante y que la presencia del odontólogo en un entorno hospitalario facilitó el acceso y tratamiento de un trastorno oral potencialmente maligno, favoreciendo el pronóstico del caso.

**Palabras clave:** Queilosis actínica; Unidad hospitalaria de odontología; Asistencia hospitalaria.

## 1. Introduction

Actinic cheilitis (AC) or actinic cheilitis is a lesion that has dysplastic proliferations of keratinocytes, also known as actinic keratosis of the lip, due to prolonged and continuous exposure to solar radiation, specifically to ultraviolet radiation, preferentially affecting the lower lip according to its anatomy and has been reported as a potentially malignant oral disorder (Mello, Melo, Modolo & Rivero, 2019). Smoking is the most predisposing factor related to its etiopathogenesis (Reinehr & Bakos, 2019). The AC affects, preferably, fair-skinned men and with age between 40 and 80 years old (Lucio & Barreto, 2012). The longer the time of sun exposure, the greater the number of individuals with AC and the severity of the injuries. The most common clinical changes were roughness, flaking, cracking, color changes and dryness (Miranda, Ferrari & Calandro, 2011).

The records of global AC occurrence reported in the scientific literature vary between 4.6 to 43.2% (Campisi & Margiotta, 2001; Lucena, Costa, Silveira & Lima, 2012; Martins-Filho, Silva & Piva, 2011; Rodríguez-Blanco et al., 2018). Also, a recent meta-analysis reporting studies with histopathological diagnosis of AC evidenced a prevalence of AC at 2.08% (Mello et al., 2018). Therefore, according to a study by Miranda, Ferrari and Calandro

conducted in 2011, nearly 95% of lip squamous cell carcinoma (LSCC) diagnosed cases may be preceded by AC.

Clinically, AC lesions on the lips show white spots or plaques, erythematous areas, swelling, loss of definition of the dividing line between the skin and the red area of the lip, wrinkling, peeling, symptoms of dryness and burning (Delgado, 2013), it can also be characterized by the elevation of the lower lip to the commissure, changes in color and loss of elasticity (Tenorio, Santos, Ferreira, Peixoto & Ribeiro, 2018). In some cases, it is possible to observe erosions. There are also other changes, such as erythema, hyperkeratosis, crusts and areas of atrophy (Martins, Marques, Martins, Bussadori & Fernandes, 2007).

The main changes in histopathology are atypical keratinocytes, hyperkeratosis, parakeratosis, covering especially atypical keratinocytes, lichenoid or perivascular lymphocytes and elastosis (Segatto, Dornelles, Silveira & Frantz, 2013).

The differential diagnosis is necessary among the multiplicity of dermatoses, whether of benign or malignant neoplastic nature. Different lesions can simulate skin cancer, due to the purely unusual aspect, that is, unusual, the abnormal evolution or to the unusual histopathological aspects such as hyper-brownness, numerous mitoses and some atypias (Vilela, 2011).

Hospital Dentistry can be understood by taking care of oral changes that require interventions by multidisciplinary teams in patient care in tertiary healthcare units. Dentistry integrated to the hospital allows better performance in the commitment of an integral care to the patient and can extend oral health care to the population (Aranega et al., 2012).

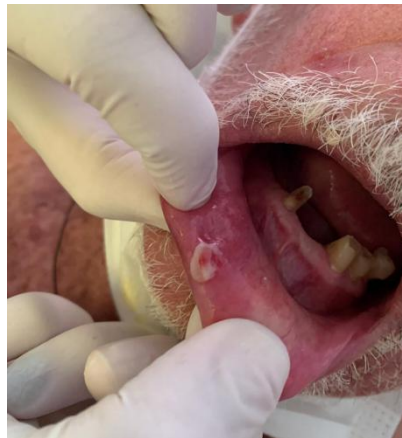The dental surgeon in a hospital environment works in different sectors, including the Intensive Care Unit (ICU), performing actions of promotion, diagnosis, planning, treatment, recovery of oral health in order to improve the patient's health and quality of life. In this sense, further clarifications about oral care performed in the hospital environment by dentists need to be disclosed to guide the programs and actions of these professionals and hospital management (Blum, Silva, Baeder & Bona, 2018).

Thus, the objective of this study was to report the clinical treatment protocol for Actinic Cheilitis in the lower lip of an elderly patient, with heart disease and admitted to the cardiology ICU of the Hospital Metropolitan Dom José Maria Pires located in the city of Santa Rita-PB.

## 2. Case Report

Male patient, 82 years old, brown, farmer and intern at the Cardiology ICU of the Hospital Metropolitano Dom José Maria Pires located in the city of Santa Rita-PB, was attended by the Dentistry team of the referred Hospital, during the routine visit. The patient presented as a pre-existing underlying disease coronary artery disease, systemic arterial hypertension and dyslipidemia, with previous history of myocardial revascularization surgery. In the clinical examination, carried out by the Dentistry team, a lesion on the lower lip on the right side was observed, with no history of symptoms, whitish in color, with raised edges, measuring approximately 2 centimeters in diameter, which at the touch detached from the lip mucosa, which one also had a sessile part (Figure 1).

**Figure 1** - Appearance of the lower lip lesion.



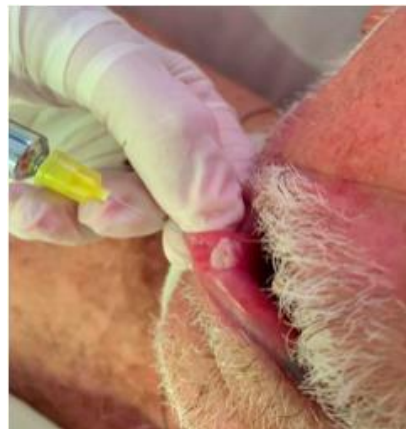Source: Own authorship.

The patient was conscious, oriented, breathing in room air, hemodynamically stable and using enoxaparin, acetyl salicylic acid and quetiapine.

In view of the presence of the lesion, the patient was informed and consented to perform the procedure, after issuing a favorable cardiological opinion. Thus, the Dentistry team at the hospital performed an incisional biopsy of the lesion in the ICU bed, after the analysis of hematological tests, whose presented favorable condition. The initial clinical diagnostic hypothesis was fibrous hyperplasia, with differential diagnosis of papilloma, due to investigation in the anamnesis. For anesthesia, 2% lidocaine anesthetic salt was administered with an adrenergic constricting vessel (1/100000) using a local infiltrative technique (Figure 2). After removing a fragment of the lesion with an elliptical incision also involving adjacent

tissue, cleaning and suturing with Nylon 4-0 thread was performed. After the surgery, the direct assistance team of the coronary ICU was instructed on how to maintain hygiene at the surgery site. The surgical specimen was conditioned in a container with 10% formaldehyde and sent for anatomopathological examination, whose diagnosis revealed ulcerated AC. The lesion presented an epidermis thickened by acanthosis on the slide, with cells showing nuclear pleomorphism and hyperchromism. The dermis presented vascular ectasia, diffuse lymphocytic infiltrate and basophilic degeneration of elastic fibers. Areas with foci of superficial erosion of the lining epithelium covered by a crust of necrotic and fibrinoleucocytic material were also observed.

**Figure 2** - Application of local anesthetic to perform biopsy.




Source: Own authorship.

Thereafter the anatomopathological diagnosis, a new surgical intervention was performed and the lesion was completely removed with an elliptical incision with 2mm safety margins on each edge and deep enough to remove the epithelial tissue and part of the adjacent connective tissue. Then irrigation, cleaning and suturing with Nylon 4-0 thread was performed. After the surgery, the direct assistance team of the coronary ICU was instructed to maintain the same hygiene at the surgery site as before. The lesion was completely removed and placed in a container with 10% formaldehyde and sent for novel anatomopathological examination (Figure 3), whose diagnosis confirmed ulcerated AC. Subsequently, the patient was monitored by the dental team, without complications, the suture was removed after 8 days, continuing the treatments inherent to his cardiac condition, and then he was discharged.



**Figure 3** - Piece removed and stored in formaldehyde.



Source: Own authorship.

### 3. Discussion

Paraíba is located in the Northeast region of Brazil, a region with a predominance of hot weather and high levels of ultraviolet radiation, which can increase the incidence of skin cancer as well as the occurrence of potentially malignant oral disorders such as AC, which presents as one of the etiological factors to excessive sun exposure. AC have the potential for malignant transformation, so, in view of the detection of suspicious lesions, one must intervene briefly, as reported in the present case, and must be studied, notified and monitored by the dental team. According to Miranda, Ferrari & Calandro (2011) and Silva et al. (2006), the longer the time of sun exposure the greater the severity of AC injuries. Therefore, early diagnosis is important to prevent the development of the disease. The actions of hospital dentistry in the diagnosis and early treatment contributed to reduce oral cancer risks.

Silva et al. (2020) reported a representative study which the objective to determine the frequency of AC and lip squamous cell carcinoma in a Brazilian population, describing clinicopathologic characteristics and sociodemographic data of these conditions. Their study highlighted the increase in the diagnosis of both conditions over the years, suggesting this fact occurs due to the improvement of access to dental services, as well as the increase of campaigns to prevent oral cancer, thus favoring the early diagnosis.

In this case, the patient lived in Paraíba, was a leucoderma, with 82 years old, male and farm worker. These characteristics corroborate the profile of patients with AC, according to the literature (Arnaud et al., 2014). The predominance of males can be justified by the fact



that many men work, for long periods, under sun exposure. In addition, women, when using lipstick, protect their lips against sunlight, preventing disease (Martins-Filho, Silva & Piva, 2011).

The authors reported the presence of AC lesions more frequently on the lower lip due to its anatomy and position, as this region is directly exposed to the incidence of sunlight and, consequently, ultraviolet radiation (Arnaud et al., 2014; Markopoulos, Albanidou-Farmaki & Kayavis, 2004). Also, AC presents a slow development associated with a lower potential of malignancy and aggression pattern when compared with other lesion, such as oral squamous cell carcinoma and intraoral erythroplakia (Dancyger et al., 2018). However, due to the slow process of malignant transformation and the asymptomatic nature, patients can often confuse AC with signs of aging, seeking treatment when the lesion is in an advanced stage, making diagnosis of AC lesions more difficult (Sarmiento, Miguel, Queiroz, Godoy & Silveira, 2014; Vieira, Minicucci, Marques & Marques, 2012).

AC is a potentially malignant oral disorder, with the possibility of progression to squamous cell carcinoma (SCC) in 6 to 10% of cases. Patients with AC should follow up after treatment with visits at least every six months for the first two years and annual skin checks after that. Some studies report cases that reach 95% of SCC on the lip, starting initially as AC. SCC on the lip is much more dangerous than other parts of the body, with 11% of SCC labial lesions metastasizing compared to 1% of SCC found in other anatomical sites (Muse & Crane, 2020).

Studies on pathogenesis and AC have already identified 89 genes associated with the progression of CA in SCC (Jadotte & Schwartz, 2012). The p53 protein is a transcription factor that regulates the checkpoint G1 of the cell cycle, being essential in the transformation of potentially malignant lesions. This protein is responsible for activating pro-apoptotic factors that induce programmed cell death when cells with irreparable genetic abnormalities are detected. This mechanism is able to inhibit the replication of abnormal cells and the consequent formation of a tumor. When UV radiation causes a mutation in the p53 gene, the protective action of that oncosuppressor gene is lost, allowing the replication of defective cells to occur. Ninety percent of SCC and 80% AC cases have specific UV mutations of the p53 gene. Thus, these mutations significantly increase the risk of transforming AC into SCC (Rass & Reichrath, 2008).

The diagnosis of the lesion consisted of anamnesis, physical examination and histopathological examination. In the anamnesis, demographic and occupational information, symptoms, time of onset of the lesion and associated risk factors were obtained. The physical

examination was important to identify the lesion changes and, thus, to formulate a hypothesis of initial clinical diagnosis as well as differential diagnosis, which in this case was fibrous hyperplasia, with differential diagnosis of papilloma, due to investigation in the anamnesis. The lesion had a clinical aspect extremely similar to the fibrous hyperplasia, whitish, with raised edges and pedicled base, making the diagnosis of ulcerated AC a surprise for the researchers involved.

The diagnosis of lesions in the oral cavity remains a challenge for hospital dentistry since patients do not only present oral lesions, but comorbidities that are often fatal and restrain proper treatment.

The promotion of oral adequacy, prevention of pain and hemorrhage, associated with early diagnosis with immediate treatment of oral lesions are the main objectives of hospital dentistry. Therefore, this study can contribute to the promotion of planning invasive interventions on inpatients at a hospital environment, improving the oral and general health of patients, and reinforces the importance of knowledge about AC and its adequate treatment by dental surgeons.

#### **4. Final Considerations**

This case report demonstrates the importance of dental surgeon presence in a hospital environment. Which further being able to contribute to the maintenance of the patient's health, in this case, was fundamentally important in the diagnosis of a potentially malignant oral disorder. In addition, this report highlights the necessity of further studies to assess the importance of the dentist's performance as an integral part of the hospital team, acting in the prevention and treatment of oral pathologies, and consequently contributing to systemic health care of the inpatient.

#### **References**

Aranega, A. M., Bassi, A. P. F., Ponzoni, D., Wayama, M. T., Esteves, J. C., & Garcia Junior, I. R. (2012). Qual a importância da Odontologia Hospitalar? *Rev Bras Odontol*, 69(1), 90-3.

Arnaud, R. R., Soares, M. S. M., Paiva, M. A. F., Figueiredo, C. R. L. V., Santos, M. G. C., & Lira, C. C. (2014). Queilite actínica: avaliação histopatológica de 44 casos. *Revista de Odontologia da UNESP*, 43(6), 384–389.

Blum, D. F. C., Silva, J. A. S., Baeder, F. M., Bona, A. D. (2018). The practice of dentistry in intensive care units in Brazil. *Rev Bras Ter Intensiva*, 30(3), 327-32.

Campisi, G., & Margiotta, V. (2001). Oral mucosal lesions and risk habits among men in a Italian study population. *J Oral Pathol Med*, 30, 22-8.

Dancyger, A., Heard, V., Huang, B., Suley, C., Tang, D., Ariyawardana, A., et al. (2018). Malignant transformation of actinic cheilitis: a systematic review of observational studies. *J Invest Clin Dent*, 9, e12343.

Delgado, A. M. (2013). Estudo imuno-histoquímico da queilite actínica, carcinoma epidermóide de lábio e carcinoma epidermóide de língua (Doctoral dissertation). Retrieved from Repositório Institucional UNESP.

Jadotte, Y. T., & Schwartz, R. A. (2012). Solar cheilosis: an ominous precursor: part I. diagnostic insights. *J Am Acad Dermatol*, 66, 173-84.

Lucena, E. E. S., Costa, D. C., Silveira, E. J., & Lima, K. C. (2012). Prevalence and factors associated to actinic cheilitis in beach workers. *Oral Dis*, 18, 575-9.

Lucio, P. S. C., & Barreto, R. C. (2012). Queilite actínica- perfil da produção científica em odontologia do Brasil nos últimos dez anos. *Rev Cub Estomatol*, 49(4), 276-85.

Markopoulos, A., Albanidou-Farmaki, E., & Kayavis, I. (2004). Actinic cheilitis: clinical and pathologic characteristics in 65 cases. *Oral diseases*, 10(4), 212–216.

Martins, M. D., Marques, L. O., Martins, M. A. T., Bussadori, S. K., & Fernandes, K. P. S. (2007). Queilite actínica: relato de caso clínico. *ConScientiae Saúde*, 6(1), 105-10.

Martins-Filho, P. R., Silva, L. C., & Piva, M. R. (2011). The prevalence of actinic cheilitis in farmers in a semi-arid northeastern region of Brazil. *International journal of dermatology*, 50(9), 1109–1114.

Mello, F. W., Melo, G., Modolo, F., & Rivero, E. R. (2019). Actinic cheilitis and lip squamous cell carcinoma: Literature review and new data from Brazil. *J Clin Exp Dent*, 11, 62-9.

Mello, F. W., Miguel, A. F. P., Dutra, K. L., Porporatti, A. L., Warnakulasuriya, S., Guerra, E. N. S., et al., (2018). Prevalence of oral potentially malignant disorders: a systematic review and meta-analysis. *J Oral Pathol Med*, 47, 633-40.

Miranda, A. M. O., Ferrari, T. M., & Calandro, T. L. L. (2011). Queilite actínica: aspectos clínicos e prevalência encontrados em uma população rural no interior do Brasil. *Rev Saúde e Pesquisa*, 4(1), 67-72.

Muse, M. E., & Crane, J. S. (2020). Actinic Cheilitis. In StatPearls. Retrieved from <https://www.ncbi.nlm.nih.gov/books/NBK551553/>

Rass, K., & Reichrath, J. (2008). UV damage and DNA repair in malignant melanoma and nonmelanoma skin cancer. In Reichrath (Ed.), *Advances in experimental medicine and biology: sunlight, vitamin D and skin cancer* (p. 167-68). New York. Springer Science.

Reinehr, C. P. H., & Bakos, R. M. (2019). Actinic keratoses: review of clinical, dermoscopic, and therapeutic aspects. *Anais Brasileiros de Dermatologia*, 94(6), 637-657.

Rodríguez-Blanco, I., Flórez, A., Paredes-Suárez, C., Rodríguez-Lojo, R., González-Vilas, D., Ramírez-Santos, A, et al. (2018). Actinic cheilitis prevalence and risk factors: a cross-sectional, multi-centre study in a population aged 45 years and over in north-west Spain. *Acta Derm Venereol*, 98, 970-4.

Sarmiento, D. J. S., Miguel, M. C. C., Queiroz, L. M., Godoy, G. P., & Silveira, E. J. (2014). Actinic cheilitis: clinicopathologic profile and association with degree of dysplasia. *Int J Dermatol*, 53, 466-72.

Segatto, M. M., Dornelles, S. I., Silveira, V. B., & Frantz, G. (2013). Comparative study of actinic keratosis treatment with 3% diclofenac sodium and 5% 5-fluorouracil. *Anais brasileiros de dermatologia*, 88(5), 732–738.

Silva, F. D., Daniel, F., Grando, L. J., Calvo, M., Rath, I. B., & Fabro, S. M. (2006). Estudo da prevalência de alterações labiais em pescadores da ilha de Santa Catarina. *Rev Odonto Ciência*, 21(51), 37-42.

Silva, L. V. O., Arruda, J. A. A., Abreu, L. G., Ferreira, R. C., Silva, L. P., Pelissari, C., et al. (2020). Demographic and clinicopathologic features os actinic cheilitis and lip squamous cell carcinoma: a brazilian multicentre study. *Head and Neck Pathology*, 10.1007/s12105-020-01142-2. Advance online publication.

Tenorio, E. P., Santos, J. A. P., Ferreira, S. M. S., Peixoto, F. B., & Ribeiro, C. M. B. (2018). Queilite actínica: relato de caso. *Rev Med Minas Gerais*, 28( e-1970), 1-6.

Vieira, R., Minicucci, E. M., Marques, M. E., & Marques, S. A. (2012). Actinic cheilitis and squamous cell carcinoma of the lip: clinical, histopathological and immunogenetic aspects. *An Bras Dermatol*, 87, 105-14.

Vilela, G. R. (2011). Queilite actinica: Revisao de literatura (Trabalho de Conclusão de Curso), Retrieved from <https://www.nescon.medicina.ufmg.br/biblioteca/imagem/6349.pdf>.

#### **Percentage of contribution of each author in the manuscript**

Maria do Carmo Pessoa Nogueira Serrão – 10%

Thamires Pereira Gomes – 10%

Andreia Medeiros Rodrigues Cardoso – 10%

Ana Karla Rodrigues Costa Araújo – 10%

Mario Toscano de Brito Filho – 10%

Gilberto Costa Teodósio – 10%

Bruno da Silva Brito – 10%

Alessandro Elery Ramos – 10%

Daniel Furtado Silva – 5%

Ana Carolina Lyra de Albuquerque – 5%

Fernando Martins Baeder – 10%