

Comparative evaluation between the “All on Four” and “Four on Pillars” techniques in 3D virtual planning associated with guided surgery on atrophic jaws

Avaliação comparativa entre as técnicas “All on Four” e “Four on Pillars” em planejamentos virtuais 3D associadas a cirurgias guiadas em maxilas atróficas

Evaluación comparativa entre las técnicas “All on Four” y “Four on Pillars” en la planificación virtual 3D asociada a la cirugía guiada de maxilares atróficos

Received: 10/19/2021 | Reviewed: 10/24/2021 | Accept: 10/25/2021 | Published: 10/28/2021

Marcelo do Lago Pimentel Maia

ORCID: <https://orcid.org/0000-0002-0227-1440>

Universidade Brasil, Brazil

E-mail: marcelomaia@isoradiologia.com.br

Daniel Souza Ferreira Magalhães

ORCID: <https://orcid.org/0000-0002-3761-1927>

Universidade Brasil, Brazil

E-mail: daniel.magalhaes@universidadebrasil.edu.br

Abstract

Thorough technical knowledge and anatomical understanding are critical for optimal surgical results. The difficulty of complete maxillary surgery can vary significantly depending on the complexity of the anatomy or bone defect. In this work, we analyze and compare two methods of software-guided planning for the manipulation of dental implants, associated with the All on Four (ALL) and Four on pillars (FOUR) techniques used in patients with atrophic maxillae. Forty-two images of totally edentulous patients were analyzed, and surgical planning was performed using both methods. The average area of the Four on pillars technique is 4.9x ($p < 0.0001$) greater than the average area of the All on four technique, this represents a difference of 489%. This means that, for the same force applied by the jaw, we will have a 4.9x smaller pressure, that is, a better distribution of forces on the jaws. It was not possible to notice a statistical difference between the success proportions ($p = 0.2542$), this means that both techniques have a non-different (similar) success proportion. We conclude that the area of the polygon formed in the Four on pillars surgical plan is larger than in the All on four plan and this results in significantly less pressure on the implants. We also concluded that it was not possible to notice a statistical difference between the proportions of success, which shows that there is no technique with successful performance advantages over the other.

Keywords: Bioengineering; Odontology; Dentistry; 3D surgical planning.

Resumo

Conhecimento técnico completo e entendimento anatômico são críticos para obter resultados cirúrgicos ideais. A dificuldade da cirurgia maxilar completa pode variar significativamente, dependendo da complexidade da anatomia ou defeito ósseo. Neste trabalho analisamos e comparamos dois métodos de planejamentos guiados em software de manipulação de implantes dentários, associados às técnicas All on Four (ALL) e Four on pillars (FOUR) utilizadas em pacientes com maxilas atróficas. Foram analisadas 42 imagens de pacientes desdentados totais a foi realizado o planejamento cirúrgico pelos dois métodos. A área média da técnica Four on pillars é 4,9x ($p < 0,0001$) maior que área média com a técnica All on four, isso representa uma diferença de 489%. Isto quer dizer que, para uma mesma força aplicada pelo maxilar teremos uma pressão 4,9x menor, ou seja, uma melhor distribuição de forças sobre as maxilas. Não foi possível notar diferença estatística entre as proporções de sucesso ($p = 0,2542$), isso quer dizer que ambas as técnicas possuem uma proporção de sucesso não-diferentes (semelhantes). Concluímos que a área do polígono formado no planejamento cirúrgico Four on pillars é maior que no planejamento All on four e isto resulta em uma pressão significativamente menor sobre os implantes. Concluímos também que não foi possível notar diferença estatística entre as proporções de sucesso, o que mostra que não existe uma técnica com vantagens de sucesso de realização em relação a outra.

Palavras-chave: Bioengenharia; Odontologia; Planejamento cirúrgico 3D.

Resumen

Un conocimiento técnico completo y una comprensión anatómica son fundamentales para obtener resultados quirúrgicos óptimos. La dificultad de la cirugía maxilar completa puede variar significativamente según la complejidad de la anatomía o el defecto óseo. En este trabajo analizamos y comparamos dos métodos de planificación guiada por

software para la manipulación de implantes dentales, asociados a las técnicas All on Four (ALL) y Four on pillars (FOUR) utilizadas en pacientes con maxilares atróficos. Se analizaron 42 imágenes de pacientes totalmente desdentados y se realizó la planificación quirúrgica con ambos métodos. El área promedio de la técnica Cuatro sobre pilares es 4.9x ($p < 0,0001$) mayor que el área promedio de la técnica Todos sobre cuatro, esto representa una diferencia del 489%. Esto significa que, para la misma fuerza aplicada por la mandíbula, tendremos una presión 4,9 veces menor, es decir, una mejor distribución de fuerzas sobre las mandíbulas. No fue posible notar una diferencia estadística entre las proporciones de éxito ($p = 0,2542$), esto significa que ambas técnicas tienen una proporción de éxito no diferente (similar). Concluimos que el área del cuadrilátero formado en el plan quirúrgico de Cuatro sobre pilares es mayor que en el plan Todo sobre cuatro y esto da como resultado una presión significativamente menor sobre los implantes. También concluimos que no fue posible notar una diferencia estadística entre las proporciones de éxito, lo que demuestra que no existe una técnica con ventajas de rendimiento exitoso sobre otra.

Palabras clave: Bioingeniería; Odontología; Planificación quirúrgica 3D.

1. Introduction

Thorough technical knowledge and anatomical understanding are critical for optimal surgical results. The difficulty of complete maxillary surgery can vary significantly depending on the complexity of the anatomy or bone defect. Historically, surgical training has been based on a learning model with progressive responses.

Fewer cases available, greater demand for safety and quality, and greater supervision resulted in a paradigm shift in surgical education. Computer surgical simulation can enhance the trainee experience in areas such as preoperative planning, skill acquisition and complication management. There is evidence that simulation, in its various forms, can provide clinical transferability for surgical procedures, techniques that require repeated exposure and integration of anatomical knowledge and psychomotor skills. Professionals who have undergone virtual planning training become more prepared than those who do not have this option (Tannyhill, & Jensen, 2019).

Guided surgery is currently a relevant option for bringing to the patient fewer surgical complications and is directly related to the 3d virtual planning for the success of the case. Guided implant surgery simplifies implant placement and generates optimal clinical outcomes. Digital implant planning allows for accurate diagnosis in which locations should be installed and allows a virtual visualization of the final prosthetic restoration. Additional clinical benefits include reduced surgical time and lower complication rate leading to greater patient acceptance and satisfaction (Al Yafi et al, 2019).

As for the professional's experience, virtual planning helps when the professional does not have much surgical experience, proving to be an important tool in dental implant surgeries. Therapy with oral implants has been performed by inexperienced dentists in eligible patients, after software planning based on cone beam computed tomography (CBCT). Two groups of patients were formed according to the surgical technique: guided and freehand implant placement and implant placement using surgical guides. After installing the implants in both techniques, the patients were again computed tomography (CT) scanned and the results were compared with the preoperative planning CT scans, and the 3D deviations were calculated. The junction of the tomographies was made using common anatomical points. Guided placement of the implant produced significantly smaller angular deviations compared to the freehand method (Alevizakos et al, 2019).

Although dental implants achieve high survival rates, the success of prosthetic therapy depends on an appropriate location for implant placement. Improperly positioned implants can damage vital structures such as nerves or vessels. In addition, proper placement of the implant can result in esthetics, biological repair minimizing complications and can act in an important way in cases where esthetics is a determining factor (Schneider et al, 2019).

The Branemark protocol technique for installing osseointegrated implants in edentulous maxillae is a common surgical/prosthetic procedure in the routine of dental clinics in general (Maló et al. 2003). And today, it has become one of the most viable methods of dental rehabilitation for the oral disabled patient, either because of its practicality, efficiency in the result of mastication and aesthetics, or because of the cost that was very high in the past and which today has become accessible to

majority of the population, for the improvement of new techniques, new materials, and equipment. The traditional way to make the perforations for the Branemark protocol is to perform an extensive opening of the maxillary flap with an incision made on the crest of the alveolar ridge, extending along the entire perimeter until reaching the maxillary tuber region. Wide vestibular and palatal displacement, releasing the gingiva and mucosa, with its periosteum showing all the maxillary bone included in the alveolar vestibule/palatine, even exposing the incisive foramen, according to the original technique described by Professor Branemark (Lund, & Wade, 1993). Despite being a daily dental technique, the major problem for the development of this technique is to have a favorable amount of bone, and it has an uncomfortable postoperative period. The All on Four (ALL) installation technique was developed and associated with guided planning and ended up being a favorable treatment option for these patients with atrophic maxillae, greatly facilitating the positioning of these implants, as well as the patient's postoperative period.

In Brazil, Smidt et al. (2018) first described the Four on Pillars technique. The technique consists of installing 4 implants in atrophic maxillae, two implants in the canine pillar's region and 2 implants in the pterygoid process region of the maxilla.

In this work we comparatively evaluate two surgical techniques, one taken as standard (ALL) and the other called Four on pillars (FOUR), comparing the areas formed by the implants in each case, which is directly related to the pressure applied to the jaws during the bite; and we compared the proportion of successful planning carried out in each technique in order to understand if any of them can be applied in more or less cases of atrophic jaws.

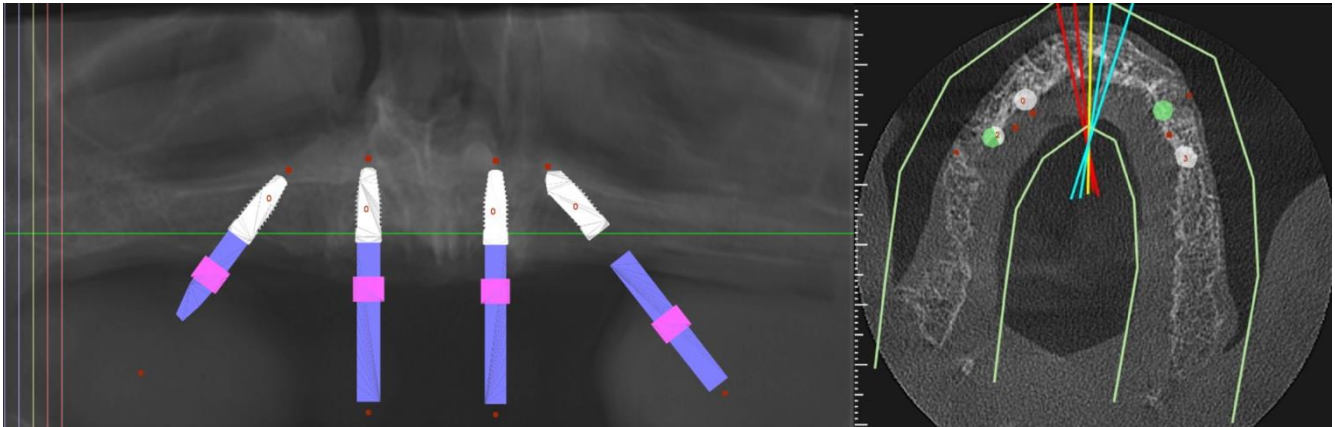
2. Methodology

For this work, 42 CT scans of maxillary edentulous people were evaluated. Exams were performed in 2019 at a radiological dental clinic in the city of Osasco, metropolitan region of São Paulo city. The analyzed images were obtained through CBTC scans of total edentulous maxillae, made in a dental scanner, brand Soredex, model Cranex 3D. This work was submitted and approved by the Ethics Committee of Universidade Brasil under approval number 4,652,975. All procedures performed in this study were in accordance with the ethical standards and with the 1964 Helsinki declaration and its later amendments.

In the planning carried out, dérig® implants (Dérig, 2021) were virtually installed, implants that appear in the Implant viewer software library (Implantviewer, 2021). 3.5 mm morse taper implants were used, models indicated for this technique. In each exam, both techniques were planned following the orientation of each of the groups: ALL and FOUR. All implants should have 100% bone tissue contact.

For the All on Four planning, the plans were carried out following the orientation of two implants in the canine pillars, more anteriorly and two more implants tangent to the anterior wall of the maxillary sinus (Siadat et al, 2018; Greenberg, 2017; Durkan, Oyar, & Deste, 2019; Soto-Penaloza et al., 2017). Figure 1 shows the All on four planning.

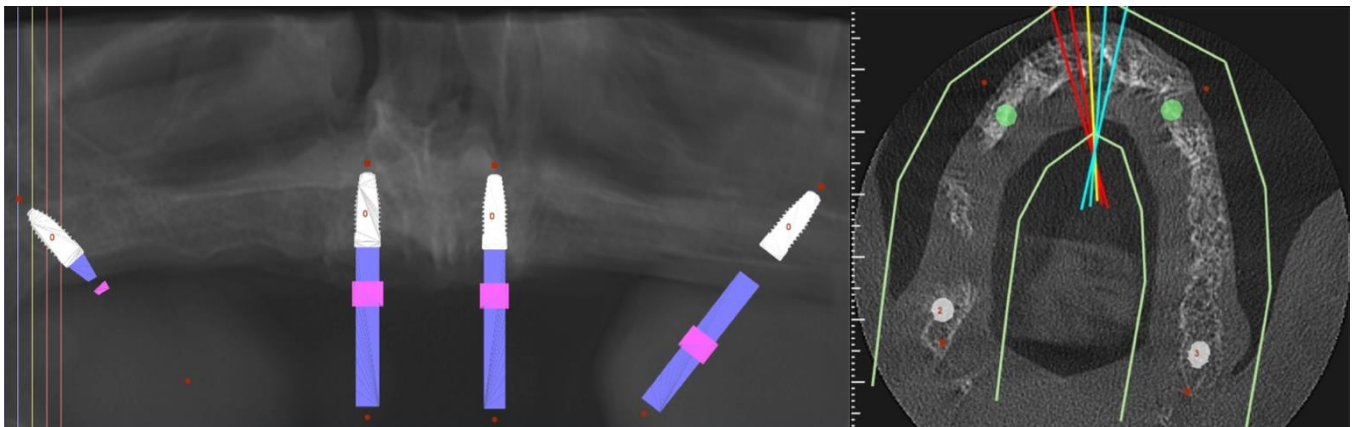
Figure 1. All on Four 3D planning.



Source: Authors.

For the Four on Pillars planning, the installation of the implants was virtually guided by two implants in the canine pillars and two more implants in the tuberosity region of the maxilla, anchoring the apex of the implant in the pterygoid process of the maxilla (Anandakrishna, & Rao, 2012; Peñarrocha, 2009; Balshi et al., 1995; Balshi et al., 1999). Figure 2 shows the Four on pillars plan.

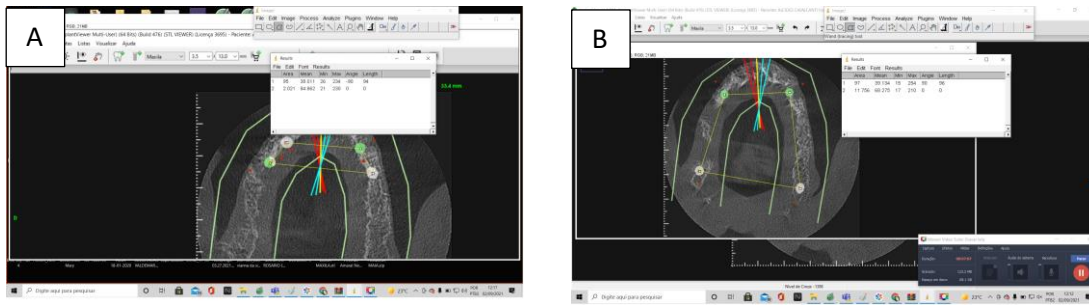
Figure 2. Four on pillars 3D planning.



Source: Authors.

To assess the area formed by the 4 implants (Figure 3), the area closest to the bone ridge was selected in the axial section, being the region in which the masticatory force is most demanded on the implants. Using the ImageJ software (Rasband, 2018) version 1.52k, the images were individually calibrated and measured by determining the areas formed by the polygons in each planning.

Figure 3. Formation of polygons in the All On Four (A) and Four On Pillars techniques.



Source: Authors.

The axial image is scaled 1:1 and next to it there is a real millimeter ruler. Through the ruler (Figure 4) the measure of 1 cm was calibrated and in the ImageJ software the cm/pixel ratio was calibrated. In this way, the formed polygon was able to measure in real values how many square centimeters were formed in each planning.

To analyze the area formed in surgical planning, the Shapiro-Wilk normality test was performed in each of the two groups (ALL and FOUR) to choose the most appropriate statistical treatment. As we compared the planning by the two methods, in the same patient, we used a paired test, as there is a dependence between the area values. In case both groups pass the normality test, the paired t-test will be used, and if at least one of them does not pass, the Wilcoxon signed-rank test will be used.

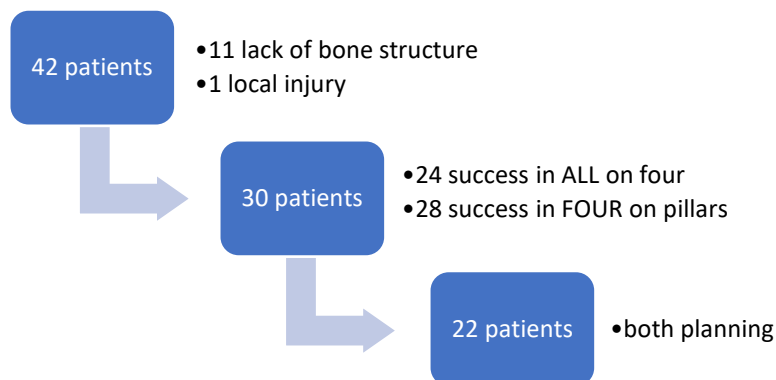
To analyze the proportions of failures and successes in planning by the two methods (ALL and FOUR) we create a contingency table describing the successes and failures of each method than Fisher's exact test was used.

In this work, we consider significant values of $p < 0.05$.

3. Results and Discussion

Computed tomography scans of 42 patients were evaluated, 4 males and 38 females. The mean age of patients was 64.0 ± 10.4 (mean \pm standard deviation). In 11 patients, none of the plans could be carried out due to the lack of bone structure. 1 patient had a local injury, which also made planning impossible. The flowchart in Figure 4 represents the analysis performed.

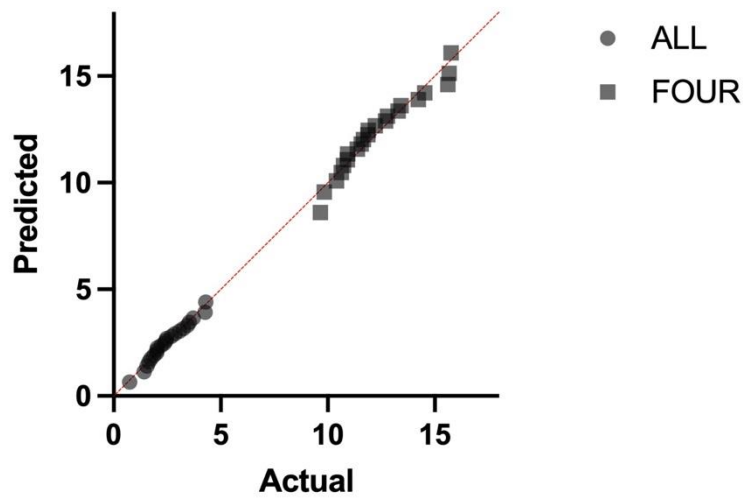
Figure 4. Flowchart of analyzed images.



Source: Authors.

Each study group passed the normality test (Shapiro-Wilk), Figure 5 shows the Q-Q plot, illustrating the test result. The proximity of the points to the red line suggests data normality.

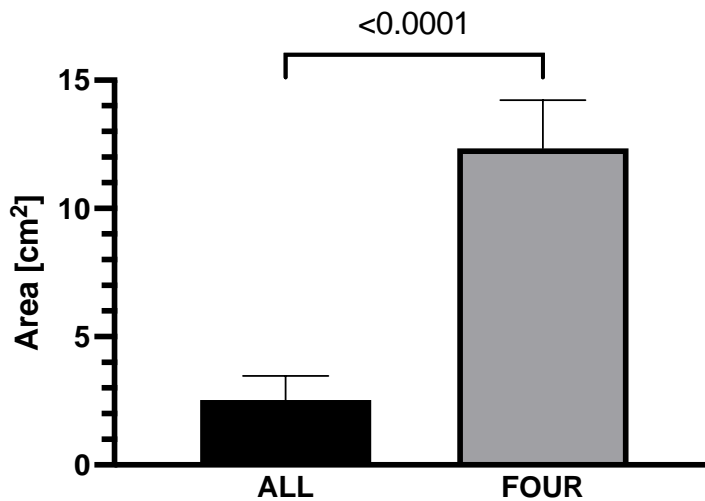
Figure 5. Q-Q chart for normality.



Source: Authors.

To compare the areas formed in the two surgical plans, we considered only the patients where planning by the two treatments was possible (n=22), as shown in Figure 4. Figure 6 shows the averages of the areas formed by the polygon; the error bars represent the standard deviation. The average area of the Four on pillars technique is 4.9x larger than the average area of the All on four technique, this represents a difference of 489%. This means that, for the same force applied by the jaw, we will have a 4.9x smaller pressure, that is, a better distribution of forces on the jaws.

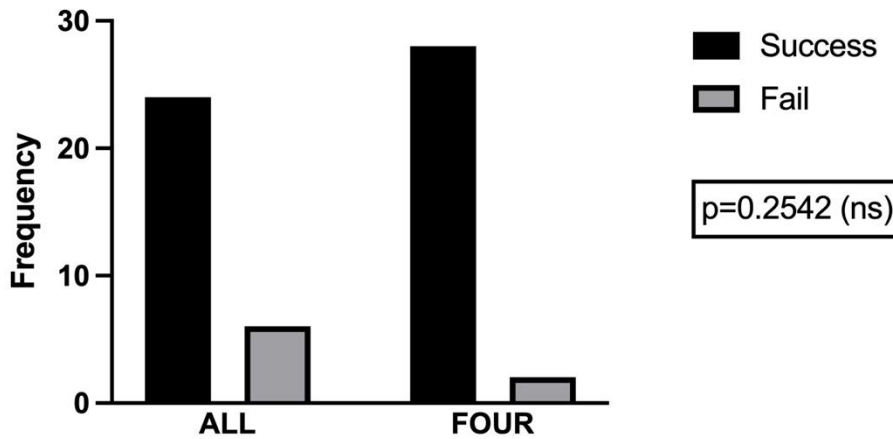
Figure 6. Planning area.



Source: Authors.

As there is a difference in the plans due to the position of the implants, there may be a difference in probabilities in the possibility of executing each plan (Four on pillars or All on four). To investigate whether there is a difference in success proportions comparing the two plans, we set up a contingency table and performed Fisher's exact test. Figure 8 shows the success and failure rates for each schedule.

Figure 7. Success rate of Four on pillars and All on four plans.



Source: Authors.

For this number of images evaluated for planning (n=30 images), it was not possible to notice a statistical difference between the proportions of success (p=0.2542). This means that both techniques have a non-different (similar) success ratio.

One study evaluated 63 patients, 21 were successfully rehabilitated with maxillary and mandibular All on Four, 21 patients were dentate and 21 were rehabilitated with double complete dentures. Electromyography was performed during tightening, non-ritual chewing, habitual chewing and at rest. All values were standardized as a percentage of a maximum voluntary contraction and as a result, similarity of muscle function in patients with total and toothed dentures shows that this concept of treatment can be considered a good option for oral rehabilitation in edentulous patients (De Rossi et al., 2014). Our results show that All on four presented greater pressure on the implants because a force applied on a surface can be decomposed into two effects: a tangential one, which gives rise to shear stresses, and a normal one (F_n), which gives rise to the pressures (Brunetti, 2008). If the pressure (p) is uniform, over the entire area (A), or if the interest is in mean pressure, then:

$$p = \frac{F_n}{A} \tag{eq. 1}$$

In an analysis of morphological characteristics of the pterygomaxillary region related to pterygoid implants, CBCT of 52 three-dimensional hemi-maxillas were analyzed. Bone density, volume, height, and width were analyzed at various sites in the maxillary and pterygoid process, and the variables age, sex, and dentistry status patients were compared. The results show that the mean width of the pterygomaxillary joint was 7.5 mm (SD 1.00 mm), the mean height was 12.51 mm (SD 1.82 mm) and the mean volume was 321.7 mm³ (SD 142.02 mm³). Statistically significant differences were found between dentate and edentulous patients, showing a higher bone density in patients dentate in the pterygoid process. In the maxilla, density was statistically significantly lower in females (571.0; SD 74.1; 95% CI 594.9 to 645.4 GSD) than in men (620.2; SD 93.8; 95% CI 594.4 to 645.4 GSD, p = 0.047). Due to the significant variation in the morphological characteristics of the pterygomaxillary region between subjects, personalized pre-surgical radiological assessment should always be performed. Gender, age and dental condition are critical factors, as they significantly affect bone density in this region (Salinas-Goodier et al, 2019). Atrophic jaws have serious aesthetic and functional consequences. The retention and support of an upper obturator prosthesis in these patients is particularly challenging. Surgical placement of implants is also difficult due to the lack of available bone. Therefore, implant placement in remote locations, such as the zygoma, has been advocated. Very few articles in the literature have discussed the use of pterygoid / pterygomaxillary implants in patients undergoing atrophic maxillae. This case report describes the

maxillofacial rehabilitation of an elderly man who underwent a bilateral subtotal maxillectomy for basaloid squamous cell carcinoma of the hard palate. After initial healing, the patient had a pterygoid implant placed on each side of the oral cavity. Zygomatic implants were also tried but failed to osseointegrate. Both pterygoid implants showed successful osseointegration. These 2 implants significantly helped to retain a full denture (Bidra et al., 2013). In our work, using the techniques All on four and Four on pillars, both techniques had a non-different (similar) success ratio.

In future works a correlation of the success ratio with the age could bring more information for surgical planning. Also, we encourage a post-surgical longitudinal-analysis to evaluate the wear of the implants.

4. Conclusion

We conclude that the area of the polygon formed in the Four on Pillars surgical plan is on average 4.9x larger than in the All on Four plan and this results in significantly less pressure on the implants. We also concluded that it was not possible to notice a statistical difference between the proportions of success, which shows that there is no technique with successful performance advantages over another.

References

- Al Yafi, F., Camenisch, B., & Al-Sabbagh, M. (2019). Is Digital Guided Implant Surgery Accurate and Reliable? *Dental Clinics*, 63(3), 381 – 397.
- Alevizakos, V., Mitov, G., Stoetzer, M., & Von See, C. (2019). A retrospective study of the accuracy of template-guided versus freehand implant placement: A nonradiologic method. *Oral Surg Oral Med Oral Pathol Oral Radiol*. 128(3):220-226. 10.1016/j.oooo.2019.01.009
- Anandakrishna, G. N., & Rao, G. (2012). Pterygomaxillary implants: a graftless solution to deficient maxillary bone. *J Indian Prosthodont Soc*. 12(3):182-186. doi:10.1007/s13191-012-0121-1
- Balshi, T. J., Lee, H. Y., & Hernandez, R. E. (1995). The use of pterygomaxillary implants in the partially edentulous patient: a preliminary report. *The International journal of oral & maxillofacial implants*, 10(1), 89–98.
- Balshi, T. J., Wolfinger, G. J., & Balshi, S. F., 2nd (1999). Analysis of 356 pterygomaxillary implants in edentulous arches for fixed prosthesis anchorage. *The International journal of oral & maxillofacial implants*, 14(3), 398–406.
- Brunetti, F. (2008). *Mecânica dos fluídos*. (2a ed.), Pearson Prentice Hall.
- Bidra, A. S., May, G. W., Tharp, G. E., & Chambers, M. S. (2013). Pterygoid implants for maxillofacial rehabilitation of a patient with a bilateral maxillectomy defect. *J Oral Implantol*. 39(1):91-97. 10.1563/AAID-JOI-D-10-00181
- De Rossi, M., Santos, C. M., Miglironça, R., & Regalo, S. C. (2014). All on Four® fixed implant support rehabilitation: a masticatory function study. *Clin Implant Dent Relat Res*. 16(4):594-600. doi:10.1111/cid.12031
- Dérig (2021). *Dérig - Implantas do Brasil*. <<https://derig.com.br/en/>>.
- Durkan, R., Oyar, P., & Deste, G. (2019). Maxillary and mandibular all-on-four implant designs: A review. *Nigerian journal of clinical practice*, 22(8), 1033–1040. https://doi.org/10.4103/njcp.njcp_273_18
- Greenberg A. M. (2017). Advanced dental implant placement techniques. *Journal of Istanbul University Faculty of Dentistry*, 51(3 Suppl 1), S76–S89. <https://doi.org/10.17096/jiufd.17594>
- Implantviewer (2021). *Implantviewer – Planejamento Cirúrgico Com Tomografia. Versão 3.5, 2021*. <<http://www.annesolutions.com.br/implantviewer/>>
- Lund, T. W., & Marshall W. (1993). Use of Osseointegrated Implants to Support a Maxillary Denture for a Patient with Repaired Cleft Lip and Palate. *The Cleft Palate-Craniofacial Journal* 30(4):418–20. 10.1597/1545-1569_1993_030_0418_uooits_2.3.co_2.
- Maló, P., Rangert, B., & Nobre, M. (2003). "All-on-Four" immediate-function concept with Brånemark System implants for completely edentulous mandibles: a retrospective clinical study. *Clinical implant dentistry and related research*, 5 Suppl 1, 2–9. <https://doi.org/10.1111/j.1708-8208.2003.tb00010.x>
- Peñarrocha, M., Carrillo, C., Boronat, A., & Peñarrocha, M. (2009). Retrospective study of 68 implants placed in the pterygomaxillary region using drills and osteotomes. *The International journal of oral & maxillofacial implants*, 24(4), 720–726.
- Rasband, W. S. (2018). *ImageJ*, U. S. National Institutes of Health, Bethesda, Maryland, USA, <https://imagej.nih.gov/ij/>, 1997-2018.
- Salinas-Goodier, C., Rojo, R., Murillo-González, J., & Prados-Frutos, J. C. (2019). Three-dimensional descriptive study of the pterygomaxillary region related to pterygoid implants: A retrospective study. *Sci Rep*. (1):16179. doi:10.1038/s41598-019-52672-x

- Schneider, D., Sancho-Puchades, M., Schober, F., Thoma, D., Hämmerle, C., & Jung, R. (2019). A Randomized Controlled Clinical Trial Comparing Conventional and Computer-Assisted Implant Planning and Placement in Partially Edentulous Patients. Part 3: Time and Cost Analyses. *Int J Periodontics Restorative Dent*. 39(3):e71-e82. [10.11607/prd.4146](https://doi.org/10.11607/prd.4146)
- Siadat, H., Rokn, A., & Beyabanaki, E. (2018) Full Arch All-on-4 Fixed Implant-Supported Prosthesis with 8.5 Years of Follow-Up: A Case Report. *J Dent (Tehran)*. 15(4):259-265.
- Smidt, R., Schneider, L. E., Nacanecy, M. M., Ozcamur A. (2018). Reabilitação de maxila edêntula atrófica utilizando um novo conceito biomecânico Four on Pillars. *INPerio* 3(5): 857-863.
- Soto-Penalosa, D., Zaragozı-Alonso, R., Penarrocha-Diago, M., & Penarrocha-Diago, M. (2017). The all-on-four treatment concept: Systematic review. *Journal of clinical and experimental dentistry*, 9(3), e474–e488. <https://doi.org/10.4317/jced.53613>
- Tannyhill, R. J. 3rd, & Jensen, O. T. (2019). Computer Simulation and Maxillary All-on-Four Surgery. *Oral Maxillofac Surg Clin North Am*. 31(3):497-504. [doi:10.1016/j.coms.2019.03.011](https://doi.org/10.1016/j.coms.2019.03.011)