

Pseudo-atrial flutter in a patient with heart-failure – Case report

Pseudo-flutter atrial em paciente com insuficiência cardíaca – Relato de caso

Aleteo pseudoauricular en un paciente con insuficiencia cardíaca – Informe de caso

Received: 04/28/2025 | Revised: 05/05/2025 | Accepted: 05/06/2025 | Published: 05/08/2025

Sophie Ballot

ORCID: <https://orcid.org/0000-0001-5692-9140>
Centro Veterinário Colina, Rio de Janeiro, Brazil
E-mail: sb_sophieballot@hotmail.com

Marcelo Barbosa de Almeida

ORCID: <https://orcid.org/0000-0001-8219-8484>
Centro Veterinário Colina, Rio de Janeiro, Brazil
E-mail: vetcolina@hotmail.com

Ana Carolina Mendes dos Santos

ORCID: <https://orcid.org/0000-0002-7760-713X>
Centro Veterinário Colina, Rio de Janeiro, Brazil
E-mail: acmvetcolina@gmail.com.br

Ângela Vargas da Silva

ORCID <https://orcid.org/0000-0003-3354-9094>
Centro Veterinário Colina, Rio de Janeiro, Brazil
E-mail: angela.vgm@hotmail.com

Gustavo Luiz Gouvêa de Almeida

ORCID: <https://orcid.org/0000-0001-7612-7655>
Hospital-Geral da Santa Casa de Misericórdia do Rio de Janeiro; Brazil
Centro Veterinário Colina, Rio de Janeiro, Brazil
E-mail: vetcolina@pig.com.br

Abstract

This article aims to present a case report of pseudo-atrial flutter in a 13-year-old-female breed dog referred for examination after a positive test for dirofilariasis. The clinical examination and echocardiogram identified degenerative mitral valve disease stage ACVIM- B2. Serial ECG of the patient showed on the baseline, instead of true P waves, bursts of repetitive small deflections resembling sawtooth waves, with a frequency of 300/min (5 Hz), identified as pseudo-atrial flutter. The P-QRS complexes were within normal reference range for the canine species.

Keywords: Pseudo-atrial flutter; Heart failure; Dog.

Resumo

Este artigo tem como objetivo apresentar um caso de pseudo-flutter atrial em uma cadela sem raça definida, de 13 anos, encaminhada após exame positivo para dirofilariose. O exame clínico e o ecocardiograma identificaram doença valvar mitral degenerativa estágio ACVIM- B2. O ECG seriado da paciente mostrou, na linha de base, em vez de ondas P verdadeiras, surtos de pequenas deflexões repetitivas semelhantes a ondas dente de serra, com frequência de 300/min (5 Hz), identificadas como pseudoflutter atrial. Os complexos QRS-P estavam dentro da faixa de referência normal para a espécie canina.

Palavras-chave: Pseudo-flutter atrial; Insuficiência cardíaca; Cão.

Resumen

Este artículo tiene como objetivo presentar un caso de pseudoaleteo auricular en una perra mestiza de 13 años, remitida después de una prueba positiva para la. El examen clínico y el ecocardiograma identificaron una enfermedad valvular mitral degenerativa en estadio ACVIM-2. El ECG seriado de la paciente mostró, en la línea de base, en lugar de ondas P verdaderas, ráfagas de pequeñas deflexiones repetitivas similares a ondas de diente de sierra, con una frecuencia de 300 lpm (5 Hz), identificadas como pseudoaleteo auricular. Los complejos P-QRS se encontraban dentro del rango de referencia normal para la especie canina.

Palabras clave: Pseudoflutter atrial; Insuficiencia cardíaca; Perro.

1. Introduction

Although atrial flutter (AF) is an well known arrhythmia in the human medical practice, it is not rare to face with situations in wich electrocardiographic artifacts resemble AF and are erroneously diagnosed, leading to inapropriate treatment (Vanerio, 2007; Al-Hamdi et al.,2020; Jagadish & Magalur, 2023).

Several cases of pseudo-atrial flutter have been reported affecting people with muscle tremors due to Parkinson's disease (Vanerio, 2007; Jagadish & Magalur, 2023; Nam MC et al. 2016; Saaren et al. 2018; Osman W, Hanson M & Baranchuk A., 2019), as well as in other conditions such as essential tremor, anxiety, hyperthyroidism, multiple sclerosis, and effect of certain drugs as amphetamines, xanthines, lithium, benzodiazepines, shivering due to hypothermia and fever, causing artifacts in the baseline, mimiking supraventricular or ventricular contractions (Riera et al, 2018).

Particularly in dogs, panting and muscular tremors are common during recording an electrocardiogram, that has the potential to cause artifactual "waves" resembling atrial fibrillation/flutter (Ettinger & Sutter, 1970).

True atrial flutter is considered rare amongst the canine population (Buchanan 1965; Goodwin, 2002; Kittleson, 2025), while pseudo-atrial flutter was not reported before in the veterinary literature.

The objective of this case report is to describe the occurrence of pseudo atrial flutter in a dog referred to for cardiological evaluation after a positive test for dirofilariasis.

2. Methodology

In this case report, a descriptive-qualitative methodology (Pereira et al., 2018) was used detailing the clinical, electrocardiographic, and echocardiographic findings in the case of pseudo-atrial flutter in a dog with dirofilariasis.

For electrocardiography was employed the digital computed electrocardiography system InCardio® (InPulse Animal Health, Florianópolis-Brazil). The patient was restrained on right lateral recumbency during the procedure, without sedation, according to Willys, 2018. For echocardiograph examination was used the Esaote Alpha Ultrasound System (Esaote S. p.A. Geneva, Italy) was used, following the ACVIM Guidelines for the Diagnosis and Treatment of Myxomatous Mitral Valve Disease in Dogs (Keenne et al., 2019).

This study followed the ethical principles of the Resolução Nº 55, de 5 de outubro de 2022 (Ministério da Ciência, Tecnologia e Inovações/Conselho Nacional de Controle de Experimentação Animal).

3. Case Description

A 13-year-old Poodle dog was referred for cardiology evaluation due to a postive test for dirofilariasis.

4. Results

On cardiac auscultation was detected a holosystolic murmur typical of mitral valve regurgitation, with intensity 3/6. Systolic arterial pressure was 120 mmHg, while the mean heart-rate was 115 bpm.

The bidimensional echocardiograph examination showed enlargement of left atrio-ventricular chambers and significant mitro-tricuspid regurgitation.

The ECG tracings showed in an isoelectric baseline, with P waves instead, bursts of sawtooth-shaped small deflections (Figures 1 and 2). The mean ventricular rate was 95 bpm, while the pseudo-P waves showed a frequency of 300/min, without correlation with the QRS complexes. The true P waves and the QRS complexes (figure 2) were all within the normal reference range for dogs (Oliveira, 2018). On pulsed Doppler registry was detected normal E/A waves from trans mitral inflow, permitting to rule-out of true atrial flutter (Figure 3).

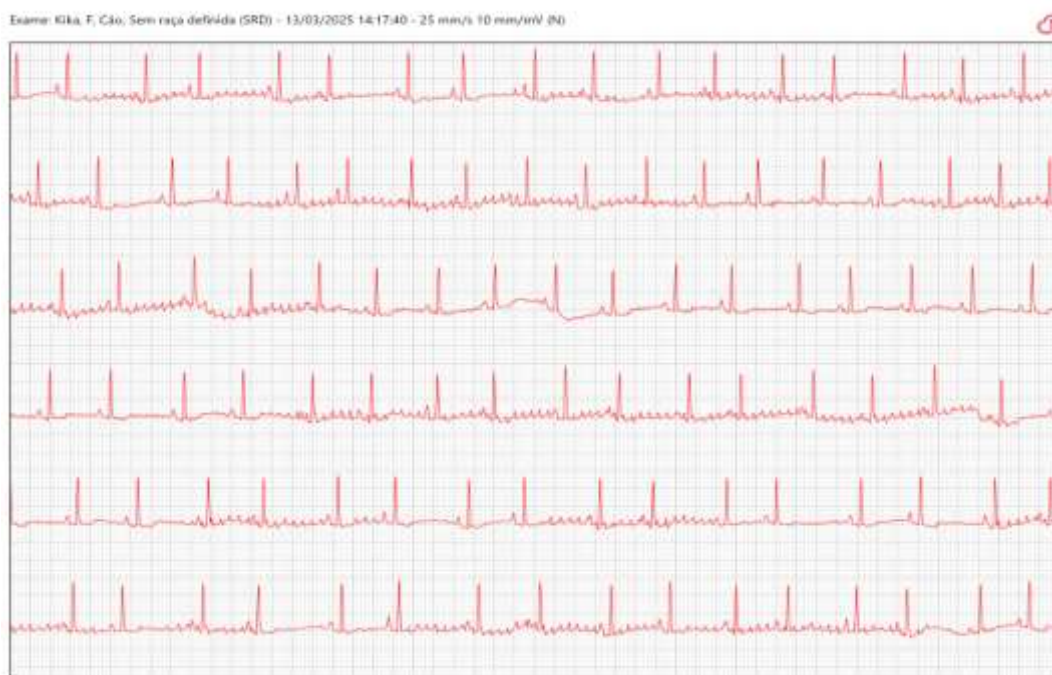5. Discussion

Atrial flutter is considered a rare arrhythmia in the canine population (Buchanan, 1965; Goodwin, 2002; Kittleson, 2025). In fact, according to the classic study carried out at the University of Pennsylvania, only two cases were identified among a population of 3000 dogs (incidence 0,33/000, or 0,03%), constituting the first report of this condition in veterinary medicine (Patterson et al., 1961). Five decades later, an investigation of cardiac arrhythmias in a population of 20,000 dogs from Nandini Veterinary Hospital, in Gujarath, India, was found 8 dogs with AF, representing an incidence of 0,06% or 0,006/1000 (Varshney, J.P. et al. 2013). More recently, a study in a university veterinary hospital in Rio de Janeiro was diagnosed two cases of AF among 586 dogs screened for cardiovascular disease, giving an incidence of 0,34% or 0,034/1000 (Mendonça et al, 2022).

As a result of artifacts, the components of the electrocardiogram such as the baseline and deflections are distorted by the effect of muscular tremors, and may be misinterpreted as atrial flutter (Riera et al, 2017). These artifacts can be electric, mechanical or both. In fact, skeletal muscle tremors sometimes resemble atrial flutter waves. In humans, two frequent clinical conditions that produce prominent muscle tremors are Parkinson's disease and hyperthyroidism. In most instances, they are easy to recognize and diagnose, because the resulting baseline oscillations are usually irregular in shape, size and rhythm (Cheng et al, 1970). However, EKG artifacts can simulate true atrial arrhythmias, and the distinction between them can be challenging to elucidate specially in emergency settings (Maden & Chang, 2017; Özsoylu et al, 2019).

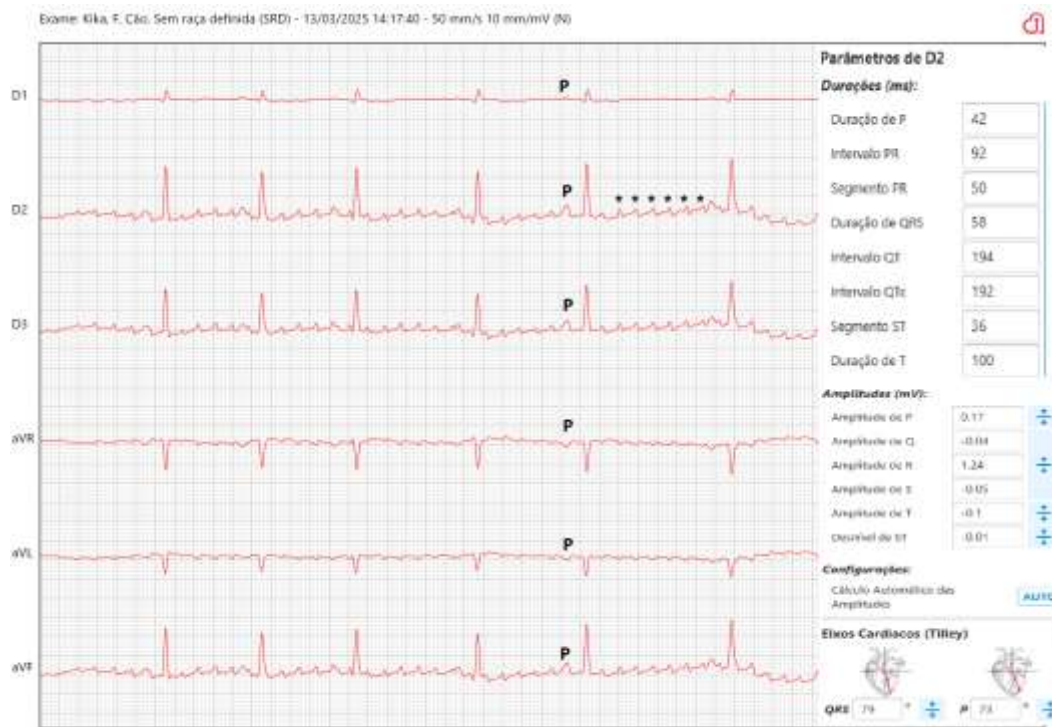A crucial point for diagnosis of pseudo-atrial flutter is that tremor induced arrhythmia has abrupt onset and termination, as well as presence of normal P waves and/or QRS complex (Areen et al, 2018), as documented in the figures 1 and 2. Furthermore, echocardiographic examination, when available, can help to discriminate the presence or absence of atrial contraction as noted on the Figure 3.

Figure 1 - D-2 lead tracing.



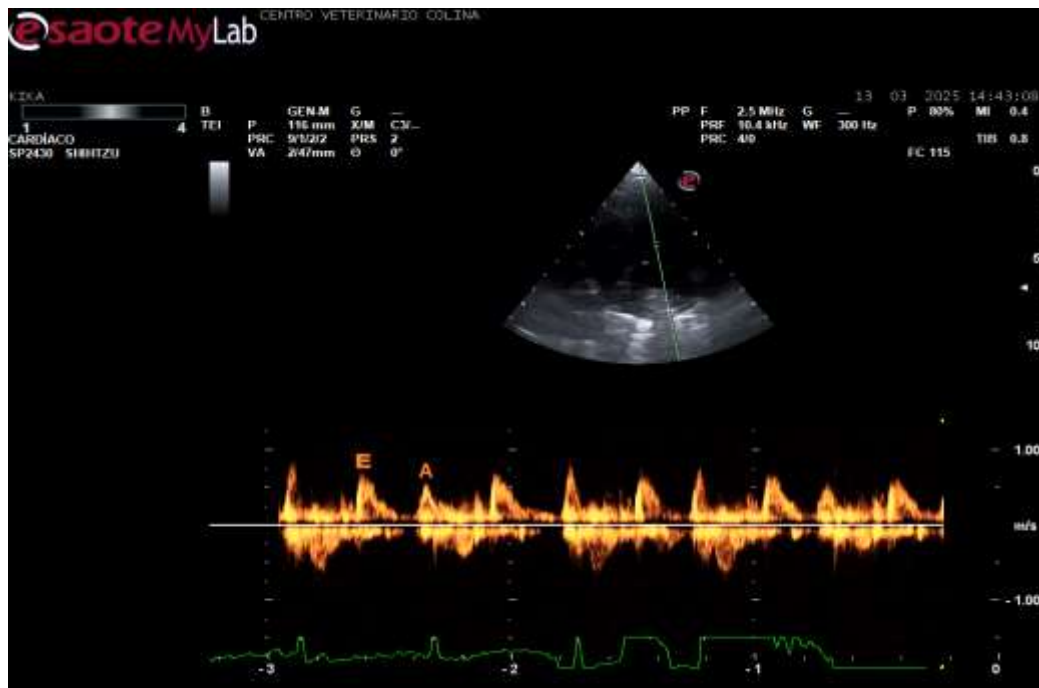
Source: Authors.

Figure 2 - Six-lead computed electrocardiogram.



Note the sinus arrhythmia and intermittent bursts of pseudo-flutter waves (*) associated to muscular tremors, during the ECG inscription mimicking atrial flutter. Source: Authors.

Figure 3 - Echocardiography examination.



Pulsed-doppler of transmittal inflow showing normal E-A waves. Source: Authors.

To the best of our knowledge this is the first report of pseudo-atrial flutter in the veterinary literature.

6. Conclusion

In the presence of artifacts on the electrocardiogram, it is advisable to check for a direct temporal correlation between muscle tremors and artifacts during the examination, as clearly documented in this patient. Therefore, a thorough analysis of the ECG can avoid erroneous diagnoses and, consequently, inappropriate treatments. Concomitant echocardiography, when available, may be useful to unmask the presence of false atrial flutter.

References

- Al-Hamdi Amar, T. (2020). Artifacts in electrocardiogram interpreted as cardiac arrhythmias: Reports of clinical cases. *J. Fac. Med. Baghdad*. 62(4), 104-8.
- Areen, S., Nayyar, M., Wheeler, B., Skelton, M. & Khouzam, R. N. (2018). Electrocardiographic artifact potentially misleading to the wrong management. *Ann Transl Med.* (1): 17. doi: 10.21037/atm.2017.11.33.
- Baranchuk, A. & Kang, J. (2009). Pseudo-atrial flutter: Parkinson tremor. *Cardiol J.* 16(4), 373-4. doi:10.1080/13668803.2014.970128.
- Barrett, C. D., Kelly, P. J., Halley, C. & Sugrue, D. (2007). Pseudo atrial flutter. *Eur J Intern Med.* 18(8), 603-4. doi: 10.1016/j.ejim.2007.02.028. Epub 2007. PMID: 18054714.
- Buchanan, J. W. (1965). Spontaneous Arrhythmias and Conduction Disturbances in Domestic Animals. *Annals of The New York Academy of Sciences.* 27(1), 224-38.
- Cheng, T. O. & Efpraxiades, J. (1970). Electrocardiogram of the month. Pseudo-atrial flutter. *Chest.* 57(3):290-2.
- Detweiler, K. & Patterson, D. F. (1965). The prevalence and types of cardiovascular diseases of dogs. *Annals of the New York Academy of Sciences.* (127), 481-516.
- Ettinger, S. & Sutter P. F. (1970). *Electrocardiography in: Canine Cardiology.* WB Saunders Company, Philadelphia. USA. p. 102-69.
- Goodwin, K. J. (2002). *Electrocardiography.* In: Tilley, L. P. & Goodwin, K. J. (2002). *Manual de Cardiologia de Cães e Gatos. Terceira Edição.* Editora Roca. São Paulo.
- Jagadish, A. & Hiremagalur, S. (2023) Global Pseudo-Atrial Flutter on Electrocardiogram and the Importance of Clinical Correlation. *Cureus.* 15(3), e35982. DOI 10.7759/cureus.35982.
- Keene, B. W. et al. (2019). ACVIM consensus guidelines for the diagnosis and treatment of myxomatous mitral valve disease in dogs. *Journal of Veterinary Internal Medicine* 33(3), 1127-40. doi: 10.1111/jvim.15488. PMID: 30974015; PMCID: PMC652408e.
- Kittleson, M. D. (2025). *Heart Disease: Conduction Abnormalities and Dogs and Cats.* in: MSD Manual. Merck & Co., Inc., Rahway, NJ, USA.
- Madden, G. R. & Chang J. J. (2017). Pseudo-Atrial Flutter Secondary to a Chest Wall Percussion Device. *Conn Med.* 81(4), 231-3. PMID: 29714409;PMCID: PMC7874240.
- Mendonça, D. A., Paiva, J. P., Knackfuss Bendas, A. & Alberigi, B. (2022). Risk of arrhythmias in dogs with structural heart disease. *Pesq. Vet. Bras.* (42), e07153, 202.
- Miller, M. S., Tilley, L. P., Smith Jr., F. C. & Fox, P. F. (1999). *Electrocardiography.* In: & Fox PF, Sisson D & Moise S.S. *Textbook of Canine and Feline Cardiology. Principles and Clinical Practice. Second Edition.* W.B Saunders Company. Philadelphia, Pensilvania. p.67-195.
- Nam, M. C., Best, L., Greaves, K. & Dayananda, N. (2016). Global pseudo-atrial flutter ECG appearance secondary to unilateral parkinsonian tremor. *BMJ Case Rep.* Doi: <http://doi.org/10.1136/bcr-2015-2140485>.
- Oliveira P. (2018). *Atrial Rythms.* In: *Guide to Canine and Feline Electrocardiography.* Ruth Willis, Pedro Oliveira & Antonia Mavropoulou. Wiley & Sons Ltd. John Wiley & Sons Ltd.
- Osman, W., Hanson, M. & Baranchuk, A. (2019). Pseudo-Ventricular Tachycardia, Pseudo-Atrial Fibrillation, and Pseudo-Atrial Flutter in a Patient With Parkinson Disease: Two's Company, Three's a Crowd. *JAMA Intern Med.* 179(6), 824-6.
- Özsoylu, S., Akyıldız, B. N., Dursun, A. & Pamukçu, Ö. (2019). Could you say that was an atrial flutter or not? *Turk J Pediatr.* 61(4), 608-10. doi:10.24953/turkjped.2019.04.021. PMID: 31990482.
- Patterson, D. F., Detweiler, D. K., Hubben, K. & Botts, R. P. (1961). Spontaneous abnormal cardiac arrhythmias and conduction disturbances in the dog (a clinical and pathologic study of 3,000 dogs). *American Journal of Veterinary Research.* (22), 355-69.
- Pereira A. S. et al. (2018). *Metodologia da pesquisa científica.* [free e-book]. Editora da UAB/NTE/UFSM.
- Pérez-Riera, A. R., Barbosa-Barros, R., Daminello, R. & Abreu, L. C. (2017). Main artifacts in electrocardiography. *Annals of Noninvasive Electrocardiol.* (23), e12494. <https://doi.org/10.1111/anec.12494>.
- Sareen, S., Nayyar, M., Wheeler, B., Skelton, M. & Khouzam, R. N. (2018). Electrocardiographic artifact potentially misleading to the wrong management. *Ann Transl Med.* 6: 17. Doi: <http://doi.org/10.21037/atm.2017.11.332023>.

Tilley, L. P. & Smith Jr., F. C. (2016). Electrocardiography. In: Manual of Canine and Feline Cardiology Fifth Edition. Elsevier. Riverport Lane St. Louis, Missouri. 63043, 49-76.

Toassi, R. F. C. & Petry, P. C. (2021). Metodologia científica aplicada à área da Saúde. (2ed.). Editora da UFRGS.

Vanerio, G. (2007). Tremor As a Cause of Pseudoatrial Flutter. American Journal of Geriatric Cardiology. 16(2), 106-8.

Varshney, J. P., Sutaria, P. V. V., Deshmukh, V. V. & Chaudhary, P. S. (2013). Prospective Study of Cardiac Arrhythmias. A survey of 20,000 canines. Intas Polivet. 14(1), 129-36.

Willis, R. (2018). Electrocardiography. In: Willis R., Mavropoulos, Pedro B., Guide to Canine and Feline Electrocardiography. Wiley & Sons Ltd. Hoboken, USA., 109-26.

Yin, R.K. (2015). O estudo de caso. Porto Alegre: Bookman.