

**Treatment outcome of young molars obstructed by fractured endodontic instruments:  
two case reports**

**Resultado do tratamento de molares jovens obstruídos por instrumentos endodônticos  
fraturados: relato de dois casos**

**Resultado del tratamiento de molares jóvenes obstruidos por instrumental endodóntico  
fracturado: reporte de dos casos**

Received: 09/16/2020 | Reviewed: 09/23/2020 | Accept: 09/26/2020 | Published: 09/27/2020

**Thaís Christina Cunha**

ORCID: <https://orcid.org/0000-0001-8292-4511>

Federal University of Uberlândia, Brazil

E-mail: [christina.thais@gmail.com](mailto:christina.thais@gmail.com)

**Felipe de Souza Matos**

ORCID: <https://orcid.org/0000-0001-5619-3831>

Federal University of Uberlândia, Brazil

E-mail: [felipe\\_smatos@hotmail.com](mailto:felipe_smatos@hotmail.com)

**Luiz Renato Paranhos**

ORCID: <https://orcid.org/0000-0002-7599-0120>

Federal University of Uberlândia, Brazil

E-mail: [paranhos.lrp@gmail.com](mailto:paranhos.lrp@gmail.com)

**Camilla Christian Gomes Moura**

ORCID: <https://orcid.org/0000-0002-5653-8403>

Federal University of Uberlândia, Brazil

E-mail: [camillahistologia@yahoo.com.br](mailto:camillahistologia@yahoo.com.br)

**Abstract**

Ultrasonic tips and anatomic finishing files have been used as strategies to improve the cleaning and disinfection of root canals, especially in complex anatomies. These instruments are also subjected to fractures, which can hinder the endodontic treatment and negatively affect the outcome. This article presents two cases of successful management of intracanal-fractured instruments with unfavourable prognosis, emphasizing on treatment protocols and outcomes. Two 14-year-old female patients underwent root canal treatment of teeth 37 (case 1) and 47 (case 2). During the final irrigation protocols, case 1 presented a fractured XP-

Clean file within the mesiobuccal canal and within the distal canal in case 2, which also showed fractured E1-Irrisonic tips within the mesiobuccal and distal canals. Non-surgical management and bypassing retained instrument fragments were successful in both cases and they may be considered adequate approaches.

**Keywords:** Endodontics; Fractured instrument; Root canal preparation; Treatment outcome.

### Resumo

Pontas ultrassônicas e limas anatômicas de acabamento têm sido utilizadas como estratégias para melhorar a limpeza e a desinfecção dos canais radiculares, principalmente em anatomias complexas. Esses instrumentos também estão sujeitos a fraturas, o que pode dificultar o tratamento endodôntico e afetar negativamente o resultado. Este artigo apresenta dois casos de manejo bem-sucedido de instrumentais fraturados dentro do canal radicular, com prognóstico desfavorável, com ênfase em protocolos de tratamento e resultados. Duas pacientes do sexo feminino, de 14 anos, foram submetidas a tratamento de canal dos dentes 37 (caso 1) e 47 (caso 2). Durante os protocolos de irrigação final, o caso 1 apresentou uma lima XP-Clean fraturada dentro do canal mesiovestibular e dentro do canal distal no caso 2, que também apresentava pontas E1-Irrisonic fraturadas nos canais mesiovestibular e distal. O manejo não cirúrgico e o desvio dos fragmentos dos instrumentos retidos foram bem-sucedidos em ambos os casos e podem ser considerados abordagens adequadas.

**Palavras-chave:** Endodontia; Instrumento fraturado; Preparo de canal radicular; Resultado do tratamento.

### Resumen

Las puntas ultrasónicas y las limas de acabado anatómico se han utilizado como estrategias para mejorar la limpieza y desinfección de los conductos radiculares, especialmente en anatomías complejas. Estos instrumentos también están sujetos a fracturas, lo que puede dificultar el tratamiento endodóntico y afectar negativamente el resultado. Este artículo presenta dos casos de manejo exitoso de instrumentos fraturados dentro del conducto radicular, con un pronóstico desfavorable, con énfasis en los protocolos y resultados del tratamiento. Dos pacientes mujeres de 14 años fueron sometidas a tratamiento de conducto 37 (caso 1) y 47 (caso 2). Durante los protocolos finales de irrigación, el caso 1 presentó una lima XP-Clean fraturada dentro del canal mesiovestibular y dentro del canal distal en el caso 2, que también presentaba puntas E1-Irrisonic fraturadas en los canales mesiovestibular y

distal. El manejo no quirúrgico y el desvío de fragmentos de los instrumentos retenidos fueron exitosos en ambos casos y pueden considerarse abordajes apropiados.

**Palabras clave:** Endodoncia; Instrumento fracturado; Preparación del conducto radicular; Resultado del tratamiento.

## 1. Introduction

New endodontic irrigation techniques using acoustic and hydrodynamic activation with sonic and ultrasonic devices (Bueno et al., 2019; Conde et al., 2017; Jiang et al., 2010) and anatomic finishing motor-driven files such as the XP-Endo Finisher (FKG Dentaire, La Chaux-de-Fonds, Switzerland) and XP-Clean (MK Life, Porto Alegre, RS, Brazil) (Bao et al., 2017; Carvalho et al., 2019; Vaz-Garcia et al., 2018) were developed to improve the effectiveness of root canal cleaning and disinfection protocols (Nagendrababu et al., 2018; Susila & Minu, 2019). Nevertheless, data regarding the fracture resistance of these instruments are scarce (Kirsch et al., 2019; Vaz-Garcia et al., 2018).

Overall, mechanized instrument fractures are concerning because retained intracanal fragments may hinder the adequate preparation of the root canal space and negatively affect the prognosis success of the endodontic treatment (Madarati et al., 2013; Panitvisai et al., 2010; Spili et al., 2005). The fracture rate of NiTi rotary instruments within root canals varies from 1.3% to 10% (Madarati et al., 2013), although there are no specific data regarding the clinical incidence of fracture on finishing nickel-titanium files. The management of intracanal-fractured instruments includes attempts to bypass and remove the fragment, preparation and filling of the root canal to the coronal level of the fragment, or surgical removal (Gencoglu & Helvacioğlu, 2009; Parashos & Messer, 2006). The ultrasonic technique has been successfully used to remove fractured rotary files (Shahabinejad et al., 2013), although its improper use may generate a secondary fracture of separated file fragments (Arslan et al., 2020; Terauchi et al., 2013). However, there are no reports about clinical management in cases of fractured ultrasonic tips during irrigation.

This study aimed to present two cases of successful management of intracanal fractures of anatomic finishing files (XP-Clean) and ultrasonic inserts (E1-Irrisonic) with unfavourable prognosis, emphasizing on treatment protocols and outcomes.

## 2. Methodology

This case report followed the CARE 2013 guidelines (Gagnier et al., 2013). All procedures performed in this case report were in accordance with the Helsinki Declaration. The parents of the patients signed an informed consent form authorizing the publication of the case and any accompanying images.

Two 14-year-old female patients were referred to endodontic treatment in the left (tooth 37, case 1) and right (tooth 47, case 2) mandibular second molars. A detailed review of the patient's medical and dental histories revealed no systemic disease and contributory oral conditions. Intraoral examinations showed negative responses to pulp sensitivity tests and palpation in the apical region and the absence of pathological mobility, but both patients reported positive responses to percussion, with the presence of caries. The radiographic examination revealed periapical radiolucent lesions (Figures 1a and 2a) and the pulp and periradicular status were diagnosed as pulp necrosis and asymptomatic apical periodontitis, respectively.

A single and experienced operator performed the root canal treatments of cases 1 and 2 using local anaesthesia and absolute isolation with a rubber dam. First, manual glide path preparations were performed with #08, #10, and #15 K-files (Dentsply Maillefer, Ballaigues, Switzerland) and 2.5% NaOCl (Rioquímica Ltda., São José do Rio Preto, SP, Brazil). The working lengths (WL) were determined with a RomiApex A-15 apex locator (Romidan Ltd., Kyriat Ono, Israel) and #15 K-file in all root canals. Biomechanical instrumentations were performed 1 mm short of the root canal length using the Twisted File (TF) Adaptive system up to the SM3 (#35/.04) file (SybronEndo, Orange, CA) adapted to the Elements motor (SybronEndo, Glendora, CA) in adaptive motion, according to the manufacturer's protocol, under abundant irrigation with 2.5% NaOCl.

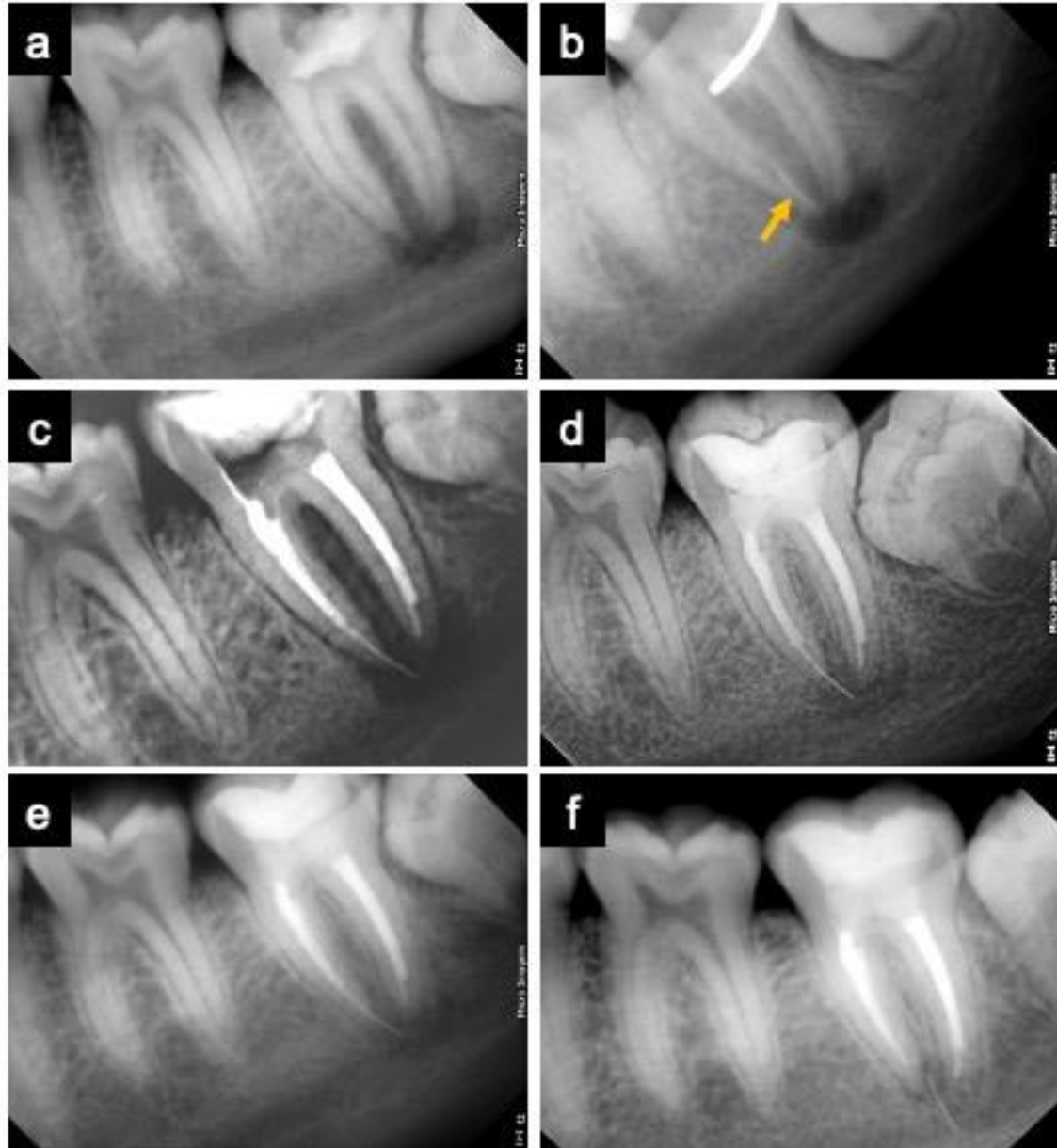
The final irrigation of all canals was carried out with 5 mL of 17% ethylenediaminetetraacetic acid (EDTA) for 3 minutes followed by 5 mL of 2.5% NaOCl agitated by XP-Clean instruments (MK Life, Porto Alegre, RS, Brazil) in continuous rotation, according to the manufacturer's recommendations (900 rpm and 1 Ncm-1 torque). However, during the agitation technique, the XP-Clean instruments fractured within the mesiobuccal (Figure 1b) and distal (Figure 2b) canals of teeth 37 (case 1) and 47 (case 2), respectively. The patients were informed about the fractured instruments and attempts were made to bypass and remove the fragments from the root canals with the help of the E5 ultrasonic insert (Helse Dental Technology, São Paulo, SP, Brazil) coupled to the EMS Piezon Master 200 Ultrasound

(EMS, São Bernardo do Campo, SP, Brazil) at a power setting of 20%. In both cases, the fragment was only bypassed and not removed, but in tooth 37 (case 1) it moved apically beyond the apical foramen (Figure 1c). Final irrigation was performed again in each canal using the E1-Irrisonic tip (Helse Dental Technology) at a power of 10% to activate ultrasonically the solutions for 30 seconds. During this procedure, new fractures occurred in the apical third of the ultrasonic insert within the mesiobuccal and distal canals (Figure 2b) of tooth 47 (case 2), and only the fragment within the distal canal was removed.

In both cases, the fragments within the canals were maintained and surgical removal was not indicated due to the proximity of the roots to the mandibular canal. Intracanal medication with calcium hydroxide paste (UltraCal™ XS, Ultradent Products Inc., South Jordan, UT, USA) was used for 14 days. In a second visit, as the teeth were asymptomatic, the roots were obturated with the lateral condensation technique using gutta-percha cones (Dentsply Maillefer, Ballaigues, Switzerland) and Sealapex sealer (SybronEndo, Orange, CA) (Figure 1c and 2c). The coronal accesses were sealed with resin-modified glass ionomer (Riva SDI, São Paulo, SP, Brazil) and restored with a light-cured composite resin (Opus bulk fill APS, FGM, Joinville, SC, Brazil). The patients did not present any painful symptoms and did not need analgesics during and after treatment.

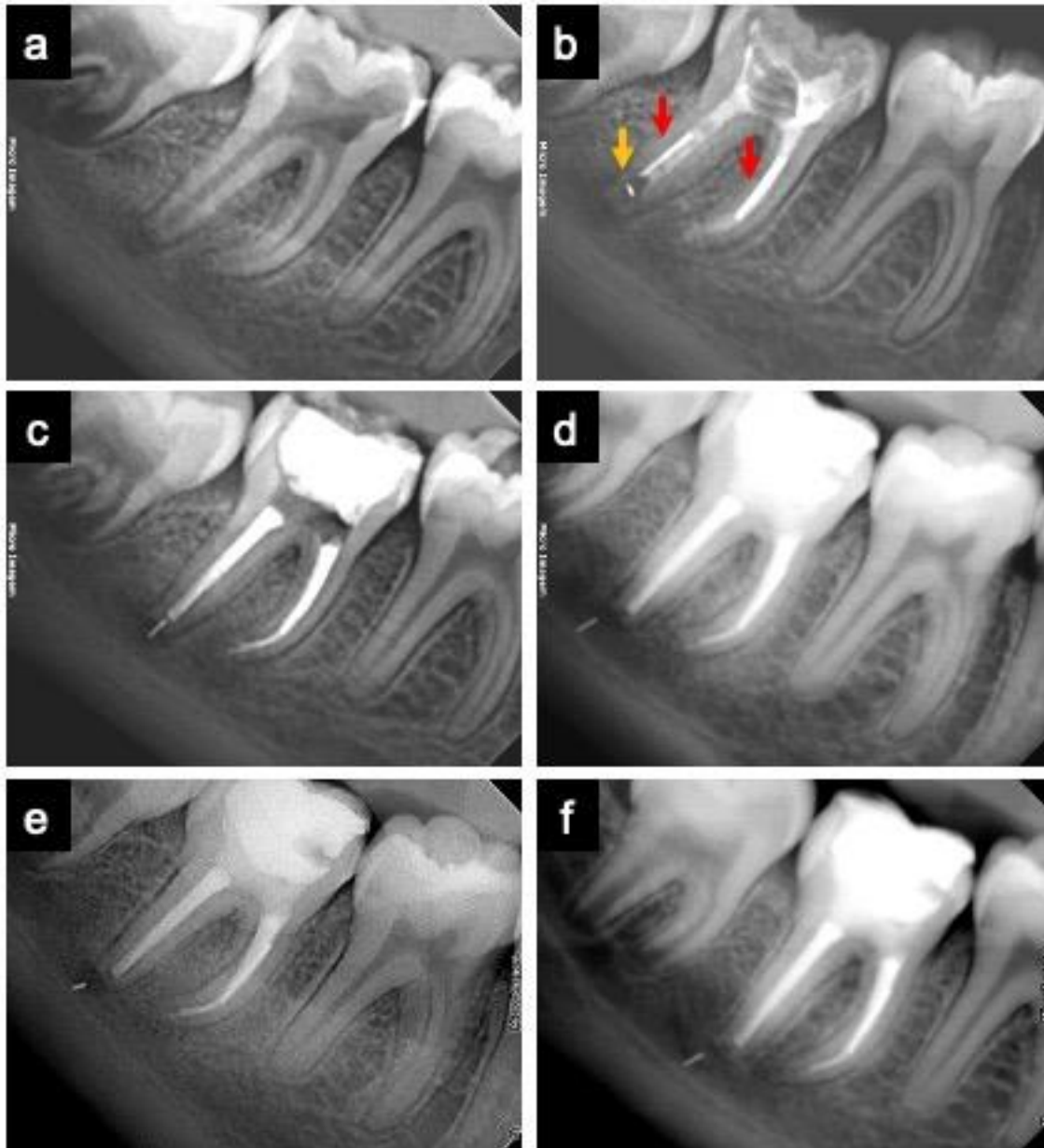
Clinical and radiographic follow-up sessions were carried out at 6 (Figures 1d and 2d), 12 (Figures 1e and 2e), and 18 (Figures 1f and 2f) months after the treatment. The patients reported no signs and symptoms related to the respective teeth. Radiographic images showed bone neof ormation in the periradicular area suggestive of successful endodontic treatment despite the complications.

**Figure 1.** Radiographic images of case 1: (a) Preoperative radiograph of the left mandibular second molar (tooth 37) showing periapical radiolucent lesion; (b) Radiograph after biomechanical instrumentation showing a fragment of the XP-Clean instrument (yellow arrow) within the mesiobuccal canal; (c) Radiograph after endodontic root canal filling; (d) 6-month follow-up; (e) 12-month follow-up; (f) 18-month follow-up showing bone neoformation in the periradicular area.



Source: The authors (2020).

**Figure 2.** Radiographic images of case 2: (a) Preoperative radiograph of the right mandibular second molar (tooth 47) showing periapical radiolucent lesion; (b) Radiograph after biomechanical instrumentation showing a fragment of the XP-Clean instrument (yellow arrow) within the distal canal and fragments of ultrasonic inserts (red arrows) within the mesiobuccal and distal canals; (c) Radiograph after endodontic root canal filling; (d) 6-month follow-up; (e) 12-month follow-up; (f) 18-month follow-up showing bone repair in the periradicular area.



Source: The authors (2020).

### 3. Results and Discussion

Case reports are still a great contribution to the endodontic literature, especially when involving techniques and instruments used extensively today, in which potential usage complications have not yet been reported, as in the two cases presented. This is the first

clinical report showing the fracture of an anatomic finishing file and ultrasonic tip used in passive ultrasonic irrigation and explaining the management of such complication.

New concepts of anatomic finishing files (XP-Endo Finisher and XP-Clean) were introduced for the final cleaning of root canals after any instrumentation technique to remove debris and microorganisms in untouched areas (Vaz-Garcia et al., 2018). Specifically in the cases reported, the XP-Clean file was chosen as a strategy for finishing the root canal preparation due to the large apical foramen of young patients, whose final apical SM3 (#35/.04) file would not be able to touch associated with the presence of radiolucent periapical lesions. According to the manufacturer, XP-Clean are NiTi instruments (#25/.02) developed to work as finishing files after the biomechanical preparation, increasing the cleaning power of the irrigating solution by mechanical agitation (“whipping” action), eliminating debris and remaining microorganisms due to the mechanical contact with the inner walls of the canals. However, unlike the XP-Endo Finisher, which is supported by current scientific literature (De-Deus et al., 2019; Reis et al., 2020), the XP-Clean was recently launched in the market. A previous *in vitro* study (Vaz-Garcia et al., 2018), comparing the mechanical properties of these two anatomic finishing files showed no difference in microhardness, although the XP-Endo Finisher showed higher resistance to cyclic fatigue than XP-Clean. Therefore, the fracture of XP-Clean files observed in both clinical cases could be attributed to torsional stress and cyclic fatigue. Additionally, the presence of defects on the surface of the instruments could also work as stress-concentration points, making these regions highly vulnerable to nucleation and crack propagation (Lopes et al., 2016; Vaz-Garcia et al., 2018).

Considering this complication, potential solutions would be trying to remove the XP-Clean fragment or bypass the fragments retained within the canal. Both alternatives may be difficult and time-consuming, with an overall clinical success rate ranging from 53% to 87% (Shen et al., 2004; Suter et al., 2005). The success of the non-surgical removal of fractured instruments from root canals depends on factors such as length and location of the fragment in the canal, instrument cross-sectional design, and diameter and degree of curvature of the root and the canal (Shen et al., 2004). When the position of the fragment prevents its conventional removal, with evidence of a negative impact on the treatment outcome due to its maintenance within the canal, a surgical approach may be considered the best option. However, in cases in which the surgical area is near vital anatomical structures at risk of damaging them, surgical removal is not indicated (Madarati et al., 2013; Wang et al., 2010). Ultrasonics under the visualization of an operating microscope has been considered the most effective method of



removing intracanal instrument fragments (Gencoglu & Helvacioğlu, 2009). However, the use of ultrasound for removing broken rotary nickel-titanium files may result in some procedural errors such as transportation, perforation, and root fracture (Shahabinejad et al., 2013) or create a secondary fracture of separated file fragments (Arslan et al., 2020; Terauchi et al., 2013). In the two cases reported, the attempt to remove the fragments with ultrasonic tips was partially unsuccessful, which led to their maintenance within the root canals due to the proximity to the mandibular canal, rendering surgical removal impossible. A very undesirable event observed after the removal attempt was the displacement of the fractured fragment beyond the apex, in proximity to the alveolar nerve (Gandevivala et al., 2014; Singh et al., 2017; Wang et al., 2016).

Unfortunately, in case 2, in addition to the primary file fracture, there was also a fracture of the E1-Irrisonic tip during the final irrigation of the root canal. Studies have shown that the acoustic flow and cavitation produced by ultrasound contribute to the cleaning capacity of the root canal irrigation (Jiang et al., 2010). This also makes them effective in several applications including root canal preparation, removal of pulp nodules and fractured instruments, and condensation of endodontic filling materials (Wan et al., 2014). However, regardless of the technique used, endodontic instruments might fracture within the root canal by improper use or pre-existing factors such as anatomical complications and weak points of the instrument itself related to the manufacturing process (Lopes et al., 2016). The fracture of ultrasonic inserts during endodontic procedures is rarely reported in the literature, but some studies correlate it with weak points such as the angle and the diameter of the tips (Walmsley et al., 1996). The acoustic streaming generated by ultrasound varies according to the tip size, in which instruments with smaller diameters have greater displacement amplitude (Ahmad et al., 1987; Lin et al., 2006). This may have favoured the fracture of the ultrasonic inserts in the roots of case 2. Additionally, the previous use of ultrasonic tips without controlling the number of times used and associated with the potential damage caused by the endodontic autoclave sterilization process may have contributed to the fracture (Dioguardi et al., 2019). Further studies evaluating the number of times ultrasonic inserts for endodontics can be used and sterilized are required to bring more safety to clinicians (Kirsch et al., 2019).

Overall, the occurrence of retained instrument fragment may affect the outcome of the endodontic treatment, transforming a common endodontic procedure into a complication that could result in tooth extraction (Madarati et al., 2013; McGuigan et al., 2013). The degree of canal infection should be considered when determining the potential effect of instrument fracture on the treatment outcome, as the healing rates of teeth with periapical lesions and

retained instrument fragment are around 86.7% compared with 92.9% for cases without retained fragment, after a 1-year follow-up (Spili et al., 2005). In both cases reported, the evidence of tissue repair characterized by bone neoformation and absence of clinical symptoms show the success of endodontic therapy although the maintenance of intracanal fragments has limited the access to the apical third of root canals. The stage and degree of root canal preparation and disinfection at the time of instrument fracture, fragment position, use of sterile instruments and antimicrobial solutions, and intracanal medication may have favoured the treatment prognosis (McGuigan et al., 2013). Generally, the cases presented reinforce the assumption that the success rate of endodontic treatment is related to the efficiency in disinfecting the root canal system, even in the presence of a fractured instrument (Nevares et al., 2012; Parashos & Messer, 2006; Simon et al., 2008). It is also necessary to be aware of the use of XP-Endo files, which even in single use seem to have a high potential for fractures.

#### **4. Conclusions**

Non-surgical management and bypassing retained fragments of anatomic finishing files (XP-Clean) and ultrasonic inserts (E1-Irrisonic) were successful in both cases and they may be considered adequate approaches. Clinical investigations are required to validate our results and to investigate the effectiveness of different protocols for the removal of fractured endodontic instruments from root canal systems.

#### **Acknowledgments**

The authors would like to thank CAPES (Coordination for the Improvement of Higher Education Personnel - Brazil) - Finance Code 001 for funding in part the execution of this work. We are also thankful for the support of CNPq (Council for Scientific and Technological Development - Brazil) - Finance Code 307808/2018-1.

#### **References**

Ahmad, M., Pitt Ford, T. R., & Crum, L. A. (1987). Ultrasonic debridement of root canals: acoustic streaming and its possible role. *Journal of Endodontics*, 13 (10), 490-499. doi:10.1016/S0099-2399(87)80016-X

Arslan, H., Doğanay Yıldız, E., Taş, G., Akbıyık, N., & Topçuoğlu, H. S. (2020). Duration of ultrasonic activation causing secondary fractures during the removal of the separated instruments with different tapers. *Clinical Oral Investigations*, 24 (1), 351-355. doi:10.1007/s00784-019-02936-7

Bao, P., Shen, Y., Lin, J., & Haapasalo, M. (2017). In vitro efficacy of XP-endo Finisher with 2 different protocols on biofilm removal from apical root canals. *Journal of Endodontics*, 43 (2), 321-325. doi:10.1016/j.joen.2016.09.021

Bueno, C. R. E., Cury, M. T. S., Vasques, A. M. V., Sarmiento, J. L., Trizzi, J. Q., Jacinto, R. C., Sivieri-Araujo, G., & Dezan Júnior, E. (2019). Cleaning effectiveness of a nickel-titanium ultrasonic tip in ultrasonically activated irrigation: a SEM study. *Brazilian Oral Research*, 33, e017. doi:10.1590/1807-3107bor-2019.vol33.0017

Carvalho, M. C., Zuolo, M. L., Arruda-Vasconcelos, R., Marinho, A. C. S., Louzada, L. M., Francisco, P. A., Pecorari, V. G. A., & Gomes, B. P. F. de A. (2019). Effectiveness of XP-Endo Finisher in the reduction of bacterial load in oval-shaped root canals. *Brazilian Oral Research*, 33, e021. doi:10.1590/1807-3107bor-2019.vol33.0021

Conde, A. J., Estevez, R., Loroño, G., Valencia de Pablo, O., Rossi-Fedele, G., & Cisneros, R. (2017). Effect of sonic and ultrasonic activation on organic tissue dissolution from simulated grooves in root canals using sodium hypochlorite and EDTA. *International Endodontic Journal*, 50 (10), 976-982. doi:10.1111/iej.12717

De-Deus, G., Belladonna, F. G., Zuolo, A. S., Cavalcante, D. M., Carvalhal, J. C. A., Simões-Carvalho, M., Souza, E. M., Lopes, R. T., & Silva, E. J. N. L. (2019). XP-Endo Finisher R instrument optimizes the removal of root filling remnants in oval-shaped canals. *International Endodontic Journal*, 52 (6), 899-907. doi:10.1111/iej.13077

Dioguardi, M., Sovereto, D., Aiuto, R., Laino, L., Illuzzi, G., Laneve, E., Raddato, B., Caponio, V. C. A., Dioguardi, A., Zhurakivska, K., Troiano, G., & Muzio, L. L. (2019). Effects of hot sterilization on torsional properties of endodontic instruments: systematic review with meta-analysis. *Materials*, 12 (13), 2190. doi:10.3390/MA12132190

Gagnier, J. J., Kienle, G., Altman, D. G., Moher, D., Sox, H., Riley, D., & Group\*, the C. (2013). The CARE guidelines: consensus-based clinical case reporting guideline development. *Journal of Medical Case Reports*, 2 (5), 38. doi:10.7453/GAHMJ.2013.008

Gandevivala, A., Parekh, B., Poplai, G., & Sayed, A. (2014). Surgical removal of fractured endodontic instrument in the periapex of mandibular first molar. *Journal of International Oral Health : JIOH*, 6 (4), 85-88.

Gencoglu, N., & Helvacioğlu, D. (2009). Comparison of the different techniques to remove fractured endodontic instruments from root canal systems. *European Journal of Dentistry*, 3 (2), 90-95.

Jiang, L.-M., Verhaagen, B., Versluis, M., & Van der Sluis, L. W. M. (2010). Evaluation of a sonic device designed to activate irrigant in the root canal. *Journal of Endodontics*, 36 (1), 143-146. doi:10.1016/j.joen.2009.06.009

Kirsch, J., Sina Reinauer, K., Meissner, H., Dannemann, M., Kucher, M., Modler, N., Hannig, C., & Weber, M.-T. (2019). Ultrasonic and sonic irrigant activation in endodontics: a fractographic examination. *Deutscher Ärzteverlag | DZZ International | Deutsche Zahnärztliche Zeitschrift International* |, 1 (6), 209-221. doi:10.3238/dzz-int.2019.0209-0221

Lin, Y.-H., Mickel, A. K., Jones, J. J., Montagnese, T. A., & González, A. F. (2006). Evaluation of cutting efficiency of ultrasonic tips used in orthograde endodontic treatment. *Journal of Endodontics*, 32 (4), 359-361. doi:10.1016/j.joen.2005.12.004

Lopes, H. P., Elias, C. N., Vieira, M. V. B., Vieira, V. T. L., de Souza, L. C., & dos Santos, A. L. (2016). Influence of surface roughness on the fatigue life of nickel-titanium rotary endodontic instruments. *Journal of Endodontics*, 42 (6), 965-968. doi:10.1016/j.joen.2016.03.001

Madarati, A. A., Hunter, M. J., & Dummer, P. M. H. (2013). Management of intracanal separated instruments. *Journal of Endodontics*, 39 (5), 569-581. doi:10.1016/j.joen.2012.12.033

McGuigan, M. B., Louca, C., & Duncan, H. F. (2013). The impact of fractured endodontic instruments on treatment outcome. *British Dental Journal*, 214 (6), 285-289. doi:10.1038/sj.bdj.2013.271

Nagendrababu, V., Jayaraman, J., Suresh, A., Kalyanasundaram, S., & Neelakantan, P. (2018). Effectiveness of ultrasonically activated irrigation on root canal disinfection: a systematic review of in vitro studies. *Clinical Oral Investigations*, 22 (2), 655-670. doi:10.1007/s00784-018-2345-x

Nevares, G., Cunha, R. S., Zuolo, M. L., & da Silveira Bueno, C. E. (2012). Success rates for removing or bypassing fractured instruments: a prospective clinical study. *Journal of Endodontics*, 38 (4), 442-444. doi:10.1016/j.joen.2011.12.009

Panitvisai, P., Parunnit, P., Sathorn, C., & Messer, H. H. (2010). Impact of a retained instrument on treatment outcome: a systematic review and meta-analysis. *Journal of Endodontics*, 36 (5), 775-780. doi:10.1016/j.joen.2009.12.029

Parashos, P., & Messer, H. H. (2006). Rotary NiTi instrument fracture and its consequences. *Journal of Endodontics*, 32 (11), 1031-1043. doi:10.1016/j.joen.2006.06.008

Reis, S., Cruz, V. M., Hungaro Duarte, M. A., da Silveira Bueno, C. E., Vivan, R. R., Pelegrine, R. A., Bruno, K. F., & Kato, A. S. (2020). Volumetric analysis of irrigant extrusion in immature teeth after different final agitation techniques. *Journal of Endodontics*, 46 (5), 682-687. doi:10.1016/j.joen.2020.01.014

Shahabinejad, H., Ghassemi, A., Pishbin, L., & Shahravan, A. (2013). Success of ultrasonic technique in removing fractured rotary nickel-titanium endodontic instruments from root canals and its effect on the required force for root fracture. *Journal of Endodontics*, 39 (6), 824-828. doi:10.1016/j.joen.2013.02.008

Shen, Y., Peng, B., & Cheung, G. S.-P. (2004). Factors associated with the removal of fractured NiTi instruments from root canal systems. *Oral Surgery, Oral Medicine, Oral Pathology, Oral Radiology, and Endodontics*, 98 (5), 605-610.

doi:10.1016/j.tripleo.2004.04.011

Simon, S., Machtou, P., Tomson, P., Adams, N., & Lumley, P. (2008). Influence of fractured instruments on the success rate of endodontic treatment. *Dental Update*, 35 (3), 172-179. doi:10.12968/denu.2008.35.3.172

Singh, P., Soni, S., Dharmadhikari, S., & Shah, A. (2017). Using cone beam computerized tomography as a guide for the removal of fractured endodontic instrument from the apex of mandibular first molar: a case report. *Journal of Research and Advancement in Dentistry*, 6 (3s), 143-146.

Spili, P., Parashos, P., & Messer, H. H. (2005). The impact of instrument fracture on outcome of endodontic treatment. *Journal of Endodontics*, 31 (12), 845-850. doi:10.1097/01.don.0000164127.62864.7c

Susila, A., & Minu, J. (2019). Activated irrigation vs. conventional non-activated Irrigation in endodontics – a systematic review. *European Endodontic Journal*, 4 (3), 96-110. doi:10.14744/ej.2019.80774

Suter, B., Lussi, A., & Sequeira, P. (2005). Probability of removing fractured instruments from root canals. *International Endodontic Journal*, 38 (2), 112-123. doi:10.1111/j.1365-2591.2004.00916.x

Terauchi, Y., O'Leary, L., Yoshioka, T., & Suda, H. (2013). Comparison of the time required to create secondary fracture of separated file fragments by using ultrasonic vibration under various canal conditions. *Journal of Endodontics*, 39 (10), 1300-1305. doi:10.1016/j.joen.2013.06.021

Vaz-Garcia, E. S., Vieira, V. T. L., Petitet, N. P. da S. F., Moreira, E. J. L., Lopes, H. P., Elias, C. N., Silva, E. J. N. L., & Antunes, H. dos S. (2018). Mechanical properties of anatomic finishing files: XP-Endo Finisher and XP-Clean. *Brazilian Dental Journal*, 29 (2), 208-213. doi:10.1590/0103-6440201801903

Walmsley, A. D., Lumley, P. J., Johnson, W. T., & Walton, R. E. (1996). Breakage of

ultrasonic root-end preparation tips. *Journal of Endodontics*, 22 (6), 287-289.  
doi:10.1016/S0099-2399(96)80260-3

Wan, J., Deutsch, A. S., Musikant, B. L., & Guzman, J. (2014). Evaluation of the breakage of orthograde endodontic ultrasonic tips. *Journal of Endodontics*, 40 (12), 2074-2076.  
doi:10.1016/j.joen.2014.09.007

Wang, D., He, X., Wang, Y., Zhou, G., Sun, C., Yang, L., Bai, J., Gao, J., Wu, Y., & Cheng, J. (2016). Topographic relationship between root apex of mesially and horizontally impacted mandibular third molar and lingual plate: cross-sectional analysis using CBCT. *Scientific Reports*, 6, 39268. doi:10.1038/srep39268

Wang, H., Ni, L., Yu, C., Shi, L., & Qin, R. (2010). Utilizing spiral computerized tomography during the removal of a fractured endodontic instrument lying beyond the apical foramen. *International Endodontic Journal*, 43 (12), 1143-1151. doi:10.1111/j.1365-2591.2010.01780.x

**Percentage of contribution of each author in the manuscript**

Thaís Christina Cunha – 30%

Felipe de Souza Matos – 30%

Luiz Renato Paranhos – 20%

Camilla Christian Gomes Moura – 20%